

CASE REPORT

Superficial Angiomyxoma of the Eyelid. A Case Report and Review of the Literature

Nadzrin Md Yusof^{1,2}, Noraini Mohd Dusa³, Norhafizah Mohtarrudin^{1,2}, Razana Mohd Ali^{1,2}

¹ Histopathology Unit, Pathology Department, Faculty of Medicine and Health Sciences, Universiti Putra Malaysia, 43400 UPM Serdang, Selangor, Malaysia.

² Histopathology Unit, Pathology Department, Serdang Hospital, Jalan Puchong, 43000 Kajang, Selangor, Malaysia.

³ Histopathology Unit, Pathology Department, Kuala Lumpur Hospital, 50586 Jalan Pahang, Wilayah Persekutuan, Kuala Lumpur, Malaysia.

ABSTRACT

Superficial angiomyxoma (SA) is an angiomyxoid cutaneous tumour. It has predilection for the head and neck, torso, limbs and genital tract. Our case is a 27-year-old female, presented with painless right medial canthal mass for two years. It was associated with tearing when the lesion grew larger. We received a nodular brownish tissue measuring 25x20x15mm with homogenous brownish cut surface. Microscopically, the tumour was partially circumscribed, exhibiting bland stellate to spindle cells of moderate cellularity with pale eosinophilic cytoplasm, indistinct border, in a loose collagenous myxoid matrix with numerous blood vessels of different calibre. The lesional cells were present at the resected margin and were nonreactive towards CD34, SMA and S100. SA of the eyelid is sometimes mistaken clinically as dermoid cyst or lipoma. Reports have shown increased risks of local recurrence following incomplete excision. Close association with Carney's complex is an important feature. Careful clinicopathologic correlation and proper investigations are needed for optimal patient care.

Keywords: Eyelid, Mass, Canthal, Superficial, Angiomyxoma

Corresponding Author:

Razana Mohd Ali, MPath

Email: razanamo@upm.edu.my

Tel: +603-97692384

INTRODUCTION

Superficial angiomyxoma is a form of cutaneous angiomyxoid neoplasm (1). It is the abundant and prominent myxoid feature along with proliferating small vascular channels that represent this tumour as well as presence of spindle to stellate cells of sparse to moderate cellularity (1,2). The predilection to certain sites such as the torso, head and neck, trunk, limbs and genital tract characterised this lesion. Eyelid, ear canal and nipple are the reported to be the common site (1). Genital angiomyxoma is a site-specific lesion that is usually discussed separately.

Allen P.W. et al (1998) first described superficial angiomyxoma with and without the presence of epithelial elements (1). Subsequently, Calonje E. et al (1999), reported a series of 39 cases with distinctive histology with tendency for recurrence (2). Risk of local recurrence is higher when it is not completely excised (1-3). In the past, these lesions were considered as

mesenchymal neoplasm that show secondary myxoid change, hence the identification of primary lesion is difficult (2). It is also closely linked to cardiac myxoma, forming part of the Carneys complex, an autosomal dominant condition especially if the external ear is involved as reported in a few literature (2,4). Multiple cutaneous myxomas, cardiac myxoma, mammary myxoma, lentiginos and endocrine overactivity are the entities of Carney's complex.

CASE REPORT

We report a case of 27-year-old female, presented with painless right medial canthal mass for two years. It was associated with tearing when the lesion grew larger otherwise there was no visual disturbances. The patient did not complain of any history of cutaneous lesion elsewhere or history of trauma. On examination, the mass was nodular, soft, non-mobile and non-tender. Ophthalmic examination was unremarkable. Other systemic examination particularly the cardiovascular system did not reveal any significant findings. Excision biopsy via anterior orbitotomy using transconjunctival approach was done. A well encapsulated vascularised lobular soft tissue mass measuring 3cm x 2.5cm was removed. Postoperatively, the patient was well. The last

follow up did not reveal any tumour recurrence.

On macroscopic examination, there was a nodular brownish tissue measuring 25x20x15mm with homogenous brownish cut surface. Representative sections were submitted for histological examination. Microscopically, the tumour showed a partially circumscribed lesion exhibiting bland stellate to spindle cells of moderate cellularity embedded in a loose collagenous myxoid matrix (Fig. 1). These cells show indistinct border with pale eosinophilic cytoplasm. There was no nuclear atypia. There were multiple blood vessels of different calibre, some appear dilated with hyalinised wall as well as scattered lymphocytes, neutrophils and mast cells (Fig. 2). There was no epithelial inclusion or basaloid protrusion into the lesion identified. The lesional cells were seen at the resected margin. Immunohistochemical study showed the lesional cells were nonreactive towards CD34, SMA and S100 (Fig. 3). An interpretation of superficial angiomyxoma, incompletely excised was given. The managing team was alerted for the risk of tumour recurrence.

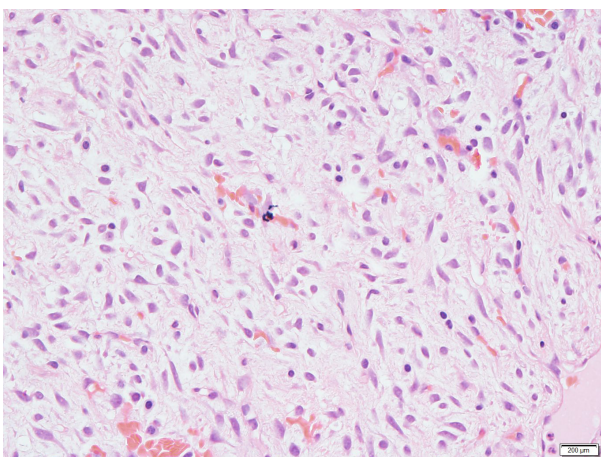


Fig. 1 : Abundant myxoid stroma with scattered spindle and stellate cells with small thin-walled blood vessels. (Hematoxylin & Eosin stain, original x200)

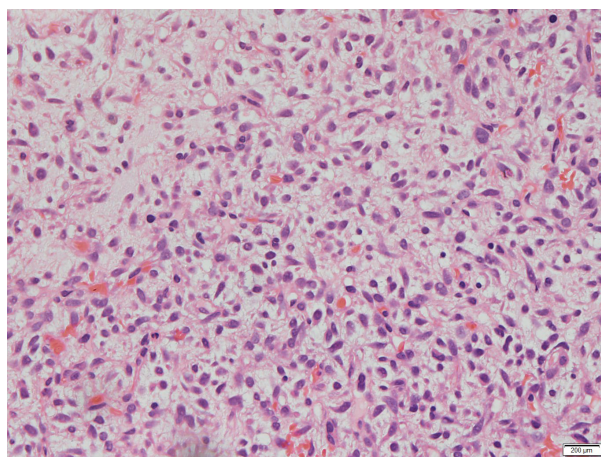


Fig. 2 : Bland spindle and stellate cells with absence of mitoses and scattered intermixed lymphocytes, neutrophils and plasma cells. (Hematoxylin & eosin stain, x200)

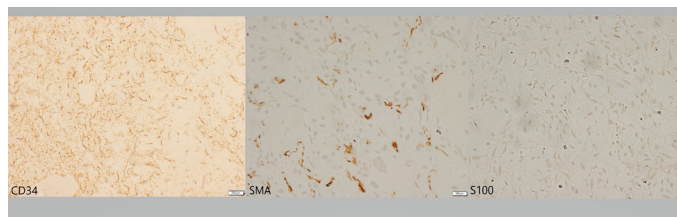


Fig. 3 : The neoplastic cells were nonreactive to CD34, SMA and S100. (x100)

DISCUSSION

Superficial angiomyxoma (SA) is a rare cutaneous angiomyxoid tumour involving the dermis and sometimes subcutis (1). Its prominent myxoid feature is characteristic along with the presence of multiple small vascular channels. It is poorly circumscribed and composed of spindle to stellate cells of sparse to moderate cellularity (1-3). Differentials by histology varies from cutaneous focal mucinosis, dermal nerve sheath myxoma, myxoid perifollicular fibroma, digital mucous cyst and myxoma, dermal nerve sheath myxoma (neurothekeoma), myxoid neurofibroma, aggressive angiomyxoma to low-grade myxofibrosarcoma, low-grade fibromyxoid sarcoma, and myxoid liposarcoma (1,2).

When Allen P.W. et al first described solitary SA, an association of some of their cases of SA with the presence of epithelial components in the form of epithelial cyst, strands of squamous epithelium and basaloid clusters were identified (1). Thus, their differentials include cutaneous lesions such as trichofolliculoma and trichodiscoma. Subsequently, it was suggested by Calonje E. et al (1999) that these structures represent secondary entrapped epithelial structures in the growing tumour and recurring cases (2). This was however not present in our case.

Among the differentials, focal mucinosis shows abundant mucin with relatively few cells and blood vessels compared to SA (2). Lesions such as myxoid perifollicular fibroma are predominantly a fibrous papule, while trichofolliculoma were diagnosed based on the presence of the epithelial components as the main feature, purely dermal and lacking the blood vessels proliferation when compared to SA (1,2). Immunohistochemistry can differentiate dermal nerve sheath myxoma and neurofibroma from SA by S100 reactivity. Neurofibroma also show its characteristic spindle cells with wavy nuclei. Histological features that support SA compared to the low-grade myxofibrosarcoma and low grade fibromyxoid sarcoma will be based on the presence of nuclear atypia, mitoses, more infiltrative border, as well as size and location. Similar criteria for myxoid liposarcoma in addition to the presence of lipoblasts is used to differentiate from SA. Aggressive angiomyxoma usually occurs in the female genital tract. Digital mucous cyst is also site specific.

Another feature that was described by Calonje E. et al was the inflammatory infiltrates in SA, characteristically neutrophils that were not associated with the presence of either ulcer or necrosis (2). They have suggested that it could be a feature that differentiate SA from other myxoid tumours. Other reports have also described this feature as clue to the diagnosis when compared to other myxomas where this feature was not present (5). The underlying mechanism for this feature was not explained. We have also noted some scattered extravascular neutrophils in our case within the tumour.

Calonje E. et al described in his series that the lesions appeared polypoid in some cases as well as cutaneous nodules and papules in others (1-3). These appearances were not specific for the diagnosis of superficial angiomyxoma and consequently, clinical diagnosis usually favoured other common benign lesions such as epidermal cyst and lipoma. Local recurrences were associated with incomplete removal of the lesion. It was reported to be 30 to 40 percent in the literature (1,2,4). There was to date no reports of distant metastases (2,4). In our case, the lesional cells are seen at the resected margin, however, in the 4 years of following up the case, the lesion has not recurred. In the series by Calonje E et al, the duration to recurrence ranges from 2 months to 216 months (18 years) with a median of 12 months (2).

To date, there is only very few reported cases of superficial angiomyxoma involving the eyelid, despite the ear canal, eyelid and nipple were mentioned to be the common sites (2). Allen P.W. et al reported 5 out of his 30 cases were from the head and neck region while Calonje E. et al received more cases (14 out of 39) from the head and neck region likely being a referral centre (1,2). Intraoral cases have also been reported (2). In view of its rarity, if multiple SA were present, an association with Carney's complex, a syndrome of autosomal dominant inheritance should be considered. Carney's complex includes cardiac myxoma in addition to multiple cutaneous myxoma, mammary myxoma, lentiginos (nevi), ephelides and endocrine overactivity (1,2). Involvement of the external ear was more frequently associated with Carney's complex in a few reports (2,4). The patient in our case did not complain of any symptoms, no other cutaneous lesions elsewhere

and physical examination did not reveal any significant findings.

CONCLUSION

In conclusion, superficial angiomyxoma of the eyelid is a rare cutaneous angiomyxoid tumour. There are several differentials with regards to its myxoid nature. However, its histology is quite distinct from other myxoid tumours. The recurrence rate is higher when it is associated with incomplete excision. Awareness of its association with Carney's complex should also allow for thorough examination and instigate proper investigations to exclude cardiac myxoma, when symptoms are present for optimal patient care.

ACKNOWLEDGEMENT

The authors would like to thank the Director of Health Malaysia for permission to publish this paper.

REFERENCES

1. Allen PW, Dymock RB, MacCormac LB. Superficial angiomyxomas with and without epithelial components. Report of 30 tumors in 28 patients. *Am J Surg Pathol.* 1988;12(7):519-530. doi:10.1097/00000478-198807000-00003.
2. Calonje E, Guerin D, McCormick D, Fletcher CD. Superficial angiomyxoma: clinicopathologic analysis of a series of distinctive but poorly recognized cutaneous tumors with tendency for recurrence. *Am J Surg Pathol.* 1999;23(8):910-917. doi:10.1097/00000478-199908000-00008.
3. Yun YI, Lee KS, Khwarg SI, Kim N. Rare Case of Isolated Superficial Angiomyxoma of the Eyelid. *Korean J Ophthalmol.* 2020;34(3):262-264. doi:10.3341/kjo.2020.0010.
4. Ali N, Child CS, Michaelides M, Olver JM. Recurrence of a rare skin tumour: superficial angiomyxoma in the eyelid. *Can J Ophthalmol.* 2011;46(2):205-206. doi:10.3129/i11-005.
5. Schmitzer S, Potop V, Levy MY, Popteanu IC. Atypical Presentation of a Rare Eyelid Tumor: A Case Report. *J Ophthalmic Stud.* 2018; 1(1): 1-3. dx.doi.org/10.16966/2639-152X.112.