

## CASE REPORT

# A Deadly Hole: Postmortem Multislice Computed Tomography of Gunshot Injury

Suzana Ab Hamid<sup>1</sup>, Muhammad Helmi Muhammad Noor<sup>2</sup>, Khairul Anuar Zainun<sup>3</sup>

<sup>1</sup> Department of Imaging, Faculty of Medicine and Health Sciences, Universiti Putra Malaysia, 43100 Serdang, Selangor, Malaysia

<sup>2</sup> Department of Radiology, Hospital Kuala Lumpur, 26100 Kuala Lumpur, Malaysia

<sup>3</sup> Department of Forensic Medicine, Hospital Kuala Lumpur, 26100 Kuala Lumpur, Malaysia

### ABSTRACT

We report a case of a fatal gunshot injury to the chest which illustrates the compatibility of the Postmortem Multislice Computed Tomography (PMCT) features with that of conventional forensic autopsy findings. This case demonstrates that the PMCT has high potential to enhance the investigation and performance of conventional forensic autopsy.

**Keywords:** Gunshot, Postmortem Multislice Computed Tomography (PMCT), Virtual autopsy

### Corresponding Author:

Suzana Ab Hamid, MD, MRad

Email: sznah@yahoo.com; suzana@upm.edu.my

Tel: +603-97692511

### INTRODUCTION

Gunshot injury is a serious ballistic trauma associated with high morbidity and mortality rate. Its incidence across the globe is in rising trend in this era of millennium, most often due to both homicide and suicide cases.

Forensic investigation of a gunshot related death can be a challenging process. Besides scene information, a detailed autopsy performance becomes a necessity in order to understand and reconstruct the shooting event. Multislice Computed Tomography has become and continues to be a useful modality in the forensic investigations of lethal gunshot wounds. It is a non-invasive imaging investigation which able to guide and direct forensic autopsy. In the forensic field, it is well established with the term Postmortem Multislice Computed Tomography (PMCT) or virtual autopsy.

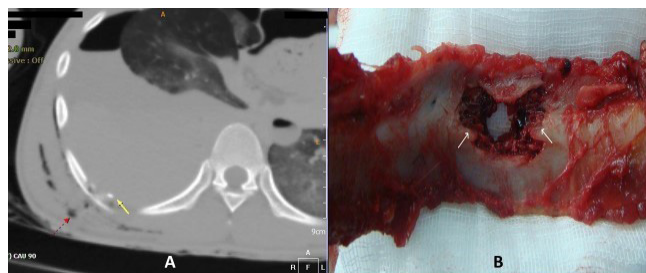We report a case of a fatal gunshot injury to the chest which illustrates the compatibility of the PMCT features with that of conventional forensic autopsy findings. This case demonstrates that the PMCT has high potential to enhance the investigation and performance of conventional forensic autopsy.

### CASE REPORT

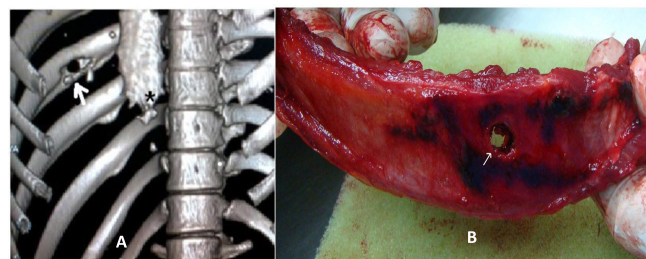
A 19-year-old male teenager was found dead at the road-side by the passers-by. Forensic investigation

was launched by the police upon receiving the body discovery report. On examination of the dead body by the police officer at the scene, a gunshot wound was found on the right side of the posterior chest wall. Retrospective history revealed he was shot while attempting gang-robbery in the nearby residential area. The body was later brought to the tertiary medical center for a detailed post-mortem. A non-contrasted PMCT for the whole body was conducted using Toshiba Aquillon 64 multislices scanner prior to conventional autopsy. The head was scanned using conventional scan mode with 120 kV, 250 mA, 1 sec/rotation, and 8 mm collimation. Helical scan mode was performed for the neck region using 120 kV, 200 mA, 0.75 sec/rotation, and 5 mm collimation. For the body block (thorax, abdomen, pelvis, and lower limbs); helical scan mode was used using 120 kV, 200–400 mA, 0.5 sec/rotation, and 5 mm collimation (cardiac: 2 mm collimation). A bone (B70f) and a soft tissue (B35f) convolution kernel were utilized. Images were documented in a brain window (50/80 HU), bone window (500/1500 HU) and a soft tissue window (50/350 HU). Additionally, coronal and sagittal multiplanar reformations (MPR) with a 4-mm slice thickness were reconstructed directly from the raw data using an overlapping technique. The digital images were stored into Infiniti PAC system.

The PMCT revealed soft tissue injury with subcutaneous emphysema and a linear track of air at the lower right chest wall posteriorly (Fig.1). There was a well defined round hole at the right 8th posterior rib with adjacent internal beveling which represented an entry wound (Fig.2). A jagged fracture was seen on the right side of the xiphisternum at the level of 9th lumbar vertebra in keeping with exit wound (Fig.2). Another relatively larger

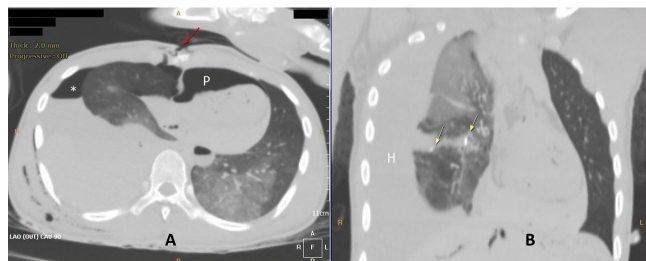


**Figure 1:** **A** - Lung window of axial PMCT showing soft tissue injury with air pockets in the posterior right chest wall and a linear track of gas (dotted arrow) associated with internal beveling at the fractured rib (solid arrow) represent the direction of gunshot entrance. **B** - Autopsy specimen viewed from internal aspect of the rib demonstrating internal beveling (arrows) compatible with the one on PMCT.

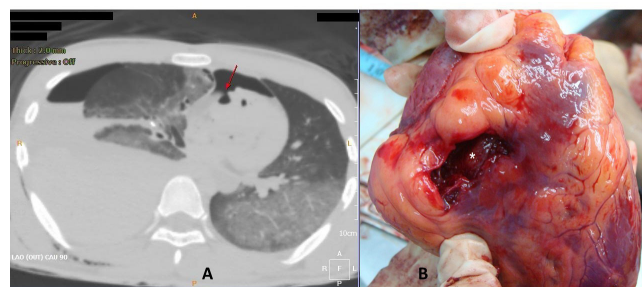


**Figure 2:** **A** - Volume rendering image of the thoracic cage demonstrating an entrance hole with characteristic internal beveling at the right 8th posterior rib (arrow) and a jagged fracture of exit wound at the right side of the xiphisternum (asterisk). **B** - The deadly hole of entrance wound in the right 8th posterior rib (arrow) on autopsy specimen.

irregular open wound with multiple small air pockets was observed at the subcutaneous tissue of the anterior chest wall in the midline (Fig.3A). Lung window of the same PMCT demonstrated right haemopneumothorax with adjacent lung atelectasis. The pneumothorax appeared to be in continuity with the pneumopericardium (Fig.3A). There were evidence of bony fragments with CT density of 200-315 HU scattered at the collapsed superior segment of the right lower lobe which followed the direction of the projectile (Fig.3B). There was also discontinuity of the right ventricular muscle suggesting right ventricular laceration (Fig.4B). The PMCT findings (Fig.4A) were compared with those of conventional autopsy and found to be compatible. No abnormality



**Figure 3:** **A** - Axial PMCT image showing jagged exit wound at the anterior chest wall adjacent to the right side of xiphisternum (arrow), associated with pneumothorax (asterisk) and pneumopericardium (P). **B** - Coronal reformat image showing multiple tiny bony fragments at the atelectatic superior segment of the right lower lobe follows the direction of the projectile.



**Figure 4:** **A** - Laceration wound of the right ventricle is demonstrated by this axial PMCT as discontinuity of the right ventricular muscle with adjacent air pocket (arrow). **B** - Autopsy specimen of the heart confirmed right ventricular laceration wound (asterisk)

was seen in the other parts of the body.

## DISCUSSIONS

Gunshot may either cause penetrating or perforating wounds. Penetrating wound occurs when the projectile enters the body and does not exit. On the other hand, the projectile enters and exits the body in perforating wound. The degree of tissue injury caused by the projectile depends on the types of tissues. The most friable organs such as liver and brain will results in the most severe injury. Contrary, the bones and subcutaneous tissues are more resistant to injury (1).

Forensic autopsy of any fatal gunshot injury need to be done thoroughly. It usually involves detailed documentation and critical analysis and interpretation of injuries in order to finally reconstruct the actual shooting incident. Entrance and exit wounds, bullet projectile pathway, range of gunshot and manner of inflictions are some of important information usually gathered from the autopsy (2). In the end, the cause of death and which one is the fatal shot need to be highlighted to the investigative authority.

PMCT has become and will continue to be an effective investigation tool for autopsy performance of fatal gunshot injuries. It is able to guide and direct the actual autopsy. It can reliably identify the location of the entrance and exit wounds, the course of projectile pathway and the associated tissue or organ injury in determining the cause and manner of death.

Entrance wounds are commonly smaller than the exit wounds due to elastic property of the skin, as demonstrated in our case. The path of bullet through a bone causes internal beveling at the bone margin at the entrance and external beveling at the exit wound as shown in Fig.2 of our case (1).

The identification of metallic or bone fragments is another indicator of the direction of the projectile. PMCT also precisely demonstrates and characterizes the foreign materials present in the body (3). The course of projectile within the soft tissues is demonstrated by

tissue/organ damage and presence of air pockets (4). However, it is worth noted that if the projectile passes the gas-containing structures eg. the lungs or bowels, air may also be introduced into the path. Blood or other body fluids may be collected in the injured structures, in our case, right hemothorax was noted.

Comparing the PMCT and conventional autopsy, a previous research found that PMCT is superior in detecting abnormal air accumulations (pneumothorax, surgical emphysema and pneumocephalus) as well as comminuted fractures in the skull vault, facial bone, ribs and vertebral body (5). In addition, PMCT revealed a significantly higher number of injuries detected per region than those of conventional autopsy. However conventional autopsy is better in detection of organ injuries and aortic ruptures (5).

### CONCLUSION

PMCT is an effective non-invasive technique that has high potential to enhance investigation and performance of conventional forensic autopsy in gunshot injuries.

### ACKNOWLEDGEMENT

The authors would like to thank the staffs of National

Institute of Forensic, Hospital Kuala Lumpur, Malaysia who have been involved in the management of the patient.

### REFERENCES

1. Di Maio VJM. Gunshot wounds: practical aspects of firearms, ballistics, and forensic techniques. 2nd edn. CRC press; Boca Raton, New York, 2002
2. Beasant Matthews PE. 2000. Examination and interpretation of rifled firearm injuries. In: The Pathology of Trauma. Mason JK, Purdue BN. 3rd ed. London: Edward Arnold. Pp 47-60.
3. Harcke HT, Levy AD, Getz JM, Robinson SR. MDCT Analysis of projectile injury in forensic investigation. AJR 2008; 190:106-110.
4. Makhlof F, Scolan V, Ferretti G, Stahl C, Paysant F. Gunshot fatalities: correlation between post-mortem multi-slice computed tomography and autopsy findings: a 30-months retrospective study. Legal Med (Tokyo, Japan), 2013 15(3):145–148. doi: 10.1016/j.legalmed.2012.11.002
5. Elkhateeb S.A., Mohammed E.B, Meleka H.A, Ismail A.A.E. Postmortem computed tomography and autopsy for detection of lesions and causes of death in gunshot injury cases: a comparative study. Egyptian Journal of Forensic Sciences, 2018; 8:50.