

## DYNAMIC CERVICAL LUNG LOBE HERNIATION IN A SHIH TZU DOG

T.S.Y. Joanne<sup>1</sup>, M.L. Lim<sup>2</sup>, O. Asnawi<sup>3</sup>, M.A.H. Shamsul<sup>3</sup> and K.H. Khor<sup>1,\*</sup>

<sup>1</sup>Faculty of Veterinary Medicine, University Putra Malaysia, UPM Serdang, Selangor Darul Ehsan, Malaysia

<sup>2</sup>Pet Wellness Veterinary Clinic, 7463 Jalan Bagan Lalang, Butterworth, Pulau Pinang, Malaysia

<sup>3</sup>University Veterinary Hospital, Faculty of Veterinary Medicine, University Putra Malaysia, UPM Serdang, Selangor Darul Ehsan, Malaysia

### SUMMARY

An 8-year-old spayed female Shih Tzu was referred to University Veterinary Hospital (UVH) with history of chronic coughing for more than a year duration. Dry, hacking cough was heard and bilateral wheezing lung sound was noted upon physical examination. Auscultation of heart revealed left apical systolic heart murmur Grade III/VI. A soft, intermittent swelling was observed at ventral neck, cranial to thoracic inlet (protruded upon expiration and collapsed upon inspiration). Thoracic radiography taken showed presence of apical radiolucency at cervical region and bronchial pattern at caudodorsal lungs with left atrium enlargement and right-sided heart enlargement. Echocardiographic examination revealed myxomatous mitral valve disease (MMVD) with mild regurgitation. Based on diagnostic imaging, this case was diagnosed as dynamic lung lobe herniation secondary to chronic coughing concurrent with myxomatous mitral valve disease. Other differential diagnosis that may lead to chronic cough such as of tracheal collapsed and bronchiectasis was not rule out.

Keywords: coughing, dog, lung lobe herniation, thoracic radiography

### INTRODUCTION

Lung lobe herniation defines as the protrusion of the pulmonary tissue beyond the normal confines of the thoracic cavity. It may be a common phenomenon in dogs, however, was claimed rarely reported (Lee, 2017). Lung lobe herniation is an uncommon condition in humans (Weissberg and Refaely, 2002).

Morel-Lavallée (1845) classified lung lobe herniation based on anatomical location such as cervical, thoracic and diaphragmatic. Classification by aetiology are grouped into congenital or acquired, and is further sub-divided into traumatic, spontaneous, and pathological causes. In humans, one-third of lung lobe herniation is cervical associated to congenital, due to a defect in Sibson's fascia that extends from the first rib to the last cervical vertebra, resulting in an area of weakness between the sternocleidomastoid and anterior scalene muscles (Minai *et al.*, 1997). Acquired cervical lung lobe herniation (CLLH) occurs a result from increased intra-thoracic pressure from coughing due to chronic obstructive pulmonary disease (COPD) causing weakening and stretching of cervical muscles (Bhalla *et al.*, 1990). Overall, 85% of lung herniation in humans was caused by trauma (Moncada *et al.*, 1996). The condition may be differed for the dog as spontaneous lung hernias were the most common reported as a sequelae of chronic respiratory diseases (Choi *et al.*, 2015). In dogs, only cervical lung lobe herniation has been noticed (Guglielmini *et al.*, 2007). This case report described a dynamic cervical lung lobe lobe herniation as a sequelae of progressive chronic cough.

### CASE PRESENTATION

A 8-year-old spayed female Shih Tzu was referred to University Veterinary Hospital, Universiti Putra Malaysia (UVH-UPM) for evaluation of chronic cough that had occurred for more than a year. Dog was abandoned at a local shelter and was found to have a bad cough. Dog was then fostered, cough treated and nursed back to health. A new owner adopted the dog for three months and dog was then returned to the shelter for recurrent cough. The previous foster caretaker adopted the dog and presented to a veterinarian for the investigation of the cause of cough. Dog was diagnosed with myxomatous mitral valve disease (MMVD) at that time point of time and was maintained with imidapril (0.25 mg/kg PO q24h) for a year (at the time when dog was presented to UVH). During the period of one year, intermittent episodes of cough was treated with furosemide (as a diuretic at 4 mg/kg PO q24h), theophylline (a mucolytic drug dosed at 10mg/kg PO q12h) and prednisolone (1 mg/kg PO q12h). The combination of drugs were used based on the clinical sign with the aim to suppress the episodes of cough. According to the referring veterinarian, the dog's cough had worsened recently and did not respond to the combination of medications given namely; azithromycin (5 mg/kg PO q12h for 5 days), furosemide (4 mg/kg PO q24h), serratiopeptidase (1 tab PO q12h) and theophylline (10 mg/kg PO q12h). The dog owner also reported that the dog would cough spontaneously upon excitement, while eating and even at rest. The reason for referral at UVH was for investigation of chronic cough, to evaluate the progression of the heart disease and to determine if the heart condition was the cause of coughing in this dog.

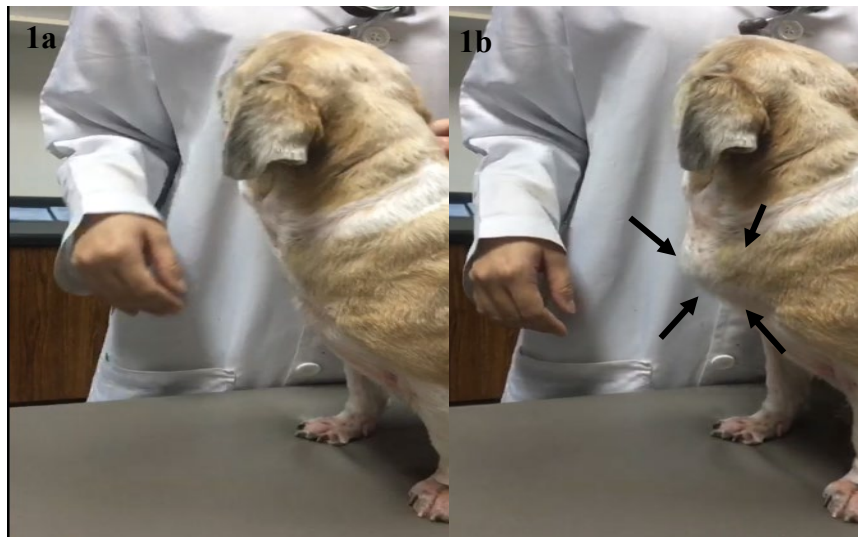
At presentation, the dog weighed 6.6 kg, was bright, alert and responsive. The temperature was 38.5°C with a pulse rate of 128 beats/min and respiratory rate of 28 breaths/min. An increased respiratory effort was noticed

\*Corresponding author: Dr Khor Kuan Hua (K.H. Khor);  
Phone No: 03-86093926; Email: [khkhor@upm.edu.my](mailto:khkhor@upm.edu.my)

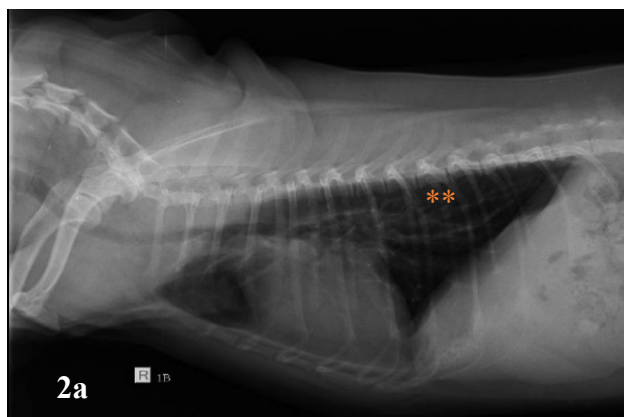
during expiration and the dog had demonstrated dry hacking cough of upper respiratory tract. Auscultation of the lungs cranial caudally on both sides of thoracic cavity revealed bilateral wheezing noises that appeared not originated from the thoracic region. A left systolic apical heart murmur grade III/VI was heard upon cardiac auscultation. Cough test was positive and each cough was accompanied by a dynamic intermittent soft swelling that protruded upon expiration and collapsed on inspiration observed at the ventral neck, just cranial to the thoracic inlet (Figure 1a and 1b). Palpation of the dynamic swelling area revealed that it was non painful and soft; and the dog was noticed to cough less and was more relaxed when gentle pressure was applied on ventral cranial thoracic inlet. The differential diagnosis for the chronic cough at that point of time was pulmonary oedema, bronchitis, tracheal collapsed, and bronchiectasis. The lump palpated was suspected due to lung lobe hernia, mass (neoplasia) or an abscess/granuloma. However, granuloma and abscess were not likely as the patient was not feverish, demeanour and appetite was all very good.

A routine thoracic radiograph of right lateral and

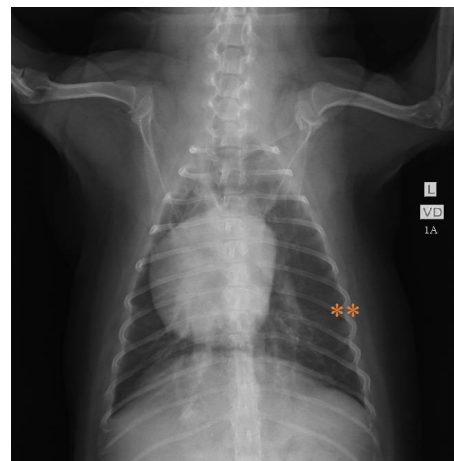ventral-dorsal view were obtained (Figure 2a & 2b). Radiographic findings revealed an enlarged cardiac silhouette from the lateral view as both, the intercostal space and sternal contact increased with trachea elevated dorsally. However, the heart size were normal with a Vertebral Heart Score (VHS) of 10.0 (Figure 2a), inverted 'D' heart shape suggestive of right sided heart enlargement (Figure 2b) and presence of bronchial pattern at the caudodorsal lung suggestive of bronchitis (Figure 2a and 2b, refer to \*\*). The presence of 'cowboy stance' appearance of the dilated pulmonary were suggestive of left atrium enlargement with pulmonary vessels congestion (Figure 2b). Echocardiography examination of the two-dimensional (2D) of the right parasternal long axis view revealed thickening of both anterior and posterior leaflets of mitral valves (Figure 3) with presence of mild mitral regurgitation seen in both the left atrium and ventricle (using a color flow Doppler mode). M-mode of right parasternal short axis view at the level of anterior of the papillary muscle was used to measure left ventricular dimension and the averaged measurements were as tabulated in Table 1. Overall, the only abnormal finding was increased in left atrium



**Figure 1a.** Normal appearance of cervical region upon inspiration, and **Figure 1b.** Intermittent swelling protruded cranially upon expiration (outlined with filled arrows)



**Figure 2a (left).** Thoracic radiographs – On the right lateral view, presence of bronchial pattern at caudodorsal lung (\*\* in orange) with vertebral heart score (VHS) of 10.0



**Figure 2b (right).** On ventro-dorsal view, revealed right-sided heart enlargement and left atrium enlargement, with presence of bronchial pattern (\*\* in orange) of the lung

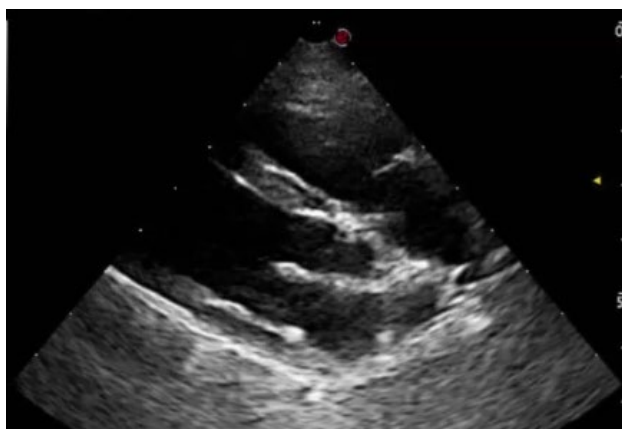dimension while the rest of left ventricular dimensions were within the normal range. Left atrium to aorta ratio (La:Ao) was 1.28, within the normal range. Therefore, the chronic coughing at that point of presentation was unlikely direct contributed by pulmonary edema as a sequelae of MMVD and the heart condition was controlled well with medication based on the echocardiography observations.

Another thoracic radiograph at right lateral view was taken immediate after inducing the dog to cough by tracheal palpation (Figure 4). Radiograph showed presence of apical radiolucency at ventral cervical region. Thus, lung lobe herniation was confirmed in this case based on the thoracic radiograph taken.

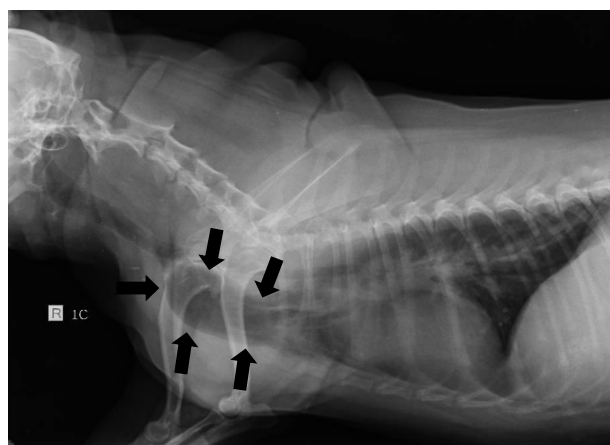
**Table 1. Echocardiographic measurements\* (mean) obtained and compared with reference to M-mode image of right parasternal short axis view**

Dimension	Mean (cm)	Reference range* (6 kg)		
		Mean (cm)	Min (cm)	Max (cm)
IVSd	0.64	0.6	0.4	0.9
LVIDd	2.18	2.6	2.2	3.1
LVPWd	0.62	0.6	0.4	0.9
IVSs	0.8	0.9	0.7	1.2
LVIDs	1.43	1.7	1.2	2.2
LVPWs	0.81	1.0	0.7	1.3
La	2.28	1.4	1.1	1.8
Ao	1.77	1.4	1.2	1.8
La:Ao ratio	1.28			
%EF	65%			
%FS	34	Range = 28% – 40%		

kg = kilogram; cm = centimetre; Min = minimum; Max = maximum, IVSd, IVSs = interventricular septal wall thickness at end-diastole and end-systole; LVIDd, LVIDs = left ventricular internal dimension at end-diastole and end-systole; LVPWd, LVPWs = left ventricular posterior wall thickness at end-diastole and end-systole; La = left atrial dimension; Ao = aortic root dimension; % EF = percentage ejection fraction; %FS = percentage fractional shortening  
\*References adapted from Cornell *et al.*, (2008).



**Figure 3. Echocardiography – Right parasternal long axis view. Both anterior and posterior leaflets of mitral valves were thickened**



**Figure 4. Right lateral thoracic radiograph - At expiration, presence of apical radiolucency at ventral cervical region (black arrows) due to lung lobe herniation**

Final diagnosis for this case would be dynamic lung lobe herniation secondary to chronic coughing concurrent with MMVD. The other differential diagnoses that might triggered chronic cough in this dog was suspected tracheal collapse and bronchiectasis. A fluoroscopy was indicated to observe the dynamic herniation of the lungs and to rule out tracheal collapse that could be a cause of chronic cough. However, further diagnostic investigation and treatment options were declined. Owner opted for medical therapy and conservative management for the dog, as dog owner could not take the risk of anaesthesia if surgery was indicated for the case.

**DISCUSSION**

Cervical herniation of lung can be unilateral or bilateral (McAdams *et al.*, 1996). However, studies shown that a unilateral protrusion of the left cranial lung lobe was reportedly more common in dogs. This is because the pointed apex of left cranial lung extended more cranially than the apex of the right cranial lung. Hence, left cranial lung lobe was more prone to cervical herniation in dogs (Guglielmini *et al.*, 2007). In contrast to dog, cervical herniation of lung in human was reported to be more common on the right lung (Bhalla *et al.*, 1990).

Predisposing factors of dogs with lung herniation reported were due to pulmonary hyperinflation and chronic coughing secondary to chronic obstructive airway disease (Guglielmini *et al.*, 2007). A retrospective study in dogs with cervical lung lobe herniation (CLLH) revealed that all affected dogs had a history of cough (Nafe, 2013). Similarly in this case, the dog had unresolved chronic cough for more than a year. Besides that, long term administration of corticosteroid have been speculated to play a role in CLLH, where by it may weaken and stretch the muscles of thoracic inlet and parietal pleura that normally restrain the apex of the lung (Sonett *et al.*, 1994). Furthermore, advanced age (>7 years old) can be one of the predisposing factors, as reported in most case reports of CLLH, the dogs were at least 8 years old and above. Several of the case reports also share similarity where brachycephalic breeds (such

as Pekingese and pug) were more commonly reported (Guglielmini *et al.*, 2007; Nafe, 2013). In this case, the affected dog was also an old brachycephalic breed (Shih Tzu) dog.

Clear pathomechanism of CLLH has yet to be investigated. However, study had shown that lung lobe herniations in dogs was strongly associated with collapsed intra-thoracic large airway and obstructive airway disease which resulted in increased resistance air flow that was more pronounced during expiration, therefore simultaneously increased its expiratory effort. It was hypothesized that obstructed airway prevents relief of pressure from cough, hence, increased in the intra-thoracic pressure would occurred (Nafe, 2013). With a chronic and continuously increased in the intra-thoracic pressure from chronic coughing may contribute to partial weakness of the thoracic wall which was speculated to play a key role in the pathomechanism of CCLH (Choi *et al.*, 2015).

In dogs with lung herniation, typical clinical finding would be an intermittent soft crepitated bulge of ventral neck, cranial to thoracic inlet, during expiration (Guglielmini *et al.*, 2007). Therefore, a routine physical examination where observation or palpation of neck during a cough would be required to identify CLLH in dogs. Besides that, tracheal manipulation in dogs with airway disease to induce cough could also be done to check for CLLH (Nafe, 2013).

Diagnosis of CLLH can be conducted using thoracic radiography, dynamic fluoroscopy, computed tomography (CT) or some combination of these procedures, besides, physical examination. Expected radiological findings of CLLH in dogs would be apical radiolucencies in the cervical region on expiration from cervical herniation of cranial lung and generalized hyperlucency with flattening of diaphragmatic cupola on inspiration (Guglielmini *et al.*, 2007). It is advised that radiographs were required during maximal expiration with forelimbs pulled caudally in order to evaluate CLLH (Nafe, 2013). However, to visualize herniation in plain thoracic radiography may be difficult as swelling depends on respiratory cycle as routine inspiratory view will not show any defect. Hence, a dynamic fluoroscopy would be the best diagnostic technique to diagnose CLLH as the to-and-fro movement of herniated lung lobes can be evaluated during respiratory cycle. The use of CT to detect CLLH is considered less accurate as lung lobe apex may remain in a normal position during anaesthesia (Guglielmini *et al.*, 2007). However, CT can help to define the location and extent of thoracic wall defect, besides, allow the quantification of lung lobe hyperinflation and evaluation of small airways (Choi *et al.*, 2015; Coutu, 2015).

Treatment for CLLH is aimed at to reduce intra-thoracic pressure by conservative management through aggressive control of the episodes of cough (Choi *et al.*, 2015). Medical management would include a combination used of antitussive, bronchodilators and steroid therapy (Coleman *et al.*, 2005). Usage of steroid such as prednisolone can help to reduce airway inflammation response as well as the use of tramadol to control cough. Bronchodilator such as theophylline and anti-tussive such as butorphanol may help to ameliorate respiratory signs in dogs with CLLH. Curative surgical

repair is resorted in cases of complicated hernia where incarceration or strangulation of hernia occurs. Other possible complications of hernia such as thoracic pain, hemoptysis, recurrent infection and nerve compression, however, these are rarely reported and have yet to be reported in dogs. Surgical technique is recommended in order to repair lung hernia in these affected dogs with CLLH. Surgically correction by transposition of sternocephalicus muscle over the defect has been reported (Okubo *et al.*, 2011). In the same dog, usage of polypropylene mesh to close the hernia along with complementary use of a cervical corset was done in the same case report after recurrence of hernia from previous surgery and favourable postoperative outcome was reported (Okubo *et al.*, 2011).

## CONCLUSION

CCLH usually occurs secondary to chronic cough or chronic obstructive airway disease. Hence, conservative therapy of primary respiratory disorder is recommended. It is important for owners to be aware that appropriate regimen therapy is required to reduce respiratory signs i.e. coughing, to prevent CLLH in dogs and complete abolition of all coughing due to chronic bronchitis or airway collapse can be hard to achieve.

## ACKNOWLEDGEMENT

The authors would like to thank the staff of UVH for their assistance in this case.

## CONFLICT OF INTEREST

None of the authors has any potential conflicts of interest to declare.

## REFERENCES

- Bhalla, M., Leitman, B.S., Forcade, C., Stern, E., Naidich, D.P., and McCauley, D.I. (1990). Lung hernia: Radiographic features. *American Journal of Roentgenology*. 154(1): 51-53.
- Choi, R., Suh, S.I., and Hyun, C. (2015). Cervical lung lobe herniation in a Pekingese dog. *Korean Journal of Veterinary Research*. 55(2): 153-154.
- Coleman, M.G., Warman, C.G., and Robson, M.C. (2005). Dynamic cervical lung hernia in a dog with chronic airway disease. *Journal of Veterinary Internal Medicine*. 19(1): 103-105.
- Cornell, C.C., Kittleson M.D., Torre, P.D., Häggström, J., Lombard, C.W., Pedersen, H.D., Vollmar, A., and Wey A. (2008). Allometric scaling of M-mode cardiac measurements in normal adult dogs. *Journal of Veterinary Internal Medicine*. 18: 311-321.
- Coutu, M.P. (2015). Dynamic cervical lung herniation causing dysphagia in a puppy. *Veterinary Record Case Reports*. 3(1): e000193.
- Guglielmini, C., De Simone, A., Valbonetti, L., and Diana, A. (2007). Intermittent cranial lung herniation in two dogs. *Veterinary Radiology and Ultrasound*. 48(3): 227-229.
- Lee, J.Y. (2017). Fluoroscopic characteristics of tracheal collapse and cervical lung herniation in dogs: 222 cases (2012–2015). *Journal of Veterinary Science*. 18(4): 499-505.
- McAdams, H.P., Gordon, D.S., and White, C.S. (1996). Apical lung hernia: Radiologic findings in six cases. *American Journal of Roentgenology*. 167(4): 927-930.
- Minai, O.A., Hammond, G., and Curtis, A. (1997). Hernia of the lung: A case report and review of literature. *Connecticut Medicine*, 61(2): 77-81.

- Moncada, R., Vade, A., Gimenez, C., Rosado, W., Demos, T.C., Turbin, R., and Venta, L. (1996). Congenital and acquired lung hernias. *Journal of Thoracic Imaging*. 11(1); 75-82.
- Nafe, L.A. (2013). Cervical lung lobe herniation in dogs identified by fluoroscopy. *The Canadian Veterinary Journal*. 53(10): 955.
- Okubo, Y., Mishina, M., and Watanabe, T. (2011). Cervical lung herniation in a dog surgically treated with a cervical corset. *Japanese Journal of Veterinary Anesthesia and Surgery*. 42(3/4): 45-49.
- Sonett, J.R., O'shea, M.A., Caushaj, P.F., Kulkarni, M.G., and Sandstrom, S.H. (1994). Hernia of the lung: Case report and literature review. *Irish Journal of Medical Science*. 163(9): 410-412.
- Weissberg, D., and Refaely, Y. (2002). Hernia of the lung. *The Annals of Thoracic Surgery*. 74(6): 1963-1966.