UNIVERSITI PUTRA MALAYSIA

3D MULTIMODAL CARDIAC DATA RECONSTRUCTION USING COMPUTERIZED TOMOGRAPHIC ANGIOGRAPHY AND X-RAY ANGIOGRAPHY REGISTRATION

SEYED ROHOLLAH MOOSAVITAYEBI

FSKTM 2016 1

3D MULTIMODAL CARDIAC DATA RECONSTRUCTION USING COMPUTERIZED TOMOGRAPHIC ANGIOGRAPHY AND X-RAY ANGIOGRAPHY REGISTRATION

By

SEYED ROHOLLAH MOOSAVITAYEBI

Thesis Submitted to the School of Graduate Studies, Universiti Putra Malaysia, in Fulfilment of the Requirements for the Degree of Doctor of Philosophy

June 2016

DEDICATIONS

My respectable parents who share their lives with me

My dear wife, Mahta, whose infinite support, incredible understanding and ultimate kindness are immeasurable

To my supervisor and entire committee.

And, to all whom I love.

Abstract of thesis presented to the Senate of Universiti Putra Malaysia in fulfilment of the requirement for the degree of Doctor of Philosophy

3D MULTIMODAL CARDIAC DATA RECONSTRUCTION USING COMPUTERIZED TOMOGRAPHIC ANGIOGRAPHY AND X-RAY ANGIOGRAPHY REGISTRATION

By

SEYEDROHOLLAH MOOSAVITAYEBI

June 2016

Chairperson : Associate Prof. Rahmita Wirza O.K. Rahmat, PhD
Faculty : Computer Science and Information Technology

Computerized tomographic angiography (3D data representing coronary arteries) and X-ray angiography (2D X-ray image sequences providing information about coronary arteries and their stenosis) are standard and popular assessment tools utilized for medical diagnosis of coronary artery diseases. At present, the results of both modalities are analyzed individually by medical specialists, and it is difficult for them to mentally connect the details of these two techniques. This research aims to propose a new framework for coronary artery registration in both modalities to provide the 3D position of the stenosis diagnosed in X-ray angiography images.

In this study, coronary arteries from two modalities are registered in order to create a 3D reconstruction and visualization of stenosis position. Over the last decade, some algorithms have been developed to register coronary arteries from the above modalities. However, most of them failed to register coronary arteries in order to estimate stenosis points from X-ray angiography on computerized tomographic angiography modalities. In this research work, we report on new contributions to the major parts of a 3D multimodal cardiac data reconstruction system.

The first contribution is to propose a fast, accurate and fully automatic method for coronary artery segmentation and labeling from X-ray angiography, based on the proposed modified Starlet Wavelet Transform for segmentation, so that the method can be utilized for registering with other modalities. The average accuracy, sensitivity, specificity, and precision values of the proposed method in LCA angiograms from the data sets are 0.96934, 0.86014, 0.98439, and 0.87797, respectively, and in RCA angiograms, the values are 0.97425, 0.89962, 0.99587, and 0.93021, respectively. Obviously, the proposed method is robust in all performance metrics. Also, by comparing the results, it shows that the proposed method has minimum artifacts and it also segmented the whole parts of the coronary arteries. Furthermore, the running time for the

proposed method is much better than other methods, as the whole process is done in less than 1 s.

The second contribution is related to propose a fast and accurate method for 3D main coronary artery segmentation and labeling from CT Angiography based on the proposed Intersection Tracking method and Improved vesselness filter. By conducting experiments on the clinical data sets, it is proven that the proposed method improved the ability of 3D coronary artery segmentation and labeling from computerized tomographic angiography by increasing the overall overlap evaluation to 95.76%. In addition, since no registration is needed prior to applying the proposed intersection tracking method, and also segmentation and labeling are applied at the same time in this work, hence, it is faster compared to previous methods.

The feature-based coronary artery registration in computerized tomographic angiography and X-ray angiography by using the provided features in both modalities is the topic of the third contribution in this work. Tests using the clinical data sets demonstrated that the proposed method aided the specialists to find the location of stenosis lesion and also to determine the visual relationship between the corresponding coronary arteries with the mean value 3D distance of $3.375\ mm$ and standard deviation of $\pm 1.4137\ mm$ in a maximum processing time of 0.2 s for each coronary artery registration.

The proposed research work is applicable and portable for common personal computers, as well as with respect to the standard medical acquisition methods. Moreover, the medical acquisition standards remain unchanged in this work, which means that no calibration in the acquisition devices is required, and it can be applied to most computerized tomographic angiography and X-ray angiography devices. Another benefit of this work would be each corresponding coronary arteries from these two modalities can be registered individually and finally, the results can be combined and displayed as a whole coronary arterial tree including stenosis.

Abstrak tesis yang dikemukakan oleh Senat Universiti Putra Malaysia sebagai memenuhi keperluan untuk ijazah Doktor Falsafah

PEMBINAAN SEMULA DATA JANTUNG 3D MULTIMODAL MELALUI ANGIOGRAFI CT DAN PENDAFTARAN ANGIOGRAFI SINAR-X

Oleh

SEYEDROHOLLAH MOOSAVITAYEBI

Jun 2016

Pengerusi : Profesor Madya Rahmita Wirza O.K. Rahmat, PhD
Fakulti : Sains Komputer dan Teknologi Maklumat

Tomografi berkomputer angiografi (data 3D mewakili arteri koronari) dan angiografi sinar-X (jujukan imej sinar-X 2D menyediakan maklumat mengenai arteri koronari dan stenosis) adalah alat penilaian standard dan popular digunakan untuk diagnosis perubatan penyakit arteri koronari. Pada masa ini, keputusan dari kedua-dua modaliti dianalisis secara individu oleh pakar perubatan, dan sukar bagi pakar untuk menghubungkan butiran kedua-dua teknik tersebut menggunakan minda. Kajian ini mencadangkan satu rangka kerja yang baharu untuk pendaftaran arteri koronori di dalam kedua-dua modaliti untuk menyediakan lokasi 3D stenosis yang telah didiagnosis dari imej angiografi sinar-X.

Dalam kajian ini, arteri koronari daripada kedua-dua modaliti tersebut didaftarkan untuk pembinaan semula 3D dan visualisasi kedudukan stenosis. Sepanjang dekad yang lalu, beberapa algoritma telah dibangunkan untuk mendaftarkan arteri koronari dengan modaliti yang dinyatakan di atas. Walau bagaimanapun, kebanyakannya gagal untuk mendaftarkan arteri koronari untuk menganggarkan titik stenosis dari angiografi sinar-X kepada modaliti-modaliti tomografi berkomputer angiografi. Dalam kajian ini, kami melaporkan sumbangan baharu kepada bahagian-bahagian utama sistem pembinaan semula data jantung 3D multimodal.

Sumbangan pertama adalah mencadangkan kaedah pensegmenan automatik arteri koronari dan pelabelan dari angiografi sinar-X, berdasarkan cadangan *Starlet Wavelet* yang diubahsuai untuk segmentasi supaya kaedah tersebut boleh digunapakai untuk pendafttaran dengan modaliti-modaliti yang lain. Purata nilai ketepatan, kesensitifan, pengkhususan dan kepersisan kaedah yang dicadangkan dalam angiogram LCA adalah masing-masing 0.96934, 0.86014, 0.98439 dan 0.87797. Manakala nilai dari angiogram RCA adalah masing-masing 0.97425, 0.89962, 0.99587 dan 0.93021. Jelas sekali, kaedah yang dicadangkan kukuh dalam semua metrik prestasi yang diukur. Juga,

dengan membandingkan keputusan yang dicapai, ia menunjukkan bahawa kaedah yang dicadangkan mempunyai artifak yang minimum dan pensegmenan merangkumi keseluruhan bahagian arteri koronari. Tambahan pula, masa larian bagi kaedah yang dicadangkan adalah jauh lebih baik daripada kaedah lain dan secara keseluruhan proses yang diperlukan adalah kurang daripada sesaat.

Sumbangan kedua adalah mencadangkan kaedah yang cepat dan tepat untuk segmentasi 3D koronari arteri utama dan pelabelan dari angiografi CT berdasarkan kaedah penjejakan persilangan yang dicadangkan dan penapis pembuluh darah yang ditambahbaik. Eksperimen yang telah dijalankan ke atas set data klinikal telah membuktikan bahawa kaedah yang dicadangkan dapat meningkatkan penilaian pertindanan keseluruhan pensegmenan arteri koronari 3D dan pelabelan dari tomografi berkomputer angiografi sebanyak 95.76%. Di samping itu, kaedah yang dicadangkan lebih pantas dari kaedah sebelumnya kerana pendaftaran tidak diperlukan untuk kaedah penjejakan persilangan. Pensegmenan dan pelabelan yang digunakan pada masa yang sama juga memberi faedah kepada kaedah didalam kajian ini.

Penyarian sifat berasaskan pendaftaran arteri koronari dalam tomografi berkomputer angiografi dan modaliti angiografi sinar-X dengan menggunakan ciri-ciri yang disediakan di kedua-dua modaliti adalah sumbangan ketiga dalam kajian tesis ini. Ujian menggunakan set data klinikal telah menunjukkan kaedah yang dicadangkan dapat membantu pakar untuk mengesan lokasi stenosis dan juga menentukan hubungan visual di antara arteri koronari yang sepadan iaitu jarak 3D dengan nilai purata 3.375 mm dan sisihan piawai $\pm$ 1.4137 mm dalam masa pemprosesan maksimum iaitu 0.2 saat bagi setiap pendaftaran arteri koronari.

Kajian penyelidikan yang dicadangkan adalah relevan dan mudah alih untuk komputer peribadi dan memenuhi standard kaedah pemerolehan perubatan. Selain itu, standard pemerolehan perubatan tidak berubah dalam kajian ini. Ia bermaksud tiada penentukuran dalam peranti pemerolehan diperlukan. Manfaat lain dari hasil kajian ini adalah setiap arteri koronari yang sepadan daripada kedua-dua modaliti ini boleh didaftarkan secara individu. Akhir sekali, hasil keputusan keseluruhan pepohon arteri koronari termasuk stenosis boleh digabungkan dan dipaparkan.

ACKNOWLEDGEMENTS

First and foremost, I would like to thank my supervisor, Assoicated Prof. Dr. Rahmita Wirza O.K. Rahmat, for the patient guidance, encouragement and advice. Also, I am grateful to my co supervisor, Dr Puteri Suhaiza Binti Sulaiman, for her good comments as well as her financial support during my candidature. Their encouragement and help made me feel confident to overcome every difficulty I encountered in all time of the research and writing of this thesis. I also would like to express my sincere thanks and appreciation to my supervisory committee members, Prof. Zamrin Dimon and Dr. Fatimah Binti Khalid for their guidance, valuable suggestions and advice throughout this research work. I must express my deep gratitude to Prof. Zamrin Dimon and medical staff of cardiology department of UiTM Hospital (Malaysia) for providing a lot of data source which allowed me to undertake this research and also for giving me the opportunity to attend their work place and gain a lot of experience by observing many real examination procedures as well as getting familiar with so many interesting people.

I would like to express my gratefulness to Mahta, my wife, for her continued support and encouragement. I also appreciate the patience of my father and mother for their unconditional love and support, but I know very well my absence from home has never been easy for them.

I certify that a Thesis Examination Committee has met on 08 June 2016 to conduct the final examination of Seyed Rohollah Moosavitayebi on his thesis entitled "3D Multimodal Cardiac Data Reconstruction Using Computerized Tomographic Angiography and X-ray Angiography Registration in accordance with the Universities and University Colleges Act 1971 and the Constitution of the Universiti Putra Malaysia [P.U.(A) 106] 15 March 1998. The Committee recommends that the student be awarded the Doctor of Philosophy.

Members of the Thesis Examination Committee were as follows:

Hamidah Binti Ibrahim, PhD
Professor
Faculty of Computer Science and Information Technology
Universiti Putra Malaysia
(Chairman)

M. Iqbal Bin Saripan, PhD
Professor
Faculty of Engineering
Universiti Putra Malaysia
(Internal Examiner)

Muhamad Taufik Bin Abdullah, PhD
Associate Professor
Faculty of Computer Science and Information Technology
Universiti Putra Malaysia
(Internal Examiner)

Gustavo Carneiro, PhD
Associate Professor
University of Adelaide
Australia
(External Examiner)

ZULKARNAIN ZAINAL, PhD
Professor and Deputy Dean
School of Graduate Studies
Universiti Putra Malaysia

Date: 26 July 2016

This thesis was submitted to the Senate of Universiti Putra Malaysia and has been accepted as fulfilment of the requirement for the degree of Doctor of Philosophy. The members of the Supervisory Committee were as follows:

Rahmita Wirza O.K. Rahmat, PhD
Associate Professor
Faculty of Computer Science and Information Technology
Universiti Putra Malaysia
(Chairman)

Puteri Suhaiza binti Sulaiman, PhD
Senior Lecturer
Faculty of Computer Science and Information Technology
Universiti Putra Malaysia
(Member)

Fatimah Khalid, PhD
Associate Professor
Faculty of Computer Science and Information Technology
Universiti Putra Malaysia
(Member)

Mohd Zamrin Dimon, PhD
Professor
Faculty of Medicine
Universiti Teknologi MARA (UiTM), Malaysia
(Member)

BUJANG BIN KIM HUAT, PhD
Professor and Dean
School of Graduate Studies
Universiti Putra Malaysia

Date:

Declaration by graduate student

I hereby confirm that:

- This thesis is my original work;
- quotations, illustrations and citations have been duly referenced;
- this thesis has not been submitted previously or concurrently for any other degree at any other institutions;
- intellectual property from the thesis and copyright of the thesis are fully-owned by Universiti Putra Malaysia, as according to the Universiti Putra Malaysia (Research) Rules 2012;
- written permission must be obtained from supervisor and the office of Deputy Vice-Chancellor (Research and Innovation) before thesis is published (in the form of written, printed or in electronic form) including books, journals, modules, proceeding, popular writings, seminar papers, manuscripts, posters, reports, lecture notes, learning modules or any other materials as stated in the Universiti Putra Malaysia (Research) Rules 2012;
- there is no plagiarism or data falsification/ fabrication in the thesis, and scholarly integrity is upheld as according to the Universiti Putra Malaysia (Graduate Studies) Rules 2003 (Revision 2012-2013) and the Universiti Putra Malaysia (Research) Rules 2012. The thesis has undergone plagiarism detection software.

Signature:_____ Date:_____

Name and Matric No.: Seyed Rohollah Moosavitayebi, GS31568

Declaration by Members of Supervisory Committee

This is to confirm that:

- the research conducted and the writing of this thesis was under our supervision;
- supervision responsibilities as stated in the Universiti Putra Malaysia (Graduate Studies) Rules 2003 (Revision 2012-2013) are adhered to.

Signature: _____
Name of Chairman of Supervisory Committee: _____

Signature: _____
Name of Member of Supervisory Committee: _____

Signature: _____
Name of Member of Supervisory Committee: _____

Signature: _____
Name of Member of Supervisory Committee: _____

TABLE OF CONTENTS

LIST OF TABLES

LIST OF FIGURES

LIST OF ABBREVIATIONS

2D	Two Dimensional
3D	Three Dimensional
CABG	Coronary Artery Bypass Graft
CAD	Computer Aided Design
CTA	Computed Tomography Angiography
CT	Computed Tomography
CVD	Cardiovascular Diseases
DICOM	Digital Imaging and Communications
DSA	Digital Subtracting Angiography
ECG	Electrocardiography
ICP	Iterative Closest point Algorithm
IVUS	Intravascular Ultrasound
FN	False Negative
FP	False Positive
GUI	Graphical User Interface
LAD	Left Anterior Descending
LCA	Left Coronary Artery
LCx	Left Circumflex
MRA	Magnetic Resonance Angiography
MRI	Magnetic Resonance Imaging
OT	Operating Theatre
PCI	Percutaneous Coronary Intervention
PCMRI	Phase Contrast Magnetic Resonance Imaging
PET	Positron Emission Tomography
R^3	Real Coordinate Space with Three Dimension
SNR	Signal-to-Noise Ratio
RCA	Right Coronary Artery
RGB	Red, Green and Blue
RMSE	Root Mean Square Error
ROI	Region of Interest
SD	Standard Deviation
SPECT	Single Positron Emission Tomography
T	Threshold number
TN	True Negative
TP	True Positive

CHAPTER 1

INTRODUCTION

This chapter serves as the starting point for the entire thesis. It commences with the presentation of the background of heart anatomy, coronary artery disease, and coronary artery imaging techniques. Then, the motivation of the research interest in the 3D multimodal cardiac reconstruction is presented. The details of the research's problem statement, research objectives, research scope, and research contributions are given in the next sections, respectively. The final section presents the organization of the whole thesis.

1.1 Background

This section presents a brief medical background and medical imaging systems related to human heart. It starts with the basic concepts of heart anatomy, as the subject of this thesis is computational algorithms for medical assisted surgery. Subsequently, a brief view of diseases that may occur in coronary arteries is explained, and coronary artery imaging techniques are generally introduced. The properties of X-ray angiography and computerized tomography angiography acquired in coronary artery imaging procedures are explained in detail because they are used as the data sets of this thesis.

1.1.1 Heart Anatomy

A heart is an organ that provides oxygen and blood to all body parts. As illustrated in Figure 1.1, the heart is separated by a divider called partition (or septum) into two parts, and each part has two chambers. The heart is about the size of any closed fist (12 cm in length and 9 cm in width), weighs about 300 g, and is particularly formed as a cone. It is located in the chest hole merely posterior towards the breastbone, between the lung area and also upper than the diaphragm. The heart is enclosed with a liquid-filled sac known as pericardium and also comprises of heart muscle tissue that enables the heart to contract and permits the synchronization with the heartbeat. The heart wall can be split directly into three layers; endocardium, myocardium, and epicardium. Endocardium is an internal layer, which is continuous with all the internal lining of blood vessels. Myocardium is a middle layer wall of the heart, and epicardium is an external protective layer of the heart. The body consists of a complex network of hollow pipes known as blood vessels. Blood is pumped away from the heart by means of arteries (arterial blood vessels) and also returned to the heart through veins. According to [2], a cardiovascular system consists of veins, arteries, the heart, and small blood vessels that transport blood to entire the body. The major artery in the body is aorta.

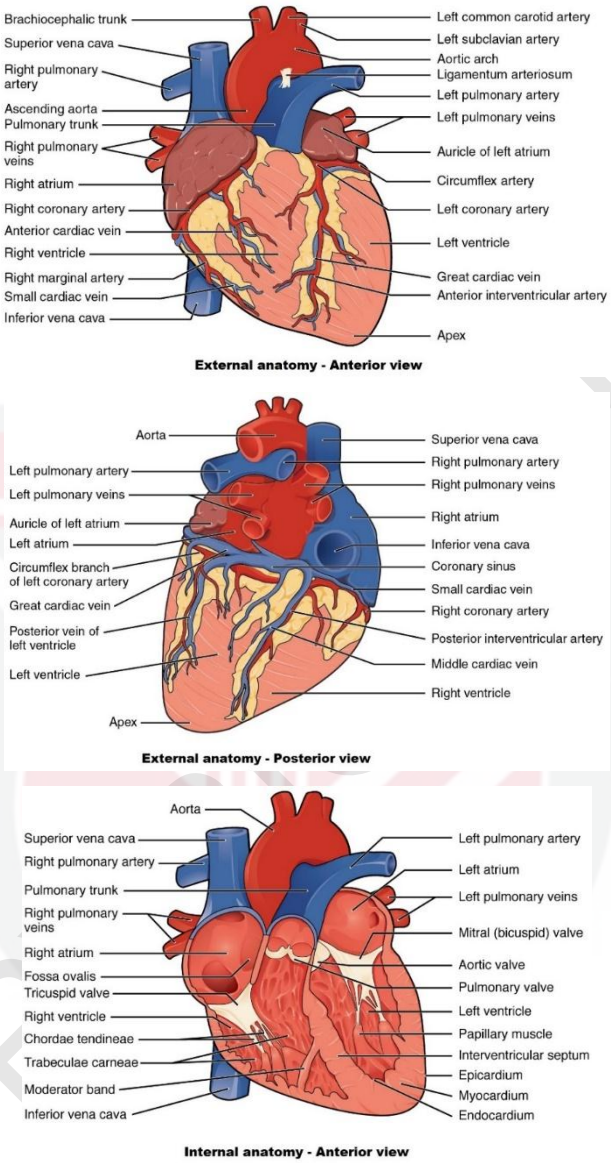

Figure 1.1: Examples of external and internal anatomies of the heart [1].

1.1.2 Coronary Artery Disease (CAD)

The cardiovascular system is liable for transporting around 3000 gallons of blood in the body every day. The heart itself requires blood to perform its functions properly. The source of feeding the heart with oxygen-rich blood is coronary arteries. Indeed, the coronary arteries are a vital part of the cardiovascular system, which mostly relies on the surface of the heart and transports the blood to the heart muscle. As shown in Figure 1.2, coronary artery vessels are categorized into two principal parts; right coronary artery

(RCA) and left coronary artery (LCA). RCA stems from the right aortic sinus and LCA stems from the left aortic sinus. The first part of the left coronary artery is referred to as the left main coronary artery (LM). This blood vessel can be about 5 mm wide and less than 30 mm long. LM branches directly into a pair of arteries; left circumflex coronary artery (LCX) and left anterior descending coronary artery (LAD). LCX circles around the left side of the heart, which is embedded throughout the surface of the rear side of the heart. LAD is embedded throughout the surface of the front side of the heart. Each LCX and LAD artery bifurcates into smaller sub-arteries; three septal arteries (S1~S3) and three diagonal arteries (D1~D3) that originate from LAD, and also two marginal arteries (OM1 and OM2) from LCX. The end of RCA bifurcates into a pair of smaller arteries; right posterior lateral branch (R-PLB) and right posterior descending artery (R-PDA).

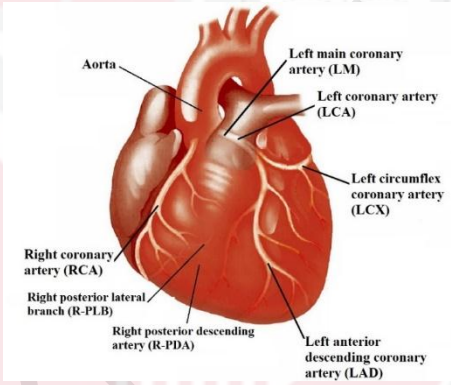

Figure 1.2: Cardiovascular system anatomy – coronary arteries

Among the cardiovascular system diseases, coronary artery disease (CAD) is an important issue, which usually stands behind the loss of life around the world today. Therefore, a precise method to visualize coronary arteries is highly needed. In fact, CAD is associated with blockage, as well as narrowing the left or right coronary artery vessels. Figure 1.3 illustrates the effects of CAD through build-up of fat and also cholesterol residua known as plaques within coronary arteries. Plaque (or cholesterol) is often produced as a fatty material in the liver and moves through the entire human body. After a while, the amount increases and narrows the coronary arteries, as well as blocks the blood circulation on the coronary arteries. This process is referred to atherosclerosis, which partly or perhaps entirely blocks the blood circulation to cardiovascular system. This problem might lead to injury or even led to the death of parts of heart muscle, which caused heart attack.

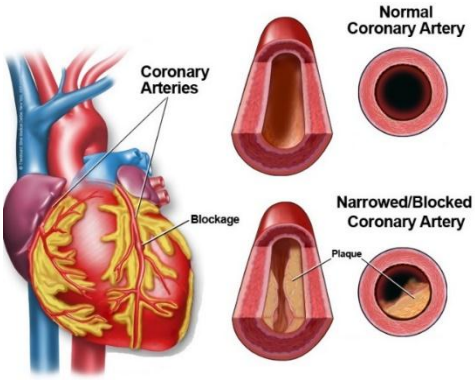

Figure 1.3: Coronary artery disease (CAD). A normal coronary artery with normal blood flow and a coronary artery with plaque build-up [3].

1.1.3 Coronary Artery Imaging Techniques

In this section, the medical imaging techniques that can be used for coronary artery imaging are introduced. Over the last three decades, there has been a fast progress in cardiovascular imaging techniques that can be used for diagnosing coronary artery diseases. As depicted in Table 1.1, there are several coronary artery imaging techniques; cardiac X-ray angiography, cardiac computerized tomography angiography (CCTA), magnetic resonance angiography (MRA), single-photon emission computed tomography (SPECT), and others.

Table 1.1: Advances in medical imaging techniques related to coronary arteries.

	Year	Medical imaging techniques
1	1895	Chest X-ray
2	1896	Fluoroscopy
3	1940	X-ray Angiography
4	1972	Computed Tomography (CT)
5	1984	Cardiac Computerized Tomography Angiography (CT Angiography)
6	1984	Magnetic Resonance Angiography (MRA) [4]
7	1990	Electron Beam Computerized Tomography (EBCT)
8	1990	Single-Photon Emission Computed Tomography (SPECT)
9	1991	Optical Coherence Tomography [5]
10	1994	Intracoronary Ultrasound [6]
11	2004	64-slice CT Scanning

Among these modalities, cardiac computerized tomography angiography (CT angiography or briefly CTA), and also cardiac X-ray angiography (X-ray angiography, X-ray arteriography or briefly angiography) are the best ways for visualizing coronary arteries and CAD diagnosis. Therefore, these image modalities have been focused, which are closely related to this work.

1.1.3.1 X-ray Angiography

X-ray angiography is well used to visualize coronary arteries and diagnose their blockage and stenosis in real-time. Therefore, most physicians prefer to use this modality instead of others to diagnose and treat CAD. Coronary artery angiography is performed by injecting the radio-opaque contrast agent into the coronary arteries and imaging using X-ray based techniques such as fluoroscopy. A series of blood vessel radiographs is called angiograms (or angiographs). As shown in Figure 1.4, a typical X-ray angiography suite setup consists of a radiographic table, in which the patient lays on, a coronary angiogram contrast injector machine, a C-arm device and one or more monitors attached to the C-arm imaging device. The C-arm allows real-time digital X-ray image acquisition in different planes, which is mobile in 360 degrees.

Figure 1.4: A typical x-ray angiography suite setup (Taken from UiTM Medical Center).

Figure 1.5 shows some X-ray angiograms of coronary arteries from one subject of the data set. The major drawback of X-ray angiography technique is being invasive and also lack of 3D information about coronary arteries and their stenosis point. A 3D coronary artery reconstruction becomes essential after acquiring 2D X-ray angiograms.

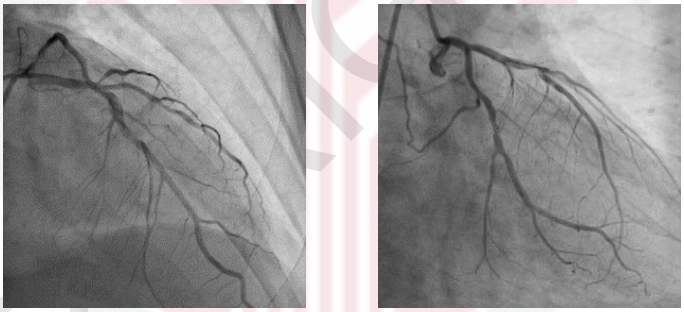

Figure 1.5: X-ray angiograms of coronary arteries from one subject in different views (Courtesy of UiTM Medical Center, Malaysia).

1.1.3.2 Computerized Tomography Angiography (CT Angiography)

Generally, CT scan is a form of X-ray, which utilizes a computer system to generate cross-sectional images of the human body. In this technique, a 3D image of a component can be reconstructed from a series of 2D X-ray. This technique was introduced by Hounsfield in 1972. Since then, five generations of CT scan devices have been manufactured with different scanning motion and tube-detector configuration. Table 1.2 presents five generations of CT scanner technology.

The modern progress of CT scan devices signifies a promising future for CT imaging utilized in coronary artery disease diagnosis. The speed benefits of

64-slice CT enable it to be used for cardiac imaging. Dual source CT scanner together with dual X-ray tubes and also dual array of 64-slice detectors have been introduced by Siemens in 2005. This technique permits better temporal resolution by obtaining a complete CT slice in one fourth of the rotation. Therefore, it reduces motion blurring at high heart rates and also makes it possible to hold breath in shorter time. Using the advancement in subsecond rotation speeds coupled with multi-slice CT (about 320 slices by 2009 [7]), higher resolution and higher speed CT scanner can be acquired at the same time. Therefore, it allows this technique to be utilized for cardiovascular imaging.

Table 1.2: Five generations of CT scanner technology [8].

Generation	Minimum scan time	Number of detectors	Beam	Configuration
1st	2.5 min	1 ~ 2	Pencil thin	Translate - rotate
2nd	10 sec	3 ~ 52	Narrow fan	Translate - rotate
3rd	0.5 sec	256 ~ 1000	Wide fan	Rotate - rotate
4th	1 sec	600 ~ 4800	Wide fan	Rotate - fixed
5th	33 ms	1284	Wide fan electron beam	Electron beam

CT angiography is a type of medical exam that mixes CT scan with the injection of a specific dye, referred to as a contrast material, to generate images of vessels in specific parts of the body. For this aim, the contrast material is often injected into a vein started in the hand or arm. Figure 1.6 illustrates a typical CT angiography suite setup.

Figure 1.6: A typical CT angiography suite setup (Taken from UiTM Medical Center).

When CT angiography is done, a series of images will be created, which can be observed as an axial view of cardiac components, such as cardiac chambers, aorta, heart's muscle and coronary arteries as well. These images are referred to as CT angiography slices throughout this thesis. From this modality, one can get the 3D reconstruction of coronary arteries and also find

out whether a plaque build-up has narrowed patient's vessels or not. Figure 1.7 shows some CT angiography slices from one subject of the data set.

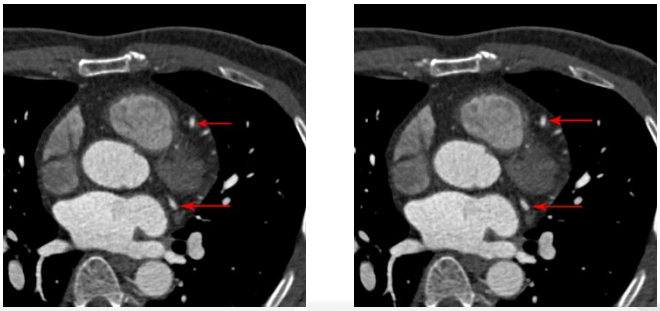

Figure 1.7: Two sequential CT angiography slices from one subject. Red arrows point to the coronary arteries (Courtesy of UiTM Medical Center, Malaysia).

1.2 Motivation and Importance of the Study

It is extensively recognized that coronary artery disease (CAD) is the major reason behind death and also handicap throughout the world. In 2004, approximately 7.2 million of deaths worldwide was caused by this disease. Unfortunately, 82% of these deaths happened in middle and low-income countries [9]. Coronary arteries are a principle resource utilized by the heart to transport nutrition and also oxygen required to pump blood throughout the body. Figure 1.8 shows a blockage inside a coronary artery caused by a mix of waxy substances. Data information from the Unit of the Ministry of Health Malaysia indicates that cardiovascular diseases have been the main reason behind the death in hospitals, responsible for 25.4%-33% of deaths from 2006 to 2010 [10]. Therefore, a great number of research is performed at present to determine the reasons behind cardiovascular disease and also to assist its diagnosis and therapy.

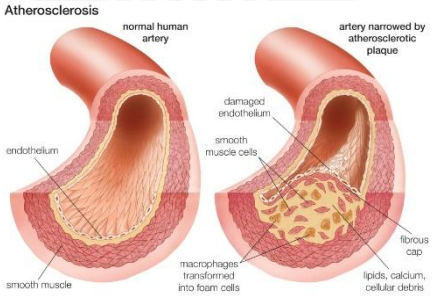

Figure 1.8: Cross-sectional explanation of coronary arteries demonstrating a normal (healthy) artery and a narrowed one (atherosclerosis) [11].

Coronary artery imaging techniques have played a significant role in the research associated with coronary artery disease diagnosis and treatment. A variety of medical imaging techniques have been utilized over the years. Among these techniques, X-ray angiography and CT angiography are the best method for specialists (cardiologists and cardiac surgeons) for the purpose of coronary artery disease diagnosis and treatment. In spite of the increased usage of X-ray angiography and CT angiography nowadays, however, some important information cannot be obtained by using each of these modalities alone, even for experienced specialists. From the technical standpoint, there are several complexities to produce precise 3D stenosis positioning, as it is a complicated task. These include:

- Limitations associated with the output of X-ray angiography (angiogram), such as 2D information. However, it is possible to detect all types of stenosis lesions in coronary arteries from this modality.
- Limitations associated with the output of CT angiography. For example, it is not possible to visualize all types of stenosis lesions in coronary arteries. However, the output of CT angiography is 3D and also includes information about other cardiac components.

These limitations have been confirmed by expert cardiologists and surgeons that participated in the validation stage of final results to detect stenosis locations in 2D coronary X-ray angiography and 3D CT angiography. This motivated the researcher to propose a set of computational algorithms for 3D multimodal stenosis reconstruction using X-ray angiography and CT angiography.

1.3 Problem Statement

Different modalities hold different information in assisting physicians in making decision. Previously, they viewed these images in separate or adjacent windows, and mentally fused these images together. Even though medical image registration and image fusion have been successfully implemented for other organs such as the brain and lungs, medical image registration and fusion for the heart present different challenges [12-14]. First, since the heart is beating, fusion requires synchronization with the rhythm of the heart for different phases. Second, the heart is a non-solid organ, thus acquired images give a vague impression.

Precise computer-assisted coronary artery analysis is consequential in later diagnosis and treatment with cardiologists and cardiac surgeons. As explained in Section 1.1.3, X-ray angiography and CT angiography are the best modalities to visualize coronary arteries and CAD diagnosis. Individually, these modalities provide valuable information, but do not represent complete information about coronary arteries. Thus, it is important for specialists (cardiologists or cardiac surgeons) to combine informative data in both modalities. Indeed, specialists believe that access to some extra information about stenosis points in coronary arteries extracted from angiogram, such as

the 3D position and their relative localization with respect to the corresponding coronary artery from CT angiography, is an important aid in CAD diagnosis and treatment.

There are several hybrid devices such as SPECT/CT, PET/CT, PET/MRI and MRI/PET, which give combined informative data. To the best of our knowledge, no hybrid device is available for combining the results of X-ray angiography and CT angiography devices. Moreover, these devices are very expensive and none returns the 3D position of stenosis lesion of coronary arteries. In a successful manner, these two modalities are available in most hospitals nowadays. Therefore, one way to aid specialists is to set up the connection between stenosis points from an X-ray angiography along with their 3D positions of coronary arteries from CT angiography, so that they have a 3D informative model consisting of stenosis and coronary arteries' information from both modalities. To achieve this aim, it is highly required that first, the coronary arteries are segmented and labeled, their control points are also extracted precisely from both modalities. Then, an appropriate registration can be computed based on these results.

1.4 Research Objectives

The main aim of this research project is to propose a new framework for coronary artery registration in X-ray angiography and CT angiography modalities to provide the 3D position of the stenosis. It will assist medical specialists to perform diagnosis and treatment by providing them with the relationship between these two modalities. To achieve this, stenosis lesion positions are reconstructed in 3D through CT angiography and X-ray angiography images registration. The following are the objectives in order to achieve the main goal of the study:

- To propose a new method of segmenting and labeling the coronary arterial tree in X-ray angiography images using enhanced starlet wavelet transform.
- To introduce a method of 3D main coronary artery segmentation and labeling in CT angiography using a new proposed intersection tracking technique.
- To reconstruct 3D multimodal cardiac data using a new proposed feature-based coronary artery registration in CT angiography and angiogram.

1.5 Research Scope

The focus of this research is to propose a new method for coronary artery registration from X-ray angiography and CT angiography images, which has the ability to be applied for 3D stenosis point registration in these two modalities. The proposed method deals with the C-arm 2D X-ray angiography devices and 3D CT angiography machines, which can be used for 3D stenosis

position visualization. Since the stenosis points can be visualized only in some X-ray angiography's frames, it is assumed that the best frame and also the best view of angiograms has already been chosen by the specialist. In addition, the medical acquisition standards in both X-ray angiography and CT angiography remain unchanged, which means that no calibration is required in the acquisition devices.

1.6 Research Contributions

The outcome of this research is a computer aided system that assist cardiac surgeons and cardiologists to visualize 3D stenosis point through CT angiography and X-ray angiography modalities. The contributions of this research are as follows:

- A fast, accurate, and fully automatic method for coronary artery segmentation from X-ray angiography images based on the proposed modified starlet wavelet transform. The proposed method enhances the ability of coronary artery segmentation from angiogram in increasing the accuracy and reducing the artifacts in segmentation results. As discussed in Chapter 4, the average accuracy, sensitivity, specificity, and precision values of the proposed method in LCA angiograms are 0.96934, 0.86014, 0.98439, and 0.87797, respectively, and in RCA angiograms, the values are 0.97425, 0.89962, 0.99587, and 0.93021, respectively. It also performs at least two times faster than previous methods. Using this method, it is also feasible to label coronary arteries and detect control points.
- A fast and accurate method for 3D main coronary artery segmentation and labeling from CT angiography using the proposed intersection tracking method. By conducting experiments on the clinical data sets, it is proven that the proposed method improves the ability of 3D coronary artery segmentation and labeling from CT angiography in increasing the overall overlap evaluation to 95.76%, as discussed in Chapter 5. In addition, since the segmentation and labeling are done at the same time in the proposed method, without any further process, the method is faster compared to previous methods.
- A fast and accurate method for coronary artery registration from CT angiography and X-ray angiography images. The proposed method enhances the ability of coronary artery registration in these two modalities and also it reduces the time complexity compared to conventional registration methods in these modalities. As discussed in Chapter 6, clinical data set tests demonstrated that the proposed method aided the specialists to find the location of stenosis lesion and also to determine the visual relationship between the corresponding coronary arteries, and a mean accuracy of $3.375\ \mathrm{mm}$ and standard deviation of $\pm 1.4137\ \mathrm{mm}$ (3D distance) have been achieved in a maximum processing time of 0.2 s for each coronary artery registration.

1.7 Outline of the Thesis Structure

There are three styles of research structure in UPM based on the School of Graduate Studies (GSO) guideline for thesis preparation (2009). The second style has been chosen for this thesis, in which a thesis is inherently divided into four parts; introduction, literature review, research methodology, and conclusion. Each research chapter represents a separate study, which includes its introduction, methodology, and also results and discussion. Thus, this thesis only has four research parts, which complement the technical elements that form the project under discussion. Subsequently, the overall organization of the thesis is as follows:

- Chapter 1 serves as the introduction of this thesis. It starts with a background about the heart anatomy, coronary artery diseases, and the latest techniques used for coronary artery imaging, as this thesis is involved with a medical problem statement. Next, a brief explanation of what motivates the interest to do this research is presented. Moreover, this chapter clarifies the problem statement, objectives, and scope of the research.
- Chapter 2 gives a literature review on coronary artery segmentation and labeling from angiogram, coronary artery segmentation, labeling and 3D reconstruction from CT angiography, as well as coronary artery registration in angiogram and CT angiography modalities. The current challenges in each of these issues are also described.
- Chapter 3 presents the research methodology used to accomplish the current research project. The chapter discusses the research steps taken to conduct this study from the problem statement to performance evaluation.
- Chapter 4 to 6 present the original contributions of this thesis, dedicated to introduce the details of the proposed method for coronary artery segmentation and labeling from angiogram, coronary artery segmentation, labeling and 3D reconstruction from CT angiography, and also coronary artery registration in these two modalities. Each of these chapter consists of these parts: an introduction, the proposed methodology, implementation, experimental results and discussion, advantages and limitations of the proposed method, and summary.
- Chapter 7 includes the conclusions that can be drawn from the present study. Additionally, this chapter suggests for future research and continuation of this work.

REFERENCES

[1] Biology, http://biology.about.com, 2014.

[2] Anatomy and Physiology, http://philschatz.com/anatomy-book, 2014.

[3] Coronary Artery Disease, http://www.mountsinai.org/interventional-cardiology-cath-lab, 2014.

[4] R. Herfkens, C. Higgins, H. Hricak, M. Lipton, L. Crooks, P. Lanzer, E. Botvinick, B. Brundage, P. Sheldon, L. Kaufman, Nuclear magnetic resonance imaging of the cardiovascular system: normal and pathologic findings ,Radiology 147, 749-759, 1983.

[5] D. Huang, E.A. Swanson, C.P. Lin, J.S. Schuman, W.G. Stinson, W. Chang, M.R. Hee, T. Flotte, K. Gregory, C.A. Puliafito, Optical coherence tomography , Science, 254, 1178-1181, 1991.

[6] S. Nakamura, A. Colombo, A. Gaglione, Y. Almagor, S.L. Goldberg, L. Maiello, L. Finci, J.M. Tobis, Intracoronary ultrasound observations during stent implantation, Circulation 89, 2026-2034, 1994.

[7] J.E. van Velzen, J.D. Schuijf, F.R. de Graaf, G. Nucifora, G. Pundziute, J.W. Jukema, M.J. Schalij, L.J. Kroft, A. de Roos, J. Reiber, Plaque type and composition as evaluated non-invasively by MSCT angiography and invasively by VH IVUS in relation to the degree of stenosis,Heart 95, 24, 1990-1996, 2009.

[8] E.K. Fishman et al., The Advanced Medical Imaging Laboratory, Department of Radiology, Johns Hopkins Medical Institutions, Baltimore, 2014.

[9] W.H. Organization, The 10 leading causes of death by broad income group, Fact Sheet, 2012.

[10] Rasiah, R., Yusoff, K., Mohammadreza, A., Manikam, R., Tumin, M., Chandrasekaran, S.K., Khademi, S., and Bakar, N.A.: 'Cardiovascular disease risk factors and socioeconomic variables in a nation undergoing epidemiologic transition', BMC public health, 13, (1), pp. 886, 2013.

[11] E. Britannica., Cardiovascular Disease - Cross Sectional Explanation of Coronary Arteries, Encyclopedia Britannica Online, 2015.

[12] X. Zhuang, K.S. Rhode, R.S. Razavi, D.J. Hawkes, S. Ourselin, A registration-based propagation framework for automatic whole heart segmentation of cardiac MRI, IEEE Transactions on Medical Imaging,29, 1612-1625, 2010.

[13] A.P. James, B.V. Dasarathy, Medical image fusion: A survey of the state of the art, Information Fusion 19, 4-19, 2014.

[14] B. Fischer, J. Modersitzki, Image fusion and registration – a variational approach, Computational Science and High Performance Computing II, Springer, pp. 193-203, 2006.

[15] C. Kirbas, F. Quek, A review of vessel extraction techniques and algorithms , ACM Computing Surveys (CSUR) 36, 81-121, 2004.

[16] R. Moosavi Tayebi, P. Suhaiza Binti Sulaiman, R. Wirza, M. Zamrin Dimon, S. Kadiman, L. Nurliyana Binti Abdullah, S. Mazaheri, Coronary artery segmentation in angiograms with pattern recognition techniques – A survey, International Conference on Advanced Computer Science Applications and Technologies, 321-326, 2013.

[17] M. Zeng, Y. Li, Q. Meng, T. Yang, J. Liu, Improving histogram-based image contrast enhancement using gray-level information histogram with application to X-ray images, Optik-international Journal for Light and Electron Optics 123, 511-520, 2012.

[18] D.J. Withey, W. Pedrycz, Z.J. Koles, Dynamic edge tracing: Boundary identification in medical images, Computer Vision and Image Understanding 113, 1039-1052, 2009.

[19] T. Aach, U. Schiebel, G. Spekowius, Digital image acquisition and processing in medical x-ray imaging, Journal of Electronic Imaging 8, 7-22, 1999.

[20] D. Guo, P. Richardson, Automatic vessel extraction from angiogram images, IEEE Computers in Cardiology, 441-444, 1998.

[21] M. Kumar, L. Wei, R. Turlapthi, J.S. Suri, DSA image enhancement via multi-resolution motion correction for interventional procedures: a robust strategy, ACTA Press, 330-335, 2007.

[22] D.L. Wilson, E.J. Kaplan, Linear and morphological digital image enhancement of peripheral angiography images, International Society for Optics and Photonics, 244-249, 1990.

[23] P.M. van der Zwet, J.H. Reiber, The influence of image enhancement and reconstruction on quantitative coronary arteriography, The International Journal of Cardiac Imaging 11 211-221, 1995.

[24] E.H. Meijering, K.J. Zuiderveld, M.A. Viergever, Image registration for digital subtraction angiography,International Journal of Computer Vision 31, 227-246, 1999.

[25] D. Lesage, E.D. Angelini, I. Bloch, G. Funka-Lea, A review of 3D vessel lumen segmentation techniques: Models, features and extraction schemes,Medical image analysis 13, 819-845, 2009.

[26] M. Plourde, L. Duong, Multi scale classification approach for coronary artery detection from X-ray angiography, 11th International Conference on Information Science, Signal Processing and their Applications (ISSPA), 181-186, 2012.

[27] C. Lacoste, G. Finet, I.E. Magnin, Coronary tree extraction from X-ray angiograms using marked point processes, 3rd IEEE International Symposium on Biomedical Imaging: Nano to Macro, 157-160, 2006.

[28] Y. Li, S. Zhou, J. Wu, X. Ma, K. Peng, A Novel Method of Vessel Segmentation for X-ray Coronary Angiography Images, Fourth International Conference on Computational and Information Sciences (ICCIS), 468-471, 2012.

[29] S. Wang, B. Li, S. Zhou, A Segmentation Method of Coronary Angiograms Based on Multi-scale Filtering and Region-Growing, International Conference on Biomedical Engineering and Biotechnology (iCBEB), 678-681, 2012.

[30] D.S. Lara, A.W. Faria, A. de A Araujo, D. Menotti, A semi-automatic method for segmentation of the coronary artery tree from angiography, Brazilian Symposium on Computer Graphics and Image Processing (SIBGRAPI), 194-201, 2009.

[31] H. Khaleel, R. Wirza, M. Zamrin Dimon, M. Ramlan, M. Norwati, Extraction of coronary artery trees in angiocardiography images, Scientific Research and Essays 7(47), 2012.

[32] P. Eichel, E. Delp, K. Koral, A. Buda, A method for a fully automatic definition of coronary arterial edges from cineangiograms, IEEE Transactions on Medical Imaging, 313-320, 1988.

[33] A. Hoover, V. Kouznetsova, M. Goldbaum, Locating blood vessels in retinal images by piecewise threshold probing of a matched filter response, IEEE Transactions on Medical Imaging, 203-210, 2000.

[34] R.C.G.a.R.E. Wood, Digital Image Processing, Prentice Hall, 2008.

[35] K. Haris, S. Efstratiadis, N. Maglaveras, C. Pappas, Semi-automatic extraction of vascular networks in angiograms, Proceedings of the 18th Annual International Conference of the IEEE Engineering in Medicine and Biology Society, 1996. Bridging Disciplines for Biomedicine., 1067-1068, 1997.

[36] K. Sun, N. Sang, E. Zhao, Extraction of vascular tree on angiogram with fuzzy morphological method, Int. J. Inf. Technol 11, 119-127, 2005.

[37] K. Sun, S. Jiang, Y. Wang, Segmentation of Coronary Artery on Angiogram by Combined Morphological Operations and Watershed, 2nd International Conference on Biomedical Engineering and Informatics, BMEI'09, 1-4, 2009.

[38] N. Ezquerra, S. Capell, L. Klein, P. Duijves, Model-guided labeling of coronary structure,IEEE Transactions on Medical Imaging, 429-441, 1998.

[39] K. Haris, S.N. Efstratiadis, N. Maglaveras, C. Pappas, J. Gourassas, G. Louridas, Model-based morphological segmentation and labeling of coronary angiograms, IEEE Transactions on Medical Imaging, 18, 1003-1015, 2000.

[40] A. Arulmurugan, D. Sharp, G. Murugadass, P. Kumar, Performance analysis of labeling technique for coronary arteries in angiogram images, 2011 International Conference on Electronics, Communication and Computing Technologies (ICECCT), 96-100, 2011.

[41] D.P. Zhang, Coronary artery segmentation and motion modelling, Imperial College London, 2010.

[42] C. Metz, M. Schaap, T. van Walsum, A. van der Giessen, A. Weustink, N. Mollet, G. Krestin, W. Niessen, 3D segmentation in the clinic: A grand challenge II-coronary artery tracking, Insight Journal, 2008.

[43] M. Schaap, C.T. Metz, T. van Walsum, A.G. van der Giessen, A.C. Weustink, N.R. Mollet, C. Bauer, H. Bogunović, C. Castro, X. Deng, Standardized evaluation methodology and reference database for evaluating coronary artery centerline extraction algorithms, Medical image analysis 13, 701-714, 2009.

[44] B. Bouraoui, C. Ronse, J. Baruthio, N. Passat, P. Germain, 3D segmentation of coronary arteries based on advanced mathematical morphology techniques, Computerized medical imaging and graphics 34, 377-387, 2010.

[45] N. Passat, C. Ronse, J. Baruthio, J.-P. Armspach, C. Maillot, Magnetic resonance angiography: from anatomical knowledge modeling to vessel segmentation, Medical image analysis 10, 259-274, 2006.

[46] B. Naegel, N. Passat, C. Ronse, Grey-level hit-or-miss transforms—part I: unified theory, Pattern Recognition 40, 635-647, 2007.

[47] B. Naegel, N. Passat, C. Ronse, Grey-level hit-or-miss transforms—Part II: Application to angiographic image processing, Pattern Recognition 40, 648-658, 2007.

[48] P. Soille, Morphological image analysis: principles and applications, Springer-Verlag New York, Inc., 2003.

[49] K. Haris, S.N. Efstratiadis, N. Maglaveras, C. Pappas, J. Gourassas, G. Louridas, Model-based morphological segmentation and labeling of coronary angiograms, IEEE Transactions on Medical Imaging ,18, 1003-1015, 1999.

[50] D. Mueller, A. Maeder, Robust semi-automated path extraction for visualising stenosis of the coronary arteries, Computerized medical imaging and graphics, 32, 463-475, 2008.

[51] O. Tankyevych, H. Talbot, P. Dokládal, N. Passat, Direction-adaptive grey-level morphology. Application to 3D vascular brain imaging, 16th IEEE International Conference on Image Processing (ICIP), 2261-2264, 2009.

[52] M.A. Luengo-Oroz, M.J. Ledesma-Carbayo, J. Gómez-Diego, M.A. García-Fernández, M. Desco, A. Santos, Extraction of the coronary artery tree in cardiac computer tomographic images using morphological operators, Functional Imaging and Modeling of the Heart, Springer, 424-432, 2007.

[53] Y. Masutani, T. Schiemann, K.-H. Höhne, Vascular shape segmentation and structure extraction using a shape-based region-growing model, Medical Image Computing and Computer-Assisted Interventation—MICCAI'98, Springer, pp. 1242-1249, 1998.

[54] M.H. Wilkinson, M.A. Westenberg, Shape preserving filament enhancement filtering, Medical Image Computing and Computer-Assisted Intervention–MICCAI, Springer, 770-777, 2001.

[55] B. Bouraoui, C. Ronse, J. Baruthio, N. Passat, P. Germain, Blur grey-level hit-or-miss transform for fully automatic 3D segmentation of coronary arteries, 9th international symposium on mathematical morphology (ISMM), University of Groningen, 37-40, 2009.

[56] D.S. Bloomberg, L. Vincent, Pattern matching using the blur hit–miss transform, Journal of Electronic Imaging 9, 140-150, 2000.

[57] X. Zhu, Z. Xue, X. Gao, Y. Zhu, S.T. Wong, Voles: Vascularity-oriented level set algorithm for pulmonary vessel segmentation in image guided intervention therapy, IEEE International Symposium on Biomedical Imaging: From Nano to Macro ISBI'09, 1247-1250, 2009.

[58] O. Friman, M. Hindennach, C. Kühnel, H.-O. Peitgen, Multiple hypothesis template tracking of small 3D vessel structures, Medical image analysis 14, 160-171, 2010.

[59] L.M. Lorigo, O. Faugeras, W.E.L. Grimson, R. Keriven, R. Kikinis, A. Nabavi, C.-F. Westin, Codimension-two geodesic active contours for the segmentation of tubular structures, Proceedings IEEE Conference on Computer Vision and Pattern Recognition, 444-451, 2000.

[60] L.M. Lorigo, O.D. Faugeras, W.E.L. Grimson, R. Keriven, R. Kikinis, A. Nabavi, C.-F. Westin, Curves: Curve evolution for vessel segmentation, Medical image analysis 5, 195-206, 2001.

[61] J. Jomier, V. LeDigarcher, S.R. Aylward, Comparison of vessel segmentations using staple, Medical Image Computing and Computer-Assisted Intervention–MICCAI 2005, Springer, pp. 523-530, 2005.

[62] M. Hernández-Hoyos, A. Anwander, M. Orkisz, J.-P. Roux, P. Douek, I.E. Magnin, A Deformable Vessel Model with Single Point Initialization for Segmentation, Quantification, and Visualization of Blood Vessels in 3D MRA, Medical Image Computing and Computer-Assisted Intervention – MICCAI 2000 Springer, 735-745, 2000.

[63] D. Nain, A. Yezzi, G. Turk, in, Medical Image Computing and Computer-Assisted Intervention–MICCAI 2004, Springer, pp. 51-59, 2004.

[64] J. Mille, L.D. Cohen, Deformable tree models for 2D and 3D branching structures extraction, IEEE Computer Society Conference on Computer Vision and Pattern Recognition Workshops CVPR Workshops 2009, 149-156, 2009.

[65] R. Goldenberg, D. Eilot, G. Begelman, E. Walach, E. Ben-Ishai, N. Peled, Computer-aided simple triage (CAST) for coronary CT angiography (CCTA), International journal of computer assisted radiology and surgery 7, 819-827, 2012.

[66] İ. Öksüz, D. Ünay, K. Kadıpaşaoğlu, A Hybrid Method for Coronary Artery Stenoses Detection and Quantification in CTA Images, MICCAI Workshop 3D Cardiovascular Imaging: A MICCAI Segmentation, 2012.

[67] G. Yang, P. Kitslaar, M. Frenay, A. Broersen, M.J. Boogers, J.J. Bax, J.H. Reiber, J. Dijkstra, Automatic centerline extraction of coronary arteries in coronary computed tomographic angiography,The international journal of cardiovascular imaging 28, 921-933, 2012.

[68] H. Kirişli, M. Schaap, C. Metz, A. Dharampal, W.B. Meijboom, S. Papadopoulou, A. Dedic, K. Nieman, M. De Graaf, M. Meijs, Standardized evaluation framework for evaluating coronary artery stenosis detection, stenosis quantification and lumen segmentation

algorithms in computed tomography angiography, Medical image analysis, 17, 859-876, 2013.

[69] G. Yang, A. Broersen, R. Petr, P. Kitslaar, M.A. de Graaf, J.J. Bax, J. Reiber, J. Dijkstra, Automatic coronary artery tree labeling in coronary computed tomographic angiography datasets, IEEE Computing in Cardiology, 109-112, 2011.

[70] A. Myronenko, X. Song, Point set registration: Coherent point drift, IEEE Transactions on Pattern Analysis and Machine Intelligence, 32, 2262-2275,2010.

[71] S. Cetin, G. Unal, Automatic detection of coronary artery stenosis in cta based on vessel intensity and geometric features, Proc. of MICCAI Workshop" 3D Cardiovascular Imaging: a MICCAI segmentation Challenge, 2012.

[72] İ. Öksüz, D. Ünay, K. Kadıpaşaoğlu, A Hybrid Method for Coronary Artery Stenoses Detection and Quantification in CTA Images, Proc. MICCAI Workshop 3D Cardiovascular Imaging: A MICCAI Segmentation,2012.

[73] K.-L. Lor, C.-M. Chen, Probabilistic Model Based Evaluation of Coronary Artery Stenosis on Computed Tomography Angiography, Proc. MICCAI Workshop 3D Cardiovascular Imaging: A MICCAI Segmentation, 2012.

[74] A. Eslami, A. Aboee, Z. Hodaei, M. Javanshir, S.C. Moghaddam, A. Katouzian, N. Navab, Quantification of Coronary Arterial Stenosis by Inflating Tubes in CT Angiographic images, Proc. MICCAI Workshop 3D Cardiovascular Imaging: A MICCAI Segmentation, 2012.

[75] W. Ahmed, M.A. de Graaf, A. Broersen, P.H. Kitslaar, E. Oost, J. Dijkstra, J.J. Bax, J.H. Reiber, A.J. Scholte, Automatic detection and quantification of the Agatston coronary artery calcium score on contrast computed tomography angiography, The international journal of cardiovascular imaging 31, 151-161, 2014.

[76] M.A. de Graaf, A. Broersen, W. Ahmed, P.H. Kitslaar, J. Dijkstra, L.J. Kroft, V. Delgado, J.J. Bax, J.H. Reiber, A.J. Scholte, Feasibility of an automated quantitative computed tomography angiography–derived risk score for risk stratification of patients with suspected coronary artery disease, The American journal of cardiology 113, 1947-1955, 2014.

[77] G. Yang, Y. Chen, Q. Sun, X. Ning, H. Shu, J.-L. Coatrieux, Fully Automatic Coronary Calcification Detection in Non-Contrast CT Images, National Basic Research Program of China, 2012.

[78] P. Medrano-Gracia, J. Ormiston, M. Webster, S. Beier, C. Ellis, C. Wang, A.A. Young, B.R. Cowan, Construction of a Coronary Artery Atlas from CT Angiography, Medical Image Computing and Computer-Assisted Intervention–MICCAI 2014, Springer, 513-520, 2014.

[79] Y. Li, W. Chen, K. Liu, Y. Wu, Y. Chen, C. Chu, B. Fang, L. Tan, S. Zhang, A Voxel-Map Quantitative Analysis Approach for Atherosclerotic Noncalcified Plaques of the Coronary Artery Tree, Computational and mathematical methods in medicine 2013, 2013.

[80] B. Zitova, J. Flusser, Image registration methods: a survey, Image and vision computing 21, 977-1000, 2003.

[81] J. Salvi, C. Matabosch, D. Fofi, J. Forest, A review of recent range image registration methods with accuracy evaluation, Image and vision computing, 25, 578-596, 2007.

[82] M. Deshmukh, U. Bhosle, A survey of image registration, International Journal of Image Processing (IJIP) 5, 245-269, 2011.

[83] M.V. Wyawahare, P.M. Patil, H.K. Abhyankar, Image registration techniques: an overview, International Journal of Signal Processing, Image Processing and Pattern Recognition 2, 11-28, 2009.

[84] J.P. Pluim, J.M. Fitzpatrick, Image registration, IEEE Transactions on Medical Imaging, 22, 1341-1343. 2003.

[85] W.R. Crum, T. Hartkens, D. Hill, Non-rigid image registration: theory and practice, The British Journal of Radiology, 2014.

[86] D.L. Hill, P.G. Batchelor, M. Holden, D.J. Hawkes, Medical image registration, Physics in medicine and biology, 46, 2001.

[87] D.G. Lowe, Distinctive image features from scale-invariant keypoints, International Journal of Computer Vision 60, 91-110, 2004.

[88] J.A. Maintz, M.A. Viergever, A survey of medical image registration , Medical image analysis 2, 1-36, 1998.

[89] A. Myronenko, Non-rigid image registration regularization, algorithms and applications, PhD thesis in Oregon Health & Science University, 2010.

[90] H. Fridman, T. Englund, Medical image registration, Lund Institute of Technology, Lund, Sweden, 2001.

[91] U.E. Aladl, T. Peters, Medical Image Registration, Multi Modality State-of-the-Art Medical Image Segmentation and Registration Methodologies, Springer, pp. 227-245, 2011.

[92] C.R. Maurer, J.M. Fitzpatrick, A review of medical image registration, Interactive image-guided neurosurgery 17, 1993.

[93] F. Maes, D. Vandermeulen, P. Suetens, Medical image registration using mutual information, Proceedings of the IEEE 91, 1699-1722, 2003.

[94] D. Rueckert, J.A. Schnabel, Medical image registration, Biomedical Image Processing, Springer, pp. 131-154, 2011.

[95] K. Kneöaurek, M. Ivanovic, J. Machac, D.A. Weber, Medical image registration, europhysics news 31, 5-8, 2000.

[96] J.P. Pluim, J.M. Fitzpatrick, Image registration, IEEE Transactions on Medical Imaging, 22, 1341-1343, 2003.

[97] F.P. Oliveira, J.M.R. Tavares, Medical image registration: a review, Computer methods in biomechanics and biomedical engineering 17, 73-93, 2014.

[98] A.A. Goshtasby, 2-D and 3-D image registration: for medical, remote sensing, and industrial applications, John Wiley & Sons, 2005.

[99] B. Zitova, J. Flusser, Image registration methods: a survey, Image and vision computing 21, 977-1000, 2003.

[100] S.R. Aylward, J. Jomier, S. Weeks, E. Bullitt, Registration and analysis of vascular images, International Journal of Computer Vision 55, 123-138, 2003.

[101] H. Chan, A.C. Chung, S.C. Yu, W. Wells, 2D-3D vascular registration between digital subtraction angiographic (DSA) and magnetic resonance angiographic (MRA) images, IEEE International Symposium on Biomedical Imaging: Nano to Macro, 708-711, 2004.

[102] C. Daul, J. Lopez-Hernandez, D. Wolf, G. Karcher, G. Ethévenot, 3-D multimodal cardiac data superimposition using 2-D image registration and 3-D reconstruction from multiple views, Image and vision computing, 27, 790-802, 2009.

[103] C. Metz, M. Schaap, S. Klein, P. Rijnbeek, L. Neefjes, N. Mollet, C. Schultz, P. Serruys, W. Niessen, T. van Walsum, Alignment of 4D coronary CTA with monoplane x-ray angiography, Augmented Environments for Computer-Assisted Interventions, Springer, pp. 106-116, 2012.

[104] D. Ruijters, B.M. ter Haar Romeny, P. Suetens, Vesselness-based 2D–3D registration of the coronary arteries, International journal of computer assisted radiology and surgery 4, 391-397, 2009.

[105] N. Baka, C. Metz, C. Schultz, L. Neefjes, R. van Geuns, B. Lelieveldt, W. Niessen, M. de Bruijne, T. van Walsum, 3D+ t/2D+ t CTA-XA registration using population-based motion estimates, MICCAI-Workshop on Computer Assisted Stenting Proceedings, MICCAISTENT, 12, 2012.

[106] M. Groher, F. Bender, R.-T. Hoffmann, N. Navab, Segmentation-driven 2D-3D registration for abdominal catheter interventions, Medical Image Computing and Computer-Assisted Intervention–MICCAI 2007, Springer, pp. 527-535, 2007.

[107] C.T. Metz, M. Schaap, S. Klein, N. Baka, L.A. Neefjes, J. Schultz, W.J. Niessen, T. van Walsum, Registration of Coronary CTA and Monoplane X-Ray Angiography, IEEE Transactions on Medical Imaging, 32, 919-931, 2013.

[108] H.-R. Kim, M.-S. Kang, M.-H. Kim, Non-rigid Registration of Vascular Structures for Aligning 2D X-ray Angiography with 3D CT Angiography, Advances in Visual Computing, Springer, pp. 531-539, 2014.

[109] G. Dibildox, N. Baka, M. Punt, J.-P. Aben, C. Schultz, W. Niessen, T. van Walsum, 3D/3D registration of coronary CTA and biplane XA reconstructions for improved image guidance, Medical physics, 41, 9, 2014.

[110] L. Duong, R. Liao, H. Sundar, B. Tailhades, A. Meyer, C. Xu, Curve-based 2D-3D registration of coronary vessels for image guided procedure, International Society for Optics and Photonics, 10, 7261-7275, 2009.

[111] C.T. Metz, M. Schaap, S. Klein, L.A. Neefjes, E. Capuano, C. Schultz, R.J. van Geuns, P.W. Serruys, T. van Walsum, W.J. Niessen, Patient specific 4D coronary models from ECG-gated CTA data for intra-operative dynamic alignment of CTA with X-ray images, Medical Image Computing and Computer-Assisted Intervention–MICCAI 2009, Springer, pp. 369-376, 2009.

[112] R. N. Ghanem, Ramanathan, C., Jia, P., & Rudy, Y. Heart-surface reconstruction and ECG electrodes localization using fluoroscopy, epipolar geometry and stereovision: application to noninvasive imaging of cardiac electrical activity, IEEE Transactions on Medical Imaging, 22, 1307-1318, 2003.

[113] A. D. Hoover, Kouznetsova, V., & Goldbaum, M. Locating blood vessels in retinal images by piecewise threshold probing of a matched filter response. IEEE Transactions on Medical Imaging, 19, 203-210, 2000.

[114] L. Sarry & Boire, J. Y. Three-dimensional tracking of coronary arteries from biplane angiographic sequences using parametrically deformable models. IEEE Transactions on Medical Imaging, 20, 1341-1351,2000.

[115] R. Zambahari, Trends in cardiovascular diseases and risk factors in Malaysia. Atherosclerosis XIII. Proceedings of the 13th International Atherosclerosis Symposium, Elsevier, 1262, 446-449, 2004.

[116] T. Saito, M. Misaki, K. Shirato, T. Takishima, Three-dimensional quantitative coronary angiography, IEEE Transactions on Biomedical Engineering , 37, 768-777, 1990.

[117] S. Wesarg, E.A. Firle, Segmentation of vessels: the corkscrew algorithm, Medical Imaging International Society for Optics and Photonics, 1609-1620, 2004.

[118] Y. Xu, H. Zhang, H. Li, G. Hu, An improved algorithm for vessel centerline tracking in coronary angiograms, Computer Methods and Programs in Biomedicine 88, 131-143, 2007.

[119] S.G. Mallat, A theory for multiresolution signal decomposition: the wavelet representation, IEEE Transactions on Pattern Analysis and Machine Intelligence, 11, 674-693, 1989.

[120] A. Ouahabi, Image Denoising Using Wavelets: Application in Medical Imaging, Advances in Heuristic Signal Processing and Applications, Springer, 287-313, 2013.

[121] E.J. Candes, D.L. Donoho, Curvelets, multiresolution representation, and scaling laws, International Society for Optics and Photonics, 1-12, 2000.

[122] A. Genovesio, T. Liedl, V. Emiliani, W.J. Parak, M. Coppey-Moisan, J.-C. Olivo-Marin, Multiple particle tracking in 3-D+ t microscopy: method and application to the tracking of endocytosed quantum dots, IEEE Transactions on Image Processing, 15, 1062-1070, 2006.

[123] J.-L. Starck, F. Murtagh, Astronomical image and data analysis, Springer, 2006.

[124] P. Bankhead, C.N. Scholfield, J.G. McGeown, T.M. Curtis, Fast retinal vessel detection and measurement using wavelets and edge location refinement, PloS one, 7, 3, 2012.

[125] J.-L. Starck, J. Fadili, F. Murtagh, The undecimated wavelet decomposition and its reconstruction, IEEE Transactions on Image Processing, 16, 297-309, 2007.

[126] J.-L. Starck, F. Murtagh, J.M. Fadili, Sparse image and signal processing: wavelets, curvelets, morphological diversity, Cambridge University Press, 2010.

[127] N. Otsu, A threshold selection method from gray-level histograms, Automatica 285-296, 11, 23-27, 1975.

[128] J. Han, M. Kamber, J. Pei, Data mining: concepts and techniques, Morgan kaufmann, 2006.

[129] C. Li, C.-Y. Kao, J.C. Gore, Z. Ding, Minimization of region-scalable fitting energy for image segmentation, IEEE Transactions on Image Processing , 17, 1940-1949, 2008.

[130] S. Zhou, J. Yang, W. Chen, Y. Wang, New approach to the automatic segmentation of coronary artery in X-ray angiograms, Science in China Series F: Information Sciences 51, 25-39, 2008.

[131] A.F. Frangi, W.J. Niessen, K.L. Vincken, M.A. Viergever, Multiscale vessel enhancement filtering, Medical Image Computing and Computer-Assisted Interventation—MICCAI'98, Springer, 130-137, 1998.

[132] H. Kirişli, M. Schaap, C. Metz, A. Dharampal, W.B. Meijboom, S. Papadopoulou, A. Dedic, K. Nieman, M. De Graaf, M. Meijs, Standardized evaluation framework for evaluating coronary artery stenosis detection, stenosis quantification and lumen segmentation algorithms in computed tomography angiography, Medical image analysis 17, 859-876, 2013.

[133] R. Goldenberg, D. Eilot, G. Begelman, E. Walach, E. Ben-Ishai, N. Peled, Computer-aided simple triage (CAST) for coronary CT angiography (CCTA), International journal of computer assisted radiology and surgery 7, 819-827, 2012.

[134] İ. Öksüz, D. Ünay, K. Kadıpaşaoğlu, A Hybrid Method for Coronary Artery Stenoses Detection and Quantification in CTA Images, Proc. MICCAI Workshop 3D Cardiovascular Imaging: A MICCAI Segmentation, 2012.

[135] G. Yang, P. Kitslaar, M. Frenay, A. Broersen, M.J. Boogers, J.J. Bax, J.H. Reiber, J. Dijkstra, Automatic centerline extraction of coronary arteries in coronary computed tomographic angiography, The international journal of cardiovascular imaging 28, 921-933, 2012.

[136] G. Yang, A. Broersen, R. Petr, P. Kitslaar, M.A. de Graaf, J.J. Bax, J. Reiber, J. Dijkstra, Automatic coronary artery tree labeling in coronary computed tomographic angiography datasets, IEEE Computing in Cardiology, 109-112, 2011.

[137] A. Myronenko, X. Song, Point set registration: Coherent point drift, IEEE Transactions on Pattern Analysis and Machine Intelligence , 32,, 2262-2275, 2010.

[138] S. Gu, R. Gupta, I. Kyprianou, Computational high-resolution heart phantoms for medical imaging and dosimetry simulations, Physics in medicine and biology 56, 5845, 2011.

[139] O.C. Avila-Montes, U. Kurkure, R. Nakazato, D.S. Berman, D. Dey, I.A. Kakadiaris, Segmentation of the Thoracic Aorta in Noncontrast Cardiac CT Images, IEEE Journal of Biomedical and Health Informatics, 17, 936-949, 2013.

[140] B. Bouraoui, C. Ronse, J. Baruthio, N. Passat, P. Germain,, 3D segmentation of coronary arteries based on advanced mathematical morphology techniques, Computerized medical imaging and graphics, 34, 377-387, 2010.

[141] G. Yang, A. Broersen, R. Petr, P. Kitslaar, M.A. de Graaf, J.J. Bax, J. Reiber, J. Dijkstra, Automatic coronary artery tree labeling in coronary computed tomographic angiography datasets, IEEE Computing in Cardiology, 109-112, 2011.

[142] A. Myronenko, X. Song, Point set registration: Coherent point drift, IEEE Transactions on Pattern Analysis and Machine Intelligence, 32, 2262-2275, 2010.

[143] F.C. Monteiro, A.C. Campilho, Performance evaluation of image segmentation, Image Analysis and Recognition, Springer, pp. 248-259, 2006.

[144] G.-A. Turgeon, G. Lehmann, G. Guiraudon, M. Drangova, D. Holdsworth, T. Peters, 2D-3D registration of coronary angiograms for cardiac procedure planning and guidance, Medical physics, 32, 3737-3749, 2005.

[145] D. Ruijters, B.M. ter Haar Romeny, P. Suetens, Vesselness-based 2D–3D registration of the coronary arteries, International journal of computer assisted radiology and surgery 4, 391-397, 2009.

[146] C.T. Metz, M. Schaap, S. Klein, N. Baka, L.A. Neefjes, J. Schultz, W.J. Niessen, T. van Walsum, Registration of coronary CTA and monoplane X-ray angiography, IEEE Transactions on Medical Imaging, 32, 919-931, 2013.

[147] H. Imamura, N. Ida, N. Sugimoto, S. Eiho, S.-i. Urayama, K. Ueno, K. Inoue, Registration of preoperative CTA and intraoperative fluoroscopic images for assisting aortic stent grafting, Medical Image Computing and Computer-Assisted Intervention—MICCAI 2002, Springer, 477-484, 2002.

[148] X. Chen, R.C. Gilkeson, B. Fei, , Automatic 3D-to-2D registration for CT and dual-energy digital radiography for calcification detection, Medical physics, 34, 4934-4943, 2007.

[149] C. Gatta, S. Balocco, V. Martin-Yuste, R. Leta, P. Radeva, Non-rigid multi-modal registration of coronary arteries using SIFT flow, Pattern Recognition and Image Analysis, Springer, 159-166, 2011.

[150] E. Serradell, A. Romero, R. Leta, C. Gatta, F. Moreno-Noguer, Simultaneous correspondence and non-rigid 3D reconstruction of the coronary tree from single X-ray images, IEEE International Conference onComputer Vision (ICCV), 850-857, 2011.

[151] C. Zhang, S. Du, J. Liu, J. Xue, Robust 3D Point Set Registration Using Iterative Closest Point Algorithm with Bounded Rotation Angle, Signal Processing, 2015.

[152] R. Hartley, A. Zisserman, Multiple view geometry in computer vision, Cambridge university press, 2003.