

CASE REPORT

Altered Vision in MSM Patient, Diagnosis of Ocular Syphilis in Primary Care: A Case Report

Hanifatiyah Ali¹, Dr Mohd Fairuz Ali², Dr Nor Azita Ahmad Tarmidzi³, Dr Raja Nor Farahiyah Raja Othman⁴

¹ Department of Family Medicine, Faculty of Medicine and Health Science, Universiti Putra Malaysia, 43400 Serdang, Selangor, Malaysia

² Department of Family Medicine, Faculty of Medicine, Universiti Kebangsaan Malaysia Medical Centre, 56000 Kuala Lumpur, Malaysia

³ Department of Ophthalmology, Hospital Kuala Lumpur, Jalan Pahang 50586 Wilayah Persekutuan Kuala Lumpur

⁴ Department of Ophthalmology, Faculty of Medicine, Universiti Kebangsaan Malaysia Medical Centre, 56000 Kuala Lumpur, Malaysia

ABSTRACT

There is a concern in the emergent of sexually transmitted diseases and its complication with the increase in the prevalence of men who have sex with men (MSM). Ocular syphilis is one of the conditions that is associated with high-risk patients especially in patients already infected with human immunodeficiency virus (HIV). This case reports an MSM patient who was diagnosed with concurrent HIV and ocular syphilis infections. The report focuses on the clinical presentation of ocular syphilis in HIV infected patients and its management in primary care.

Keywords: Syphilis, tertiary; uveitis; Homosexuals, HIV

Corresponding Author:

Hanifatiyah Ali, MMed (FamMed)

Email : fatiyah@upm.edu.my

Tel : +603 – 89472538

INTRODUCTION

In the year 2013, WHO has classified Malaysia as having a concentrated HIV epidemic. A Malaysian survey completed in 2012 found that males constituted 90% of PLHIV, and the percentage of MSM living with HIV was reported at 12.6% (1). This number is worrying as other sexually transmitted infections (STI) such as syphilis may also become more prevalent among MSM.

CASE REPORT

A 38-year-old man presented with a one-month history of bilateral reduced vision which progressively worsened for the past two days prior to presentation. It was associated with bilateral intermittent floaters and eyes redness. He denied any eye pain, discharge, or photophobia. He also complaint of loss of appetite and loss of weight for few months. Otherwise, he has no associated symptoms such as dizziness, headache or fever. Despite having the symptoms, he did not seek any medical treatment initially.

He was referred to Ophthalmology Department in

Hospital Kuala Lumpur for further management. On further history, he works as a car mechanic. He was a single however having multiple sexual partners only with men. He was unsure of the infective status of his partners. He denied any drug or alcohol abused. There was no history of oral or genital ulcer or skin rashes previously. He had history of recent travelling but no history of recent swimming in the river/pool. He had no symptoms of chronic cough, night sweat or tuberculosis contact. He never rears cats and no history of being scratched by cats. There were no autoimmune symptoms such as alopecia, myalgia, and arthralgia. This was his first episode of ocular problem. None of his family members had similar problem as him.

On assessment, the vital signs were within normal range and he was afebrile. Skin examination was unremarkable, no maculopapular rashes especially at palm or soles. No mouth ulcer seen. Eye examination revealed the visual acuity of his right eye was 6/60 not improved with pinhole and left eye was 6/9. Both pupils were 3 mm, equally round, symmetry and reactive to light. There is no relative afferent pupil defect (RAPD). Bilateral conjunctiva mildly injected with evidence of moderate anterior segment inflammation. The intraocular pressure of both eyes were normal. Fundus examination revealed right eye hazy view due to vitritis, foci area of retinitis superiorly with normal optic disc (Figure 1). Left eye showed minimal vitritis with swollen

optic disc, otherwise no obvious retinitis seen (Figure 2). Macula looked fairly normal in both eyes.

Several investigations were done. Blood test revealed VDRL positive with a titre of 1:512. Subsequently patient was admitted for commencement of intravenous (IV) C-Penicillin 4 mIU four hourly for two weeks and topical corticosteroid two hourly for both eyes. He was also newly diagnosed HIV positive with CD4 count 360 cell/mm³. Other infective screening was negative. He was co-managed with Neuromedical and Infectious Disease Team. CT brain was done and showed normal findings. Lumbar puncture showed CSF VDRL negative.

He was discharged home after completing IV antibiotics. His bilateral vision improved to 6/6 after 2 months. The right eye fundus clearer and the left eye swollen disc had improved (Figure 3 & 4). He was referred back to the community outpatient health clinic to start on anti-retroviral therapy (ART) and other management for the RVD. The patient was started on ART which consists of Tenofovir-Emtricitabine (Tenvir-Em), and Efavirenz 600 mg daily in which he had no complaint of any adverse effect. The VDRL titre was repeated two months later and it was markedly reduced to 1:64.

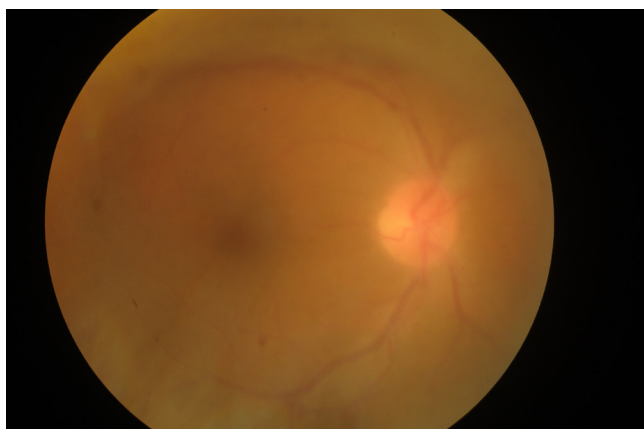


Figure 1: Right eye hazy fundus view due to vitritis. Area of retinitis superiorly (Initial presentation)

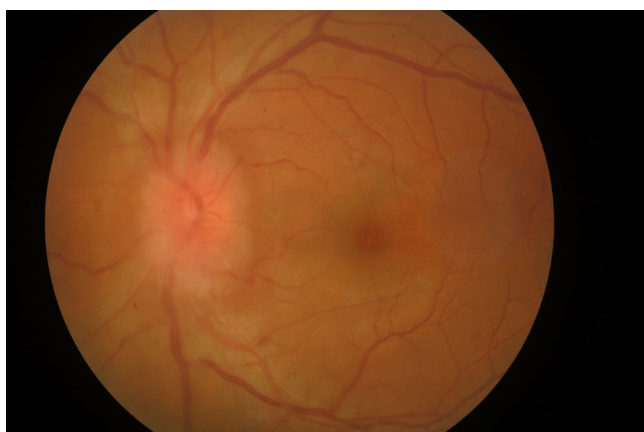


Figure 2: Left eye showed swollen optic disc (Initial presentation)

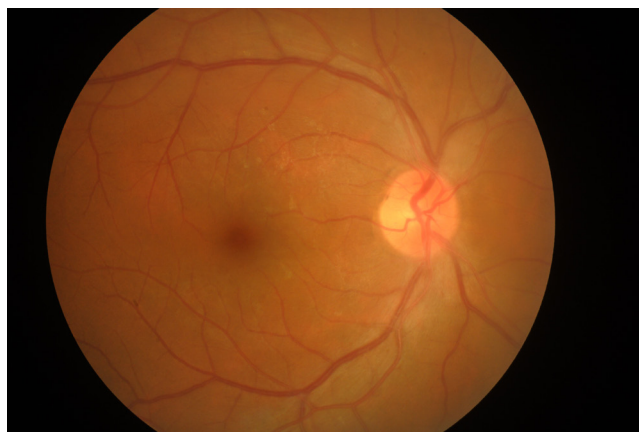

Figure 3 : Right eye fundus clearer (After completed treatment)

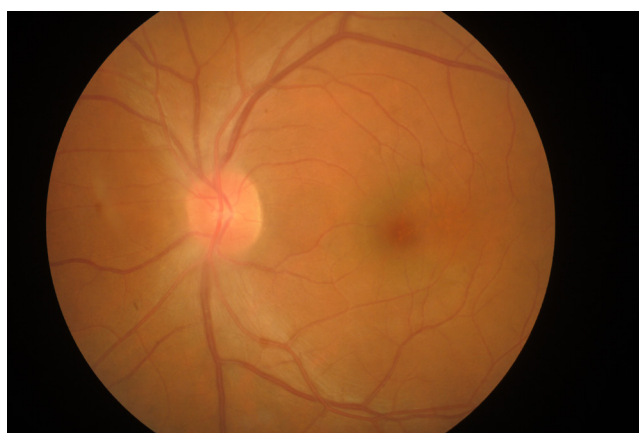

Figure 4 : Left eye disc swollen resolved (After completed treatment)

DISCUSSION

Syphilis is caused by spirochaete *Treponema pallidum*. It is usually transmitted by sexual contact or transplacental. Acquired syphilis is divided into primary, secondary, latent and tertiary stages. Local data on the prevalence of ocular syphilis among HIV-infected patients was not available, however in an HIV clinic in the U.S, the prevalence of ocular involvement in patients diagnosed with syphilis was around 9% (2).

Syphilis presents similarly in both HIV-infected or non-HIV-infected patients. However, in primary syphilis, HIV-infected patients may present with multiple chancre and with larger and deeper lesions (3). Although atypical and aggressive presentations of syphilis occur more frequently among HIV-infected patients, these represent a very small minority of the cases (3). Previous study had showed that early neurologic involvement is found more frequently in HIV-infected patients (3). Ocular syphilis is a form of neurosyphilis. If untreated, risk of cerebral involvement may lead to severe morbidity and mortality.

In this patient who presented with gradual painless blurring of vision associated with eye redness for a month should entertain uveitis as one of the provisional diagnosis. Uveitis is inflammation of uveal tissue. It can be due to infection and non-infection. Other differential diagnosis of blurring of vision with red eye are corneal ulcer, acute angle closure glaucoma, scleritis, orbital cellulitis, lens-related problem such as phacomorphic, and trauma which are usually painful and acute in clinical presentation.

Uveitis is the most common ocular manifestation of secondary and tertiary syphilis. Symptoms of uveitis are eye redness, blurred vision, photophobia, and floaters. Syphilis may affect all structures of the eyes both in immunosuppression or immunocompetent. Syphilis can cause conjunctivitis, episcleritis, scleritis, intermediate uveitis, and miscellaneous neuro-ophthalmic features related to CNS involvement including Argyll Robertson pupils. For retina, syphilis can cause occlusive retinal vasculitis, chorioretinitis, neuroretinitis. Unfortunately, this examination needs an ophthalmologist.

The health care practitioners should have high index of suspicion of sexually transmitted disease in a young patient with high risk behaviour. History taking should include symptoms like oral ulcer, genital ulcer, and skin rashes. Once patient has confirmed to have sexual transmitted disease, contact tracing need to be done. Other causes of infective uveitis are tuberculosis, toxoplasmosis and leptospirosis. Investigations need to be tailored accordingly. Non-infective cause of uveitis can be autoimmune disease related.

As for the eye examination, visual acuity and relative afferent pupillary defect (RAPD) can be done at a primary care level as a baseline to assess optic nerve function. In addition, pupil examination also can give a clue, anisocoria may suggest Argyll Robertson/Adies pupil as both can manifest in syphilis. Funduscopy examination is important to look for involvement of posterior segment. In the presence of uveitis, it can be very challenging and requires ophthalmologist assessment.

The role of topical corticosteroid in the treatment of ocular syphilis is to reduce ocular inflammation but must be given with the antibiotics. The mainstay of the treatment is still IV C-Penicillin (Aqueous penicillin G 3–4 million units IV every 4 hours for 10–14 days). To date there is no documented penicillin resistance in treating *T. pallidum* infection (4). Topical steroid will be tapered down slowly according to inflammatory activity.

Patients with concurrent syphilis and HIV usually will be seen at three months after penicillin administration to monitor response and subsequently every 6 months for two years. VDRL titres should be taken regularly, with the goal of a four-fold decrease after one year. In RVD patient, the desired VDRL reduction may take

longer than normal with a high risk of treatment failure if only based on the serological monitoring (5). Thus, it is important to assess both the clinical and serological response when making treatment decisions.

Testing for syphilis should occur yearly but may need to be more frequent in those with ongoing risky behaviour. Alcohol and recreational drug use are other behaviours associated with risky sexual practices and also warrant patient education and monitoring. MSM patients should also be vaccinated against hepatitis A, hepatitis B, and HPV, as these diseases complicate the existing infection and increase morbidity.

Management also needs to include non-pharmacologic treatment. Physicians need to have continues counselling against risky sexual practices. This is vital in high-risk patients, especially in MSM. Managing MSM patients requires an open, non-judgmental approach from health care workers in order to encourage patient communication and adherence to the recommended treatment. Reserving extra clinic times specifically for MSM and providing educational materials on same-sex issues can be helpful. Other than that, contact tracing is also important. Persons exposed sexually to a person who has any stages of syphilis should be evaluated clinically and serologically and treated accordingly. This helps limit the spread of disease in the community.

CONCLUSION

MSM are prone to having a higher risk of specific diseases related to their sexual practices and preferences. Physicians should be attentive when MSM present with non-specific medical complaints in the primary care setting, as a failure to detect certain conditions early enough may result in detrimental outcomes. Therefore, a perceptive approach to patients' sensitivity is a must, without jeopardising sound clinical judgment in dealing with this high-risk group.

ACKNOWLEDGEMENTS

The authors wish to thank Dr. Mohd Radzniwan Rashid, lecturer of University Sains Islam Malaysia who provided mentorship in the development of the case report. Besides we would also like to thank Dr. Kenneth Teow Kheng Leong and Dr. Ahmad Syazrin Abdullah bin Azlan, Ophthalmology Masters Trainee in Hospital Kuala Lumpur. The authors would also like to thank Suanne Garrity, MPT, who provided medical and English language writing and editing services.

REFERENCES

1. Ngadiman S. THE NATIONAL STRATEGIC PLAN ON HIV / AIDS 2011 - 2015. 2013.
2. Balba GP, Kumar PN, James AN, Malani A,

- Palestine AG, Welch JN, et al. Ocular Syphilis in HIV-Positive Patients Receiving Highly Active Antiretroviral Therapy. *Am J Med*. 2006;119(5):0–4.
3. Schüfer H, Imhof M, Thoma-Greber E, Brockmeyer NH, Hartmann M, Gerken G, et al. Active syphilis in HIV infection: a multicentre retrospective survey. The German AIDS Study Group (GASG). *Genitourin Med* [Internet]. 1996 Jun [cited 2018 Jul 16];72(3):176–81.
 4. Douglas JM. Penicillin Treatment of Syphilis. *JAMA* [Internet]. 2009 Feb 18 [cited 2018 Jun 12];301(7):769.
 5. Ormerod LD, Puklin JE, Sobel JD. Syphilitic Posterior Uveitis: Correlative Findings and Significance. *Clin Infect Dis* [Internet]. 2001 Jun 15 [cited 2018 Jul 16];32(12):1661–73.