

CASE REPORT

Challenges in the Management of a Child with Yolk Sac Tumour of the Nasal Cavity Presenting with Epistaxis and Progressive Respiratory Distress

Mohd Nor Khadijah^{1,2}, Michelle Manuel Anura¹, Chew Man Fong³, Gan Chin Seng⁴, Tsiao Yi Yap⁴, Loong Siow Ping¹, Abdullah Wan Ariffin⁴

1 Department of Otorhinolaryngology (Head and Neck), University Malaya Medical Centre, Pantai Valley, 59100 Kuala Lumpur, Malaysia

2 Department of Surgery, Faculty of Medicine and Health Sciences, Universiti Putra Malaysia, 43400 Serdang, Selangor, Malaysia

3 Department of Pathology, University Malaya Medical Centre, Pantai Valley, 59100 Kuala Lumpur, Malaysia

4 Department of Paediatrics, University Malaya Medical Centre, Pantai Valley, 59100 Kuala Lumpur, Malaysia

ABSTRACT

Yolk Sac tumour (YST) of the nasal cavity is extremely rare with only less than five previously reported cases in the English literature. Due to its rarity, the diagnosis is not one that is considered at initial presentation until tissue biopsies are sent for histopathological examination. Serum α -fetoprotein levels aid in diagnosis and in monitoring progression of the tumour. Being a very uncommon tumour of germ cell origin presenting as localized disease in the nasal cavity, prognosis and survival rates are difficult to determine. We are reporting a rare yolk sac tumour case in an infant and the challenges encountered in its management.

Keywords: Sinonasal tumour, Yolk sac tumour, Serum α -fetoprotein

Corresponding Author:

Dr. Khadijah Mohd Nor

Tel: +6038947 2360 / +60123345906

Fax: +6038945 5217

E-mail: khadijahmnor@upm.edu.my

serum α -fetoprotein(AFP). Management for gonadal and extragonadal primary sites has been well studied with overall favourable outcome (1). However, treatment approaches and outcomes of head and neck YST varies which given the rarity of the disease.

INTRODUCTION

Yolk sac tumours (YST) are malignant neoplasms of embryonic origin, germ cells which derived the precursors of gametes (1). Of the germ cell tumours, teratomas are more common, while YST are rare. It normally originates from the gonads, which primordial germ cells migrate from the yolk sac to the genital ridge, usually in the infant testes and ovaries. YST are also known as endodermal sinus tumours, the features are similar with endodermic sinuses of the placenta. About 20% of cases are found in extra-gonadal site of origin (2). Extragonadal regions in order of frequency are the sacrococcygeal region, retroperitoneal region, central nervous system and mediastinum. About 5% of all types of germ cell tumours develop in the head and neck region, with only approximately 1% being malignant (3).

The diagnosis is strongly dependent on the histopathologic features, specifically Schiller-Duval bodies and raised

CASE PRESENTATION

A 1-year-old girl was presented with history of unilateral mucoid nasal discharge for one-week duration, associated with occasional nose bleed from the same side of the nose. On oral cavity and oropharyngeal examination, the soft palate was pushed down, and the child was breathing through the mouth.

Nasoendoscopic examination under general-anaesthesia revealed a firm, fleshy mass completely obstructing the left nasal-cavity and occupying most of the post-nasal space (Fig. 1). It bled easily with manipulation. The right nasal cavity was obliterated by a deviated nasal septum; the latter being pushed by the mass from the left nasal cavity. The child was intubated on the 2nd day of admission due to progressive upper airway obstruction from the aggressive nature of the tumour. CAT-scan showed a soft tissue density mass

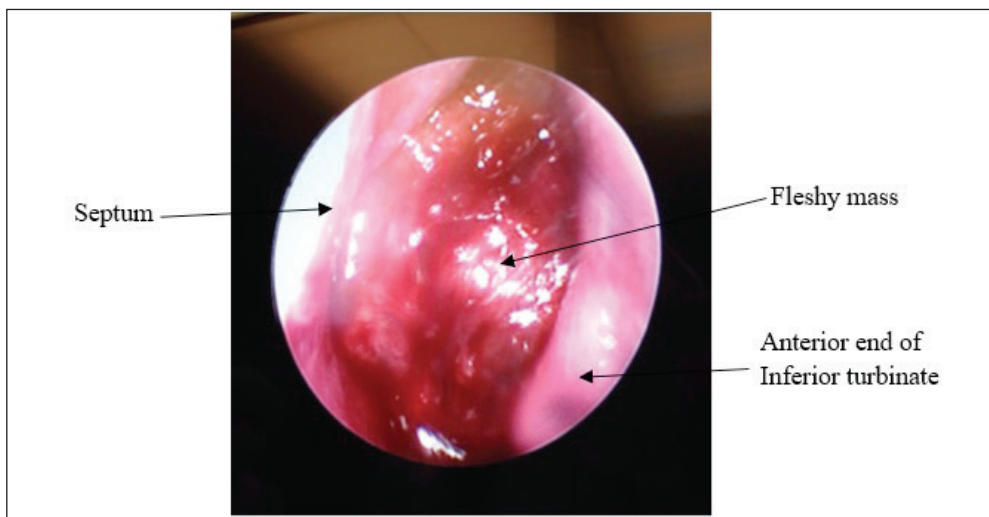


Fig. 1 Left nasal cavity mass.

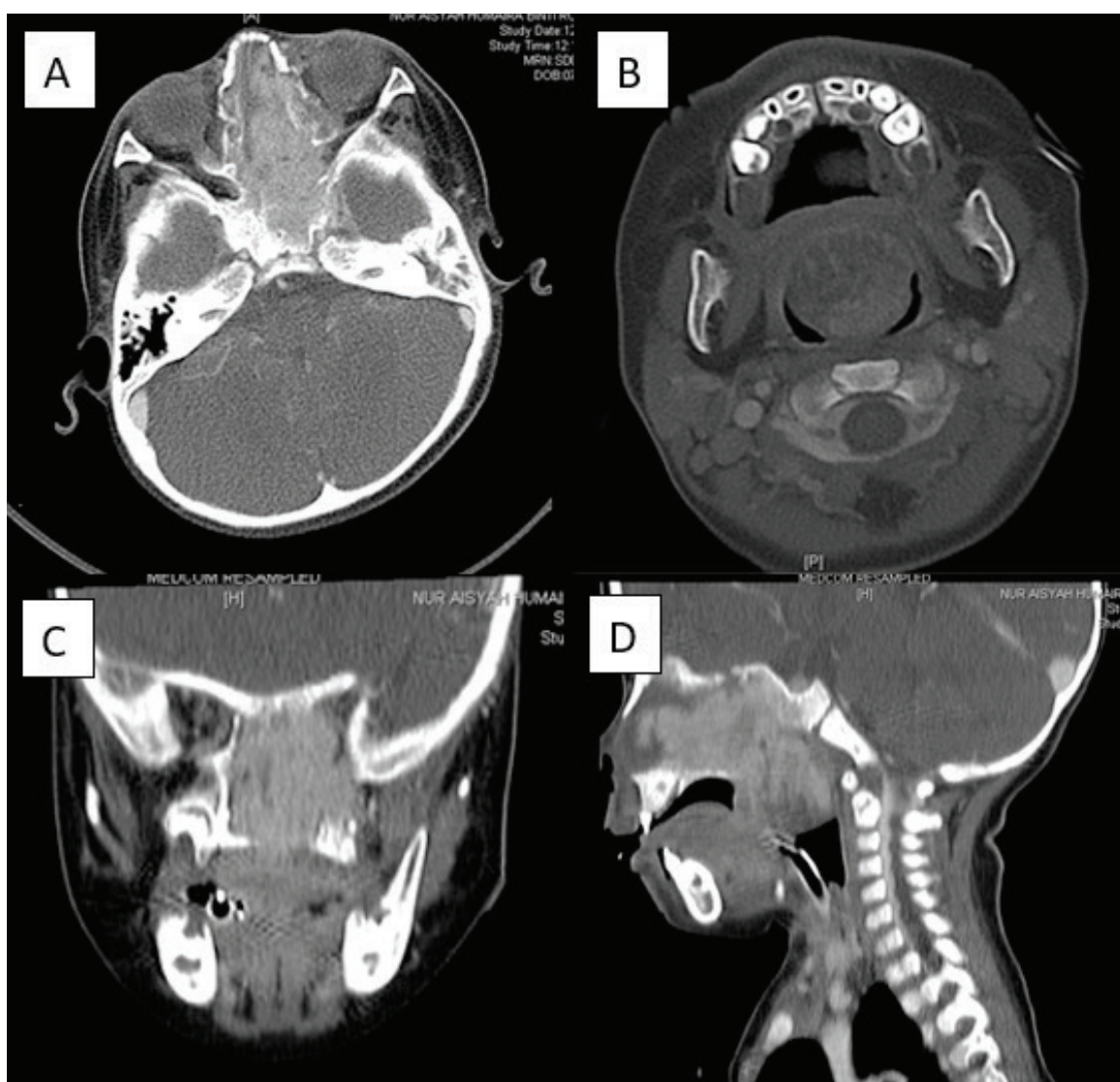


Fig. 2 CT films of paranasal sinus, (A) a mass obliterating the left nasal cavity extending laterally into the medial extraconal space of the left orbit, eroding the left lamina papyracea and anteriorly into the left ethmoidal sinus and (B) Posteroinferiorly into the oropharynx. (C&D) Superiorly, erosion of the left basi-sphenoid, dorsum sella and cribriform plate.

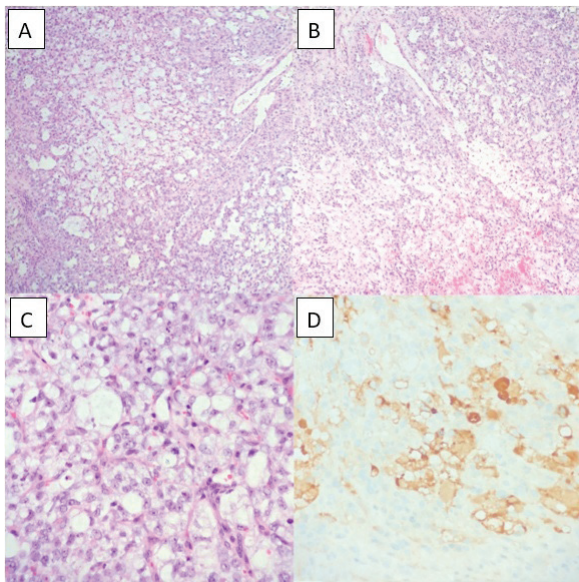


Fig. 3 Histopathology photomicrographs. (A&B) Low magnification view-Reticular (microcystic and macrocystic) pattern. (C&D) High magnification view-Prominent vascularity and myxoid matrix. Tumour cells with vesicular nuclei, pleomorphism is mild to at most moderate. (D) Positive immunoperoxidase with AFP.

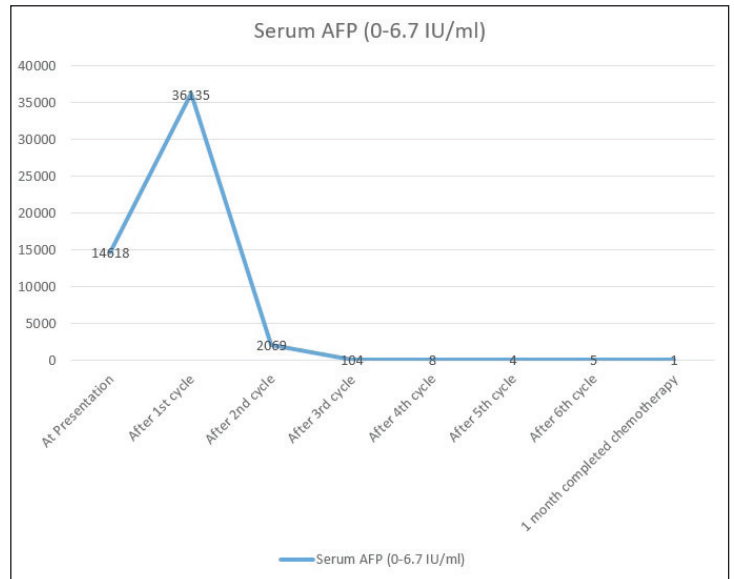


Fig. 4 Line chart showing the changes in serum AFP levels (in IU/ml) decreased over the course of treatment and became normal after 3rd cycle of chemotherapy

that obliterate the left nasal cavity extending superiorly with erosion of left basisphenoid, dorsum-sella and cribriform-plate; anteriorly into the left ethmoidal sinus and posteroinferiorly into the oropharyngeal space. The mass also extended laterally into the medial extraconal space of the left orbit, eroding the left lamina-papyracea (Fig. 2). The left extra-ocular muscles, intraconal space, hard palate, clivus and hypopharynx were spared. There was no distant metastasis. At this stage, the differentials diagnoses included rhabdomyosarcoma, haemangiopericytoma and lymphoma.

Magnetic-resonance-imaging (MRI) showed intracranial extradural tumour extension through the cribriform plate and opacification of the maxillary and frontal sinuses. Features were keeping with parameningeal rhabdomyosarcoma with its epicenter in the nasal cavity. There was no significant cervical adenopathy.

Biopsy was done under general-anaesthesia ensuring that adequate samples were taken. Significant bleed from the tumour was arrested by nasal packing. Pathologic diagnosis was initially challenging. There was a prominent myxoid background and high vascularity, with mild to moderately pleomorphic cuboidal cells interspersed in a complex reticular pattern of predominantly microcysts and focal macrocysts. Small foci of solid nests of small to medium sized malignant cells with amphophilic cytoplasm were seen treatment (Fig. 3). Labyrinthine endodermal sinus patterns, papillae or characteristic Schiller-Duval bodies were not

detected. The differential diagnosis at this point was that of a YST or chordoma.

Positive α -fetoprotein (AFP) immunoperoxidase in the histopathology tissue section as well as marked elevation of AFP in a concurrent blood sample confirmed the diagnosis of Yolk Sac Tumour.

The patient received 6 courses of combination chemotherapy with Etoposide (120mg/m² on days1-3), Carboplatin (600mg/m² on day2) and Bleomycin(15mg/m² on day3) every 3weeks. The AFP levels decreased over the course of treatment and became normal after 3months of treatment (Fig. 4).

After commencement of chemotherapy, tumour size reduced rapidly and the patient was extubated successfully within one week of treatment.

A CT scan done 4weeks after completed treatment, showed complete regression of tumour mass. Repeated biopsy, was negative for malignancy. The patient currently remains disease free at 1year follow up post-chemotherapy.

DISCUSSION

YST occurs in the gonads due to the presence of germ cells in the testes and ovaries. The challenging part are, to explain how the primitive yolk sac cells migrate to

the nasal cavity and the presence of germ cells in extra-gonadal sites which still unknown. Some theories that can explain the presence of this sinonasal tumour, are detachment of germ cells during migration of the vitelline sac to the gonadal crest during embryogenesis, and subsequent malignant transformation, the theory of pluripotential cells that escape from the influence of primary development, the theory that the tumour has a genetic origin arising through somatic cells or germ cell mitoses and the theory of presence of germ cells in all tissues (2).

YST are malignant germ cell tumours and simulate the yolk sac, at same time secrete AFP. The serum AFP concentration correlates with the response of the neoplasm to treatment and is directly comparable with prognosis. Therefore, reduction of the serum AFP level correlates with response of the disease to the therapy.

Reported few sites of origin in the head and neck region including the orbit, maxillary sinus, temporomandibular region, ear, retroauricular region, nasopharynx, oral-cavity, parotid gland and submandibular gland (3).

Sinonasal YST are like other nasal tumours in children, they may present with nonspecific symptoms. YST of the nasal cavity is uncommon, and is usually not considered in the differential diagnosis of a sinonasal mass in a young age group. More common differentials include rhabdomyosarcoma, lymphoma, meningocele, chondroma, meningioma and other soft tissue sarcomas.

Head and neck YST are more common presentation in children, and are generally non-resectable at diagnosis. Some studies conclude that patients with these tumours have a relatively poorer prognosis in comparing to those with primary gonadal tumours (4). In view of its rarity, the treatment protocol has not yet been established. Even though poor prognosis, an advances in chemotherapeutic drugs and diagnostic methods have improved survival rates (3). Most authors advocate, surgical excision followed by adjuvant chemotherapy, is recommended. Meanwhile, combination chemotherapy has also given satisfactory outcome in gonadal YST. Postoperative adjuvant radiotherapy may also give benefit for tumours in head and neck. Bernardo et.al reported a sinonasal YST's patient underwent postoperative radiotherapy resulted in disease free survival of 7 years (3). Issue of radical surgery and combined modality treatment in small and young patients with malignant disease of potentially poor prognosis can be complex. The complication risk, quality of life, functional outcome and the possibility of controlling the disease must be considered in treatment planning.

Chemotherapeutic regimens including cisplatin, etoposide and bleomycin have given satisfactory results (3). In this case, chemotherapy was administered. She underwent combination chemotherapy with carboplatin, etoposide and bleomycin. The patient was extubated uneventfully after the first cycle of chemotherapy due to the rapid shrinkage of tumour.

Following 6 cycles of chemotherapy, there was a marked decrease in size and normalization of AFP levels. Imaging performed at the end of treatment demonstrated significant new bone formation which was negative for malignancy.

YST are malignant tumours which tends to have local recurrence, and surprisingly it may present with early metastases in 50% of cases (3). Metastases to lungs, lymph nodes, liver and bones have all been discussed by Devaney et.al (2). Lungs is the main target organ for metastases.

CONCLUSION

YST of the sinonasal tract are extremely rare malignant tumours. Its diagnosis is based on histopathologic findings and elevated AFP. Histopathological diagnosis can be challenging especially in those with a glandular morphology. Accurate diagnosis dictates efficacy of treatment. Maintaining an adequate airway is of paramount importance in cases where the tumour causes upper airway obstruction. Combined modality of treatment with radical surgery, adjuvant chemotherapy and/or radiotherapy seem to be the mainstay of treatment. Despite poor prognosis, developments in chemotherapeutic drugs and diagnostic methods have improved survival rate of patients.

REFERENCES

1. Hauser LJ, Chiang T, Ramakrishnan VR, Lovell MA, Kelley PE. Parapharyngeal and skull base yolk sac tumor: A case report with lessons in diagnosis and management. *Int J Pediatr Otorhinolaryngol.* 2014;78(11):2003-6.
2. Devaney KO, Ferlito A. Yolk sac tumors (endodermal sinus tumors) of the extracranial head and neck regions. *Ann Otol Rhinol Laryngol.* 1997;106(3):254-60.
3. Araujo Filho BC, McHugh JB, Carrau RL, Kassam AB. Yolk sac tumor in the nasal cavity. *Am J Otolaryngol.* 2008;29(4):250-4.
4. Kusumakumari P, Geetha N, Chellam VG, Nair MK. Endodermal sinus tumors in the head and neck region. *Pediatr Blood Cancer.* 1997;29(4):303-7.