



Review Article

High-frequency Ultrasound Imaging in Wound Assessment: Current Perspectives

Hamidreza Mohafez^{1*}, Siti Anom Ahmad^{1,4}, Maryam Hadizadeh^{3,5},
Mohammad Hamiruce Marhaban¹ and Mohammad Iqbal Saripan²

¹Department of Electrical and Electronic Engineering, Faculty of Engineering, Universiti Putra Malaysia, 43400 UPM, Serdang, Selangor, Malaysia

²Department of Computer and Communication Systems Engineering, Faculty of Engineering, Universiti Putra Malaysia, 43400 UPM, Serdang, Selangor, Malaysia

³Sports Centre, University of Malaya, 50603 UM, Kuala Lumpur, Malaysia

⁴Malaysian Research Institute of Ageing, Universiti Putra Malaysia, 43400 UPM, Serdang, Selangor, Malaysia

⁵Sama Technical and Vocational Training College Tehran Branch, Islamic Azad University, Tehran, Iran

ABSTRACT

Non-invasive imaging modalities for wound assessment have become increasingly popular over the past two decades. The wounds can be developed superficially or from within deep tissues, depending on the nature of the dominant risk factors. Developing a reproducible quantitative method to assess wound-healing status has demonstrated to be a convoluted task. Advances in High-Frequency Ultrasound (HFU) skin scanners have expanded their application as they are cost-effective and reproducible diagnostic tools in dermatology, including for the measurement of skin thickness, the assessment of skin tumours, the estimation of the volume of melanoma and non-melanoma skin cancers, the visualisation of skin structure and the monitoring of the healing of acute and chronic wounds. Previous studies have revealed that HFU images carry dominant parameters and depict the phenomena occurring within deep tissue layers during the wound-healing process. However, the investigations have mostly focussed on the validation of HFU images, and few studies have utilised HFU imaging in quantitative assessment of wound generation and

healing. This paper is an introductory review of the important studies proposed by the researchers in the context of wound assessment. The principles of dermasonography are briefly explained, followed by a review of the relevant literature that investigated the wound-healing process and tissue structures within the wound using HFU imaging.

Keywords: Wound assessment, High-frequency ultrasound, Dermatologic sonography, Wound healing

ARTICLE INFO

Article history:

Received: 08 June 2016

Accepted: 28 May 2017

E-mail addresses:

hamidrezamohafez@gmail.com (Hamidreza Mohafez),

sanom@upm.edu.my (Siti Anom Ahmad),

m.hadizadeh.sport@gmail.com (Maryam Hadizadeh),

mhm@upm.edu.my (Mohammad Hamiruce Marhaban),

iqbal@upm.edu.my (Mohammad Iqbal Saripan)

*Corresponding Author

INTRODUCTION

Wound assessment is complex and multi-faceted, comprising wound aetiology, wound appearance, identification of factors delaying healing, monitoring and prediction of healing rates and wound documentation (Shaw & Bell, 2011). The gold standard is wound biopsy, which provides valuable superficial and in-depth information about the cost of the increment in the wound area and the impairment in the healing process. Regular monitoring of healing helps clinicians to evaluate the effectiveness of a particular treatment strategy and change it if necessary, and to distinguish between healing and non-healing wounds (Dyson et al., 2003).

In clinical arena, assessment methods have been mainly based on the measurement of two valuable wound characteristics, physical dimension and colour (Plassmann & Jones, 1998; Treuillet et al., 2009). The early methods used a ruler, acetate sheet and alginate casts to measure the wound area and volume. Nevertheless, the problem of direct contact with the wound along with poor precision due to subjectivity in measurement and inaccurate employed tools, made these earlier methods less reliable (Plassmann, 1995). Numerous simple and complicated non-contact methods such as standardised digital photography, structured light analysis (MAVIS) and stereo-photogrammetry were proposed to improve the measurement error rate to 10-12%, 3-5% and 0-3%, respectively, to prevent wound contamination and to reduce patient discomfort (Humbert et al., 2004). However, they are costly and require a trained operator, making them impractical in clinical applications.

Wound colorimetry considers ulcer colour characteristics as a function of its clinical stage. This method is based on the Red-Yellow-Black model, which is more a measure of the clinicians' effectiveness in cleaning up a wound than of the healing progress (Plassmann & Belem, 2009). Significant advances in the field of image analysis make standardised digital photography the most popular tool for assessing healing, which considers both aspects of the wound i.e. colour and size. However, it only provides surface-level information that cannot show the full extent of underlying tissue damage, wound severity and etiology (Dyson et al., 2003; Moghimi et al., 2011). This issue becomes more significant when dealing with diabetic foot ulcers (DFUs), which are notably different from acute wounds in that they can develop superficially or from within the deep tissue, depending on the nature of dominant risk factors (Moghimi et al., 2010). More specifically, wound healing, especially in chronic wounds such as DFUs, tends to be slow, and may lead to reactive treatment if the assessment is based purely on dimensional changes (Jones & Plassmann, 2000).

Therefore, advanced imaging modalities, such as computerised tomography (CT), magnetic resonance imaging (MRI) and high-frequency ultrasound (HFU) imaging (> 20MHz), have been employed to reveal the healing progress and wound status of underlying tissues. Of the three aforementioned modalities, CT and MRI are not economical for utilisation in clinics and have drawbacks, such as patient exposure to X-rays, magnetic fields and injected dyes (Wendelken et al., 2003). Improvements in ultrasound instrumentation and advances in portable HFU skin scanners have expanded their application to microscopic imaging in dermatology, which enables us to visualise skin structure from the epidermis up to deep fascia and to monitor dimensional changes deep within the tissues in a non-invasive manner, but still it needs a highly trained operator for data acquisition and interpretation (Dyson et al., 2003; Moghimi et al.,

2011; Rippon et al., 1998). This paper briefly explains the principles of ultrasound imaging; considers and interprets 2D B-mode HFU images of healthy and wounded skin; reviews related studies that have investigated the application of dermasonography in wound assessment; and enumerates HFU imaging limitations.

PRINCIPLES OF ULTRASOUND IMAGING

The ultrasound beams undergo three major phenomena including reflection, refraction and attenuation during travelling through skin tissues. Even so, the ultrasonic image formation relies on the reflected waves from the tissues mostly at the interfaces between regions like the echogenic dermis and hypo-echoic sub-cutis (Figure 1). Inherent variations in skin tissue structure, especially density and vascularity, which are reflected as differences in collagen, keratin and water content, lead to the presence of different echogenicity areas in the ultrasound image (Kleinerman et al., 2012). Ultrasound measurement consists of the transformation of sound beams into visual image that can be exhibited in different modes. One of those is the brightness mode (B-mode), which is a two-dimensional presentation of scanned structures, mostly used in dermatology. It is generated through the conversion of reflected waves into grey-scale values and shows a cross-sectional image of examined tissue.

In general, the resolution of 2D ultrasound B-mode images improves as the probe frequency increases with the cost of diminishing depth of penetration. Given that fact, a low-frequency probe is normally used to visualise deeper and larger organs, while the superficial skin layers (e.g. epidermis and dermis) need to be scanned at higher frequencies. The two key parameters of an ultrasound probe are axial resolution, referring to the ability of distinguishing two adjacent objects lying parallel to the beam direction, and lateral resolution, the ability to distinguish two points lying perpendicular to the ultrasound beam direction.

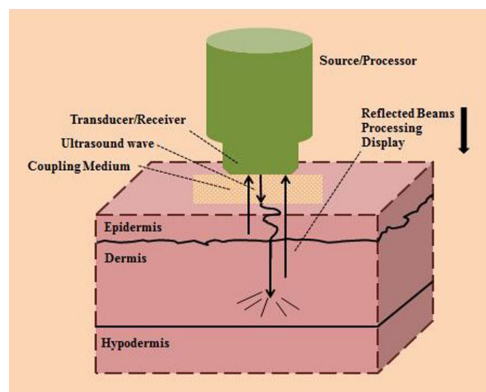


Figure 1. Schematic of Dermasonography Device, including source, transducer, coupling medium and high-frequency wave projected into the skin. The ultrasound wave is reflected back to the transducer from different parts of the skin, is then processed and finally displayed

For dermatological purposes, high-frequency ultrasound within the range of 13.5-100 MHz is utilised and mostly performed at 20 MHz, which provides both epidermis and dermis

visualisation with axial resolution of 50-80 μm , lateral resolution of 150-300 μm and penetration of 7-14 mm (Rallan & Harland, 2004). Higher-frequency probes, 40-100 MHz, are merely able to display the epidermis at an axial resolution of 17-30 μm and a lateral resolution of 33-94 μm (Aspres et al., 2003; Rallan & Harland, 2003).

Ultrasound in Dermatology

Ultrasound imaging has been widely used in dermatology for the last 35 years. It was first proposed as a dermatological toolbox in which a 15-MHz probe was used to measure skin thickness by Alexander and Miller (1979). Since then, ultrasound practical applications in diagnostic dermatology have expanded, including the evaluation of benign and malignant lesions, assessment of infectious and inflammatory diseases, examination of foreign bodies present in soft tissue, measurement of skin thickness and estimation of tumour margins, estimation of volume in melanoma and non-melanoma skin cancer, evaluation of the efficacy of drugs, differentiation of dermal burns, visualisation of the skin structure and monitoring of the healing of acute and chronic wounds in both animal and clinical models (Dyson et al., 2003; Kleinerman et al., 2012; Moghimi et al., 2010; Rippon et al., 1998). However, some of its application such as wound assessment remain in experimental phases.

INTERPRETATION OF HEALTHY AND WOUNDED SKIN IN 2D B-SCANS

Ultrasound as a non-invasive, quantitative and reproducible imaging modality is able to provide visualisation of the epidermis, dermis, sweat glands and hair follicles as well as the collagen layer. The structures with high echogenicity are reflected as brighter (i.e. colourful) regions in the 2D B-mode images, while the ones with low echogenicity are observed as dark areas. Thus, it is worthwhile to consider a brief review of the ultrasonic characteristics of skin components that are practically used to interpret 2D B-mode images in dermatology (Figure 2).

As is seen in the image from the arm obtained by a 20-MHz ultrasound skin scanner (from left to right), the first echoic band belongs to the plastic water barrier film placed in the head of the probe, followed by the black area coming from the water inside the probe. The second echoic band obtained from the interface between the gel and the epidermis i.e. the second white line(s) shows the entry and exit echoes of the epidermis. As the thickness of the epidermis is too small in the arm area (<0.18 mm), the entry and exit echoes are superimposed, while in the case of thicker epidermis layers (e.g. foot sole), two separate echoic bands can be detected in the image.

After the epidermis, comes the dermis, with an average thickness of 1-4 mm consisting of three layers: papillary, reticular and hypodermis, which is a hypo-echoic area interspersed with hyper-echoic regions, a consistent hyper-echoic region and a hypo-echoic area, respectively. The papillary layer entails hypo-echoic fine collagen, while the curl collagen fibres in the reticular dermis placed parallel to the skin surfaces give rich echoes. The end of the reticular layer can be determined once the black area appears, due to the presence of homogenous subcutaneous fat and loose connective tissues. The muscle fascia that consists of collagen fibre bundles is presented as a hyper-echoic band below the hypodermis (Rippon et al., 1998). The sub-cutis is mostly layered with fat-fascia-fat-fascia bundles until the signal fades away.

The inclusions like hair follicles, blood vessels and sebaceous glands are generally echo-poor regions, while the blood vessel walls appear more echoic. Although muscle layer, including muscle and connective tissues, are echo-poor in nature, the presence of fibre bundles makes them echo-rich. In practice, muscle is difficult to measure using HFU imaging as it does not give a strong response.

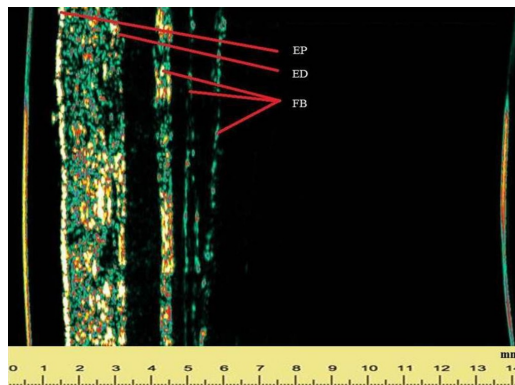


Figure 2. 2D B-scan image from the arm by 20-MHz Ultrasound Skin Scanner. The epidermis (EP) entry and exit echoes become super-positioned in the case of thin epidermis layer. End of dermis (ED) is defined where the colourful echo stops and the black area starts. The fascia bundles (FB) of collagen fibre are presented as hyper-echoic bands

The components of wounded skin show different characteristics compared to healthy skin constituents, which are enumerated as follows (Rippon et al., 1999; Rippon et al., 1998):

1. Blood clots including fibrin and fibrinogen are intermediate echo-poor or echo-rich regions, and their appearance in the 2D HFU image depends on their density.
2. Newly created collagen fibres at the early stage of healing (i.e. 2-3 days) encompass endothelial cells, fibroblasts, immature fibrous tissue and microphages that appear as echo-poor regions, while mature granulation tissue, curled and mature fibrous tissues seen after 4-21 days, are detected as hyper-echoic regions. In other words, the echogenicity of granulation tissue increases as the collagen fibres accumulated.
3. Epithelial cells are echo-lucent in nature, but a band of echo-rich tissue can be determined at the surface level due to tissue re-epithelialisation.
4. Scars, which are remodelled collagen, are relatively echo-poor regions and become more echo-lucent over time.

APPLICATIONS OF HFU IMAGING IN WOUND ASSESSMENT

As HFU imaging does not interfere with the healing process, it has been employed in studies that are mostly focussed on validation of B-mode HFU images and investigation of wound structures. The findings revealed that the 2D B-mode HFU images contain the most sought after parameters, namely depth and volume of the wound, depth of scars and blood clots, collagen

content and granulation tissue formation and changes in tissue regularity and homogeneity; and also depict the wound-healing phenomena comparable to established histological analysis. In other words, HFU imaging is a quantitative, reproducible, objective modality that examines living materials in microscopic details and provides measurement of tissue structural changes deep within a wound while carrying non-damaging aspects required for wound-healing assessment (Dyson et al., 2003; Foster et al., 2000). However, few studies have investigated the application of HFU imaging in assessing wound generation and healing. In this section, the related literature is reviewed in the context of two domains: Assessment of healing process and investigation of wound structures.

In an investigation, 10-40 MHz ultrasound waves were utilised to evaluate the beam attenuation coefficient in healthy skin and to explore the correlation between healing and ultrasound wave attenuation in surgical wounds aged between 9 and 49 days. It was reported that the ultrasound attenuation increased by 15% and 30% on day 9 and day 34 respectively, which was in line with the changes in the content of collagen. So, it was concluded that the attenuation coefficient may be highly correlated with the amount of collagen in the healing surgical wounds. However, their findings could not be generalised as the other factors like size of collagen fibres and their structural arrangement were not considered (Forster et al., 1990).

Meanwhile, Hoffmann et al. (1993) measured changes in the surface and volume of the cryosurgical defects, using a 20-MHz HFU to assess the efficacy of treatment strategy in 80 patients who received cryosurgery for treatment of basal cell carcinoma. The results demonstrated that the wound surface and volume can be used as a measure of treatment efficacy. However, the wound improvement could not be monitored when there were no significant dimensional changes. Moreover, the healing process in chronic wounds does not certainly follow the order of healing phases in acute surgical wounds.

In the study performed by Rippon et al. (1998), a 20-MHz HFU skin scanner was used to visualise skin structures and wound healing by comparing them with histological information. Firstly, healthy skin of different anatomical areas in pigs and human cadavers were scanned to identify and measure normal skin structures and the results were compared with histological findings. More specifically, the depth of skin layers including epidermis, dermis and hypodermis was measured, and the skin structures visualised in 2D B-mode images were compared with the histological results. The outcomes showed a significant relationship between both technique measurements ($r=0.97$, $P\text{-value}<0.0001$). Secondly, the full-thickness acute wounds induced on the pigs' dorsal area were scanned by a HFU skin scanner and investigated over time. In detail, the wound depth, blood clot depth and granulation tissue depth were measured using a HFU scanner at pre-determined time intervals and compared with histological measurements. The results revealed that there was a significant relationship between the amounts of accumulated fibrous granulation tissue in the wound measured by HFU imaging and histological study ($r=0.82$, $P\text{-value}<0.001$). It was concluded that periodic wound assessment can help to differentiate between healing and non-healing wounds. However, this approach cannot be used in considering clinical chronic wounds such as diabetic foot ulcers (DFUs) as the wound biopsy for histological investigation is infeasible. Moreover, the alteration in chronic wound

tissue structures like amount of collagen fibres and depth of blood clot may not be necessarily matched with their findings, as the healing process in chronic wounds is complex and does not absolutely follow the order of the healing phases in acute wounds.

The same research group monitored acute experimental wounds created on the dorsal area of pigs over a period of 21 days. In addition, clinical chronic wounds including healing and non-healing ulcers were scanned over six weeks during routine dressing changes. The sequence of events happening during the healing process was interpreted and compared with the findings obtained from studying the histological changes. It was discovered that the stages such as granulation tissue formation, wound contraction, and re-epithelialisation could be sequentially visualised using the high-frequency ultrasound skin scanner. Furthermore, wound margin, blood clots and scars could be detected in the HFU images, and healing and non-healing chronic wounds such as leg ulcers could be identified using the observed differences between the scans (Rippon et al., 1999).

Dyson et al. (2003) compared two non-invasive techniques, optical and HFU imaging, in punch biopsy wounds made on the forearm with a diameter of 4 mm post-operatively on day 3, 7, 14 and 21, and found that the wound margins could be clearly defined in 2D B-mode images compared to the optical images, especially in the presence of scabs. Moreover, the structural changes in the tissue deep within the wounds were distinguishably detected, i.e. the epidermis breakage and blood clot formation could be clearly seen on day 3, followed by granulation tissue formation on day 7 and regeneration of epidermis on day 14. Finally, an increment in wound echogenicity was observed on day 21, attributed to deposition of collagen fibres. It was concluded that the HFU imaging provides quantitative measurement of the structural changes in the tissue below the epidermis, while optical imaging can only capture superficial alterations.

Prabhakara (2006) determined corresponding features, echogenicity and thickness of the top skin layers, to a bruise visualised in B-mode scanning, and stated that these parameters can be used as disputable evidence of a bruise if the changes in healthy and bruised regions are much greater than the normal variation. When the qualitative changes in B-mode scans of the bruised and intact skin were compared through snapshot analysis, it was uncovered that different types of qualitative changes appeared in bruised skin compared to the control site, including fuzziness of the lower top-layer boundary, swelling, changes in top-layer thickness, increased irregular echogenic areas and echogenicity changes. Hence, it was concluded that usually more than these mentioned indicators are displayed in a B-scan of bruised skin that may help to detect an injury or a bruise within deep tissue layers.

In another research, pressure ulcers were induced on the limbs of 28 guinea pigs using a pressure delivery system, and those areas were monitored over 21 days with both a 20MHz HFU scanner and a digital camera. Then, the camera images were calibrated and the meaningful colour features were extracted from a 2D histogram. Apart from that, the texture features that portrayed the echo-graphic structural and echogenicity changes during healing were obtained from HFU images, which were categorised into five groups. A multi-layer perceptron neural network classifier was used and the outputs were integrated with a Fuzzy integral designed for fusion of information from both modalities. It was concluded that each individual

modality failed to discriminate some classes i.e. four examination days, while the fusion of both techniques was capable of determining generation of pressure ulcers and healing stages (Moghimi et al., 2011). However, their findings cannot be generalised to human skin wounds as healing of both may not necessarily follow the similar pattern. Moreover, the wounds were artificially induced in a controlled lab environment i.e. wound size, depth and severity were not comparable with clinical chronic wounds.

The evaluation of wound structures to determine an appropriate model for different types of wound was the focus of some investigations. Early detection of dermal wounds becomes possible in suspected skin areas that may help to prevent skin breakage. In an investigation, 15 chronic wounds including four DFUs, one pressure ulcer and 10 venous leg ulcers along with 30 scars were evaluated and characterised using image analysis of recorded video, 20-MHz HFU imaging and laser Doppler flowmetry. These tools provided ulcer and scar linear dimensions, ulcer and scar thickness along with their echogenicity and blood flow at the surface level of the ulcers and scars, respectively. These parameters were also measured in adjacent healthy skin for comparison. The results indicated that the blood flow in all types of chronic ulcers was 170% higher than in normal healthy skin and this can be used as a positive sign of healing, which is caused by the increment in perfusion of granulation tissue. The HFU imaging outcomes revealed that skin thickness in chronic ulcers was reduced by 0.5 mm compared to the intact skin. Moreover, the echo-poor regions detected in HFU images of DFUs were from those areas with thinner skin, where there were newly created healing areas. Finally, it was demonstrated that measuring the dimensions of chronic ulcers using binary image analysis or HFU imaging was more accurate than measurement by means of a calibrated ruler (Timar-Banu et al., 2001).

In another study, various types of chronic wound including DFUs, ischemic ulcers, venous and pressure ulcers and inflammatory ulcers were evaluated in terms of their skin structures, wound margins and wound area and volume using an ultrasound scanner with 8-12MHz frequency. Moreover, different phenomena like granulation tissue formation and sub-dermal edema were subjectively identified in the 2D B-mode images. The results indicated that HFU imaging can be used as an accurate, reproducible and non-invasive tool that may help physicians in diagnosing wound aetiology (Wendelken et al., 2003).

Du et al. (2006) evaluated severe burn scars using quantitative assessment of 2D B-mode images recorded by a 15-MHz ultrasound probe. An image reconstruction technique was utilised to identify the scar border and to estimate the depth, volume and surface area of burn scars. A phantom was used to simulate scar volumetric structure and to verify the accuracy of the proposed image processing chain. The findings showed that the estimation error of scar volume measurement was less than 10%. Therefore, it was concluded that an assessment tool based on the analysis of HFU images can be employed to evaluate burn scars in clinical practice. Table 1 summarises the aforementioned studies and their findings.

Table 1
Assessment of Wound Healing and Tissue Structural Changes Using Dermasonography in Clinical Studies

| Investigation Category | Authors (Year) | Type of Wound/ Ultrasound Probe | Findings and Inferences |
|-------------------------------|--------------------------|------------------------------------|---|
| | Forster et al. (1990) | Surgical/10-40 MHz | <ol style="list-style-type: none"> 1. Beam attenuation increased by 15% and 30% at day 9 and 34, respectively. 2. Attenuation coefficient may be highly correlated with the amount of collagen. |
| | Hoffmann et al. (1993) | Cryosurgical/20 MHz | <ol style="list-style-type: none"> 1. Wound surface and volume can be used as a measure of treatment efficacy. |
| | Rippon et al. (1998) | Acute/20 MHz | <ol style="list-style-type: none"> 1. Significant relationship between HFU & histology ($r=0.97$, $p\text{-value}<0.0001$). 2. Significant relationship between amounts of accumulated fibrous granulation tissue measured by HFU imaging & histological study ($r=0.82$, $p\text{-value}<0.001$). 3. Periodic wound assessment may help to differentiate between the healing and non-healing wounds. |
| Wound Healing Assessment | Rippon et al. (1999) | Acute & Chronic/20 MHz | <ol style="list-style-type: none"> 1. Stages of wound healing can be sequentially visualised using HFU imaging. |
| | Dyson et al. (2003) | Punch biopsy 20 MHz | <ol style="list-style-type: none"> 2. Wound margin, blood clots and scars can be detected in the HFU images. 1. Wound margins can be clearly defined in the HFU images compared to the optical images. 2. Tissue structural changes deep within the wound were distinguishable and easily detected. 3. An increment in wound echogenicity was observed at day 21, attributed to deposition of collagen fibres. 4. HFU imaging provides measures of structural changes below the epidermis. |
| Evaluation of Wound Structure | Prabhakara (2006) | Bruised skin/20 MHz | Different types of qualitative change like swelling, fuzziness of lower top-layer boundary etc. may appear in bruised skin compared to the control site. |
| | Moghimi et al. (2011) | Pressure ulcers/20 MHz | Fusion of HFU and optical imaging was capable of determining pressure ulcer generation and healing stages. |
| | Timar-Banu et al. (2001) | Chronic/20 MHz | <ol style="list-style-type: none"> 1. Blood flow was 170% higher than in normal healthy skin and can be used as a positive sign of healing. 2. Skin thickness in chronic ulcers was reduced by 0.5 mm compared to intact skin. 3. Measuring the dimensions of chronic ulcers using HFU imaging provided more accurate figures than when using a calibrated ruler. |
| | Wendelken et al. (2003) | Chronic/8-12 MHz | HFU imaging can be used as an accurate, reproducible and non-invasive tool that may help physicians in diagnosing wound aetiology. |
| | Du et al. (2006) | Burn scars/15 MHz | Error of scar volume measurement was less than 10%, allowing for the conclusion that analysis of HFU images can be used to evaluate burn scars in clinical practice. |

LIMITATIONS

All the reviewed studies were in agreement that HFU imaging can be utilised as a non-invasive, quantitative, reliable and cost-effective technique in wound-healing assessment. However, some aspects of HFU imaging capability were unclear due to design and analysis. For instance, most of the conclusions were subjective and limited to the correlation analysis between histological information and wound depth and width. Such comparison is infeasible for clinical chronic wounds as wound biopsy deteriorates the healing process. In addition, most of the investigations focused on the validation of 2D B-mode HFU images, not to quantitatively assess the wound healing. Moreover, they often evaluated the healing in acute experimental wounds induced on pigs and humans, where wound severity, depth and size and the healing phase sequential order did not necessarily follow patterns seen in acute wounds. It is equally important to point out that the accuracy and reliability of determining the most appropriate scan line(s) and selecting the region of interest in 2D B-mode HFU images are highly dependent on the physician's experience and the operator's skills; these can be subjective and time-consuming.

CONCLUSION

High-frequency ultrasound imaging has great potential for non-invasive and quantitative assessment of the wound-healing process, with additional information about underlying tissues. It can also be combined with other clinically established modalities such as optical imaging to provide comprehensive and accurate information on tissue dimensional and structural changes that may ameliorate patient discomfort by adopting proactive treatment regimens. Further work, however, is required to diminish the dependence on expert clinicians and operators by developing standard protocols for identifying the informative scan lines and for selecting the region of interest.

REFERENCES

- Alexander, H., & Miller, D. (1979). Determining skin thickness with pulsed ultra sound. *Journal of Investigative Dermatology*, 72(1), 17–19.
- Aspres, N., Egerton, I. B., Lim, A. C., & Shumack, S. P. (2003). Imaging the skin. *Australasian Journal of Dermatology*, 44(1), 19–27.
- Du, Y. C., Lin, C. M., Chen, Y. F., Chen, C. L., & Chen, T. (2006). Implementation of a burn scar assessment system by ultrasound techniques. *Paper presented at the Engineering in Medicine and Biology Society, 2006 EMBS'06 28th Annual International Conference of the IEEE* (pp. 2328–2331). IEEE.
- Dyson, M., Moodley, S., Verjee, L., Verling, W., Weinman, J., & Wilson, P. (2003). Wound healing assessment using 20-MHz ultrasound and photography. *Skin Research and Technology*, 9(2), 116–121.
- Forster, F. K., Olerud, J. E., Riederer-Henderson, M. A., & Holmes, A. W. (1990). Ultrasonic assessment of skin and surgical wounds utilizing backscatter acoustic techniques to estimate attenuation. *Ultrasound in Medicine and Biology*, 16(1), 43–53.
- Foster, F. S., Pavlin, C. J., Harasiewicz, K. A., Christopher, D. A., & Turnbull, D. H. (2000). Advances in ultrasound biomicroscopy. *Ultrasound in Medicine and Biology*, 26(1), 1–27.

- Hoffmann, K., Winkler, K., EL-Gammal, S., & Altmeyer, P. (1993). A wound healing model with sonographic monitoring. *Clinical and Experimental Dermatology*, *18*(3), 217–225.
- Humbert, P., Meaune, S., & Gharbi, T. (2004). Wound healing assessment. *Phlebology*, *47*, 312–319.
- Jones, T. D., & Plassmann, P. (2000). An active contour model for measuring the area of leg ulcers. *IEEE Transactions on Medical Imaging*, *19*(12), 1202–1210.
- Kleinerman, R., Whang, T. B., Bard, R. L., & Marmur, E. S. (2012). Ultrasound in dermatology: Principles and applications. *Journal of the American Academy of Dermatology*, *67*(3), 478–487.
- Moghimi, S., Baygi, M. H. M., & Torkaman, G. (2011). Automatic evaluation of pressure sore status by combining information obtained from high-frequency ultrasound and digital photography. *Computers in Biology and Medicine*, *41*(7), 427–434.
- Moghimi, S., Baygi, M. H. M., Torkaman, G., & Mahloojifar, A. (2010). Quantitative assessment of pressure sore generation and healing through numerical analysis of high-frequency ultrasound images. *Journal of Rehabilitation Research and Development*, *47*, 99–108.
- Plassmann, P. (1995). Measuring wounds. *Journal of Wound Care*, *4*(6), 269–272.
- Plassmann, P., & Belem, B. (2009). Early detection of wound inflammation by color analysis. In G. Schaefer, A. E. Hassanien & J. Jiang (Eds.), *Computational Intelligence in Medical Imaging: Techniques and Applications*, (pp. 89–110). New York, NY: CRC Press.
- Plassmann, P., & Jones, T. (1998). MAVIS: A non-invasive instrument to measure area and volume of wounds. *Medical Engineering and Physics*, *20*(5), 332–338.
- Prabhakara, S. (2006). *Acoustic imaging of bruises*. (Master's thesis). Georgia Institute of Technology, USA.
- Rallan, D., & Harland, C. (2003). Ultrasound in dermatology-basic principles and applications. *Clinical and Experimental Dermatology*, *28*(6), 632–638.
- Rallan, D., & Harland, C. (2004). Skin imaging: Is it clinically useful? *Clinical and Experimental Dermatology*, *29*(5), 453–459.
- Rippon, M., Springett, K., & Walmsley, R. (1999). Ultrasound evaluation of acute experimental and chronic clinical wounds. *Skin Research and Technology*, *5*(4), 228–236.
- Rippon, M., Springett, K., Walmsley, R., Patrick, K., & Millson, S. (1998). Ultrasound assessment of skin and wound tissue: Comparison with histology. *Skin Research and Technology*, *4*(3), 147–154.
- Shaw, J., & Bell, P. M. (2011). *Wound measurement in diabetic foot ulceration*. Global perspective on diabetic foot ulcerations. Croatia: InTech Open Access Publisher.
- Timar-Banu, O., Beauregard, H., Tousignant, J., Lassonde, M., Harris, P., & Viau, G. (2001). Development of noninvasive and quantitative methodologies for the assessment of chronic ulcers and scars in humans. *Wound Repair and Regeneration*, *9*(2), 123–132.
- Treuillet, S., Albouy, B., & Lucas, Y. (2009). Three-dimensional assessment of skin wounds using a standard digital camera. *IEEE Transactions on Medical Imaging*, *28*(5), 752–762.
- Wendelken, M., Markowitz, L., Patel, M., & Alvarez, O. (2003). Objective, noninvasive wound assessment using B-mode ultrasonography. *Wounds: A Compendium of Clinical Research and Practice*, *15*(11), 351–360.

