

PNEUMONIA AND CONCURRENT EGGS RETENTION IN A RIVER TERRAPIN (*BATAGUR BASKA*)

C.I. Inirah^{1a}, C.A. Azlan^{2*}, H.X. Teoh², Y. Donny¹ and F.F.A. Jesse²

¹Department of Wildlife and National Parks (DWNP) Peninsular Malaysia, Km 10 Jalan Cheras, Kuala Lumpur.

²Faculty of Veterinary Medicine, Universiti Putra Malaysia, UPM Serdang, Selangor, Malaysia.

SUMMARY

A case report of pneumonia and egg retention in a river terrapin was presented in this paper. A 20 year-old river terrapin (*Batagur baska*) was presented with complaint of coughing with blood discharge, wheezing breathing and inappetance. Plain radiograph showed both right and left lung lobes were consolidated due to pneumonia 90% and 70%, respectively. Tentative diagnosis of pneumonia due to opportunistic bacterial infection of *Chromobacterium* sp. and *Plesiomonas shigelloides* was made in this case based on bacterial isolation and response to antibiotic and anti-inflammatory drugs. Enrofloxacin and flunixin meglumine were administered from Day-1 to -5. Enrofloxacin was then changed to gentamicin since it showed resistance in those bacteria. No clinical changes were observed. Gentamicin was given at rate 2.5 mg/kg once a week intramuscularly and prednisolone 2 mg/kg once on Day-6 given intramuscularly, showed a response on Day-10 of hospitalisation with the evidence of reduction in lung consolidation by almost 90% clear of lung lobes from pneumonia. Sixteen thin-shelled eggs were also observed in the coelomic cavity on radiographic images. Active laying season, prolonged laying period and the history of laying only two eggs a week before presenting to hospital gives a highly suggestive diagnosis of egg retention syndrome. To encourage laying, the terrapin was given a daily parenteral calcium supplement, oxytocin 5 IU/kg intramuscularly (Day-10 hospitalisation) and was released for sunbath and to sand twice daily. The eggs were completely laid on Day-11 and the overall terrapin condition was greatly improved 2 weeks post-hospitalisation.

Keywords: Pneumonia, bacterial infection, egg retention, river terrapin, clinical management

INTRODUCTION

River terrapin also known as '*tuntung sungai*', is the common name of fresh water turtle, *Batagur baska* (*B. baska*). It is also known as 'The Royal River Terrapin' because its eggs were regarded as being a luxurious and special dish to the royal families of the Malay Peninsula in Perak (Duli, 2009). River terrapin is a common chelonian with a wide range of distribution in tropical countries include Bangladesh, Cambodia, India, Indonesia and Malaysia. This species is placed in the Class of Reptilia, Order Testudines, Family Geoemydidae and Genus *Batagur*. River terrapin is listed as critically endangered by the International Union for Conservation of Nature (IUCN) and reported to be extinct in Myanmar, Singapore, Thailand and Vietnam (IUCN, 2012). Population of river terrapin in Perak River in Malaysia was reported to decline approximately 38% from year 1969 to 1974 (Moll, 1990). The main reason of this rapid decrease in the population was due to disturbance of their natural habitat and also activity of harvesting their eggs for consumption.

Most recent population and conservation status in Malaysia was surveyed by Kalyar (2007) where *B. baska* in the Perak River (the second longest river in Peninsula Malaysia) continue to decline and estimated less than 50 breeding females remain in this river. However, Peninsula Malaysia represents the stronghold of river terrapin and relatively high populations in several

rivers on both the east and west coasts.

A large number of chelonian cases were related to inappropriate husbandry management such as inappropriate diet and suboptimal environment condition (Longley, 2013). A low temperature, poor ventilation and inappropriate food and nutrient may predispose to problems like respiratory disease, reproductive disorders, gastrointestinal parasitic infestation and others. Respiratory tract diseases are common occurrence in captive chelonians and infectious agents include viruses, bacteria, fungi, and parasites (Origi and Jacobson, 2000). Clinical signs are non-specific but may represented such as laboured breathing by mouth open and neck extension, inactive, anorexia and concurrent with other disease or syndrome (McArthur *et al.*, 2004). Optimising husbandry management and selection of appropriate treatment based on causal agent and predisposing factor may facilitate recovery.

Dystocia or egg retention or egg binding is commonly reported among captive reptiles, more frequently reported in turtles and snakes. Egg retention in reptiles can be multifactorial and may be the result of inappropriate nesting sites, stress, dehydration, malnutrition, obesity, salphingitis, malformed eggs and abnormal reproductive anatomy (DeNardo, 1996). Chelonian acquiring egg retention may be asymptomatic or may have one or more clinical signs such as anorexia, excessive basking, restlessness, constant digging behaviour, weakness and lethargy (Norton, 2005). The ecological and impact of lower respiratory tract diseases are not well reported in captive and free ranging terrapins. Multifactorial causes especially husbandry management

*Corresponding author: Dr. Azlan Che' Amat (C.A. Azlan);
Phone: +60 173433811; Email: azlancheamat@gmail.com

may be highly attributed to the occurrence of infectious diseases leading to other problem. This paper described a river terrapin presented with respiratory disorders with concurrent egg retention syndrome, the diagnostic approach and medical management of bacterial pneumonia and egg retention.

CASE REPORT

History and Diagnostic Workup

A 20-year-old, female river terrapin from the River Terrapin Wildlife Conservation Centre, Bota Kanan, Perak, Department of Wildlife and National Parks (DWNP), with a body weight of 15 kg was presented to University Veterinary Hospital (UVH), Universiti Putra Malaysia (UPM) with complaint of coughing blood and inappetance. Seven days before presentation, blood discharge was observed from the oral cavity. They also noticed 2 eggs were laid on the same day. There was no improvement observed after vitamin K, meloxicam and enrofloxacin were administered. Physical examination revealed the terrapin was coughing out foam of blood (Figure 1) with presence of wheezing.



Figure 1. Blood from the oral cavity as evidence on the latero-ventral lower jaw

Further diagnostic approaches were performed which include blood sampling from the jugular venipuncture for haematology and serum biochemistry, tracheal swab sampling for routine bacterial isolation, identification and antibiotic sensitivity, and thoracic radiography of anterior-posterior and latero-lateral view for observation of lungs. Tracheal swabs were also submitted for virus isolation.

The haematology and serum biochemistry results showed no evidence of infection or abnormality as compared to baseline parameters for *Testudo sp.* and *Gopherus sp.* (McArthur *et al.*, 2004) whereas a normal flora of fresh water which (e.g. *Chromobacterium sp.* and *Plesiomonas shigelloides*) were isolated from the tracheal swab. In addition, these bacteria were found to be resistant to enrofloxacin and oxytetracycline. No virus was isolated from the samples. Anterior-posterior and latero-lateral views of the lungs (Figure 2a, 2b, 2c) revealed bilateral increased radiopacity or consolidation

of lungs fields which indicate pneumonia. Estimated about 90% and 70% lung consolidation of the right and left lung lobes respectively. There was an evidence of 16 thin-shelled eggs in the coelomic cavity. The diagnosis of this case was pneumonia possibly due to opportunistic bacterial infection as evidence by culture and egg retention was based on the evidence of prolonged retention of egg since the first egg was laid a week before presented.

Treatment and Progression

Treatments given for inappetance were 15 ml/kg of 0.9% Sodium Chloride (0.9% Sodium Chloride, B.Braun[®], Melsungen, Germany) 300 ml subcutaneously into the inguinal and front limb fossa and force fed with mashed water spinach and banana. On Day-9 of hospitalisation, the appetite and eating behaviour were back to normal. Pneumonia was treated with enrofloxacin (Baytril[®], Bayer Healthcare, Kansas, USA) 10 mg/kg subcutaneously once a day for the first 5 days. Flunixin meglumine (Flunixin 50 mg/ml[®], Norbrook[®], KS, USA) 1 mg/kg intramuscularly (pelvic muscle of hind limbs) was given for the first 3 days. Prednisolone (Prednikal 01[®], Kela N.V., Hoogstraten, Belgium) 2mg/kg was also given intramuscularly once on Day-6. Gentamicin (Ilium Gentam 50[®], Troy Laboratories, NSW, Australia), 2.5 mg/kg intramuscularly twice on Day-6 and Day-13. Enrofloxacin was changed to gentamicin since the bacteria isolated were resistant to enrofloxacin.

Pneumonia was greatly improved on Day-10 of hospitalisation based on resolved of clinical signs and radiological findings (Figure 3). The lungs showed more radiolucent-like a typical of normal lungs (90% clear from the consolidation of pneumonia) as compared to initial radiograph. Other supportive treatment given were vitamin K (Vitamin K₃[®], Vétaquinol S.A., Lure, France) 0.5mg/kg, intramuscular, once a day for 2 days; iron based supplement (Fercobsang[®], Vétaquinol S.A., Lure, France) 0.5 ml, intramuscular, once a day for 7 days. The foam of blood from the oral cavity and inappetance were resolved on Day-7 of hospitalisation. Egg retention was managed with release on sand twice a day under the morning and afternoon sunlight for 15 minutes, calcium supplement (Theracalcium[®], Vétaquinol S.A., Lure, France) 100 mg/kg, subcutaneously once a day; oxytocin (Ocytokel[®], Kela N.V., Hoogstraten, Belgium) 5 IU/kg, intramuscularly once for 2 days (14 eggs were laid 45 minutes after first oxytocin on the same day and the same dose was repeated on the next day for the remaining eggs) and vitamin D₃ supplement (Vitavet[®], Nova Medicine Co. Ltd, Pathumthani, Thailand) 2 ml, intramuscularly, once a day for 2 days. The egg stasis was resolved on Day-11 of hospitalisation. The terrapin was discharged 2 weeks after hospitalisation with all clinical signs resolved.

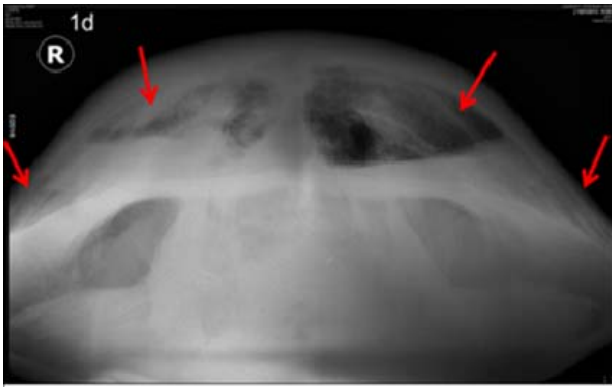


Figure 2a. Craniocaudal view: Increase radiopacity of lung lobes (arrow), 90% consolidation of pneumonia on the right lung lobe and 70% lung consolidation of pneumonia on the left lobe

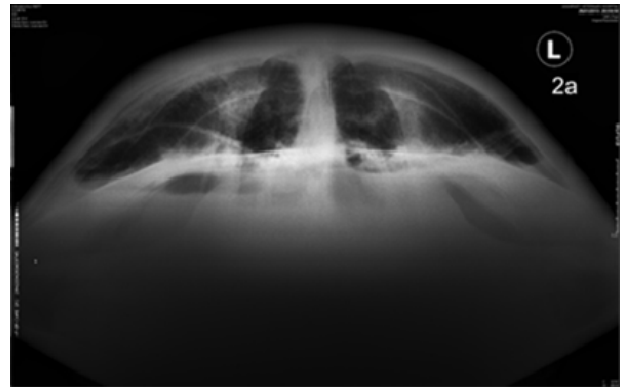


Figure 3. Craniocaudal view: A significant 90% reduction of lungs consolidation due to pneumonia 10 days post-medical management.

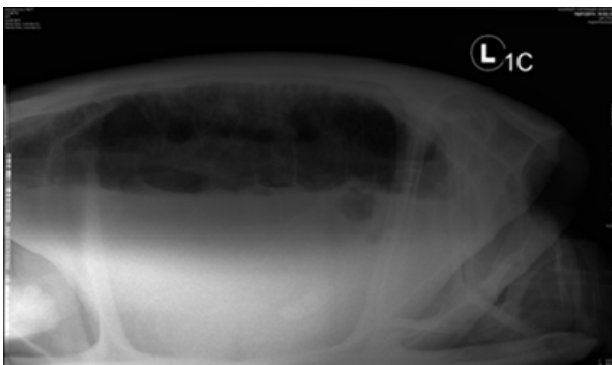

Figure 2b. Left lateral view: Increase radiopacity of the lungs indicating consolidation due to pneumonia

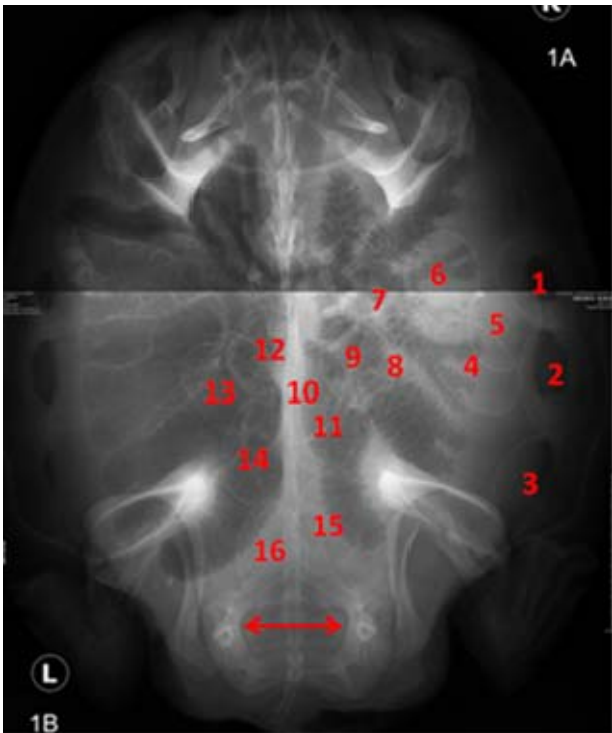


Figure 2c. Dorsoventral view: Presence of 16 normal size thin-shelled eggs in the coelomic cavity with normal width of pelvic inlet (longitudinal arrow)

DISCUSSION

Pneumonia in chelonians could be due to bacteria, fungus, virus, parasites or other non-infectious causes. Among the bacterial causes, Gram-negative bacteria are found to be the most common agent causing pneumonia in chelonians. It mostly involves opportunistic commensal species. Isolation of oral normal flora e.g. *Pseudomonas*, *Klebsiella*, *Aeromonas*, *Salmonella*, *Pasteurella* and *Proteus* in lower respiratory tract of diseased chelonian were reported (Abdul Aziz *et al.*, 2008a,b; Mader, 2006). Moderate multifocal, subacute broncho-interstitial pneumonia has been reported in a gravid female bog turtle in which the condition was due to infection by Gram negative bacteria such as *Pseudomonas* sp. and/or *Aeromonas* sp. (Carter *et al.*, 2005). In this study, *Plesiomonas shigelloides*, a common aquatic bacterial species was isolated. It has been found in pneumonic lung of a common otter (Jagger, 2000). This suggested that *Plesiomonas shigelloides* could also cause pneumonia in other aquatic species such as chelonian. *Chromobacterium*-like sp. have been isolated from anal sample in healthy captive desert tortoise (Snipes *et al.*, 1980). *Chromobacterium* sp. isolated in this case suggested the possibility that pneumonia may be caused by this bacterium. This is seen in a study in captive Greek tortoises where *Chromobacterium* sp. were isolated from samples of nasal exudates of rhinitic cases (Martinez-Silvestre and Antonio, 1997). Other reports also stated *Chromobacterium violaceum* have been isolated from captive Macquarie turtle (*Emydura macquarii*) (Scheelings *et al.*, 2012). However, it was not known whether the bacteria isolated was incidental or infection but this pathogen should be included in a list of differential diagnoses. Although most of the bacteria that cause pneumonia is considered as secondary problem reports of *Chlamydomyces* and *Mycobacteria* sp. have found to cause primary infection (Mader, 2006).

Fungal pneumonia is relatively uncommon in chelonians. The occurrence of fungal pneumonia is usually due to overuse of antibiotics, overexposure to fungal spores or immunocompromised status. Fungal respiratory diseases in turtles have been identified as those caused by *Aspergillus*, *Beauveria*, *Cladosporium*, and *Paeilomyces* through culture (Johnson, 2004).

Herpesvirus is an important agent that resulted in viral respiratory disease in chelonians; however, it frequently causes upper respiratory tract disease (McArthur *et al.*, 2004). Prolonged viral diseases such as herpesvirus infection may progress to lower respiratory tract if the nutrition and husbandry have been impaired. Herpesvirus was reported to cause pneumonia in green sea turtle with concurrent conjunctivitis and tracheitis (Mader, 2006). Other causes of pneumonia in chelonians include parasitic agents (e.g. pentastomids, trematodes), non-infectious causes (e.g. aspiration of foreign object) and, mixed and varied combination of causes (Origgi and Jacobson, 2000).

Dystocia or egg retention in chelonians not always required emergency treatment, unless there is an obstructive process involved such as oversize eggs or/and occlusion of the cloacal opening and/or pelvic inlet. It may be difficult to determine when a gravid patient is overdue or when to intervene either medically or surgically (Norton, 2005). In non-obstructive egg retention like this case (normal egg size with suboptimal egg shell calcification), the terrapin may be pretreated with calcium for a few days to harden the shell followed by oxytocin to stimulate contraction and the eggs normally should pass out within 30 to 60 min. The terrapin successfully laid all eggs within 45 min after the first oxytocin injection. The remaining eggs were laid on the next day after the second injection was conducted.

Any sick animal needs minimum database such as a complete blood count and serum chemistry analysis to make a disease investigation (Johnson, 2004). Detail history and physical examination are crucial to diagnose pneumonia in chelonian. Findings that suggest pneumonia such as abnormal breath sound, increased respiratory rate and imbalance swimming pattern are important signs (Murray, 1996). Haematology and biochemistry have limited usefulness since the baseline data are not available. However, these tests can help to determine other underlying diseases that might lead to pneumonia. Radiography especially craniocaudal and lateral view are very useful to diagnose pneumonia in chelonian although unable to determine the causative agent (Murray, 1996). Tracheal swab and tracheal washes are the common procedures perform to obtain sample for pathogen identification with higher sensitivity in tracheal wash, however requires general anaesthesia or sedation. Endoscopic examination provides good opportunity for the determination of a definitive diagnosis in live chelonian. Lung tissue samples can be collected through this technique for cytology, culture as well as histopathologic examination. However, general anaesthesia cannot be exempted. In case of dead animal, post mortem examination can be performed to obtain definitive diagnosis (Norton, 2005; Johnson, 2004; Murray, 1996). In this case, radiological observation, tracheal swab bacterial isolation and sensitivity test helped the chosen of the suitability of clinical management.

CONCLUSION

Opportunistic bacterial pneumonia was suspected in this case since *Chromobacterium* sp. and *Plesiomonas shigelloides* were isolated. This assumption was strengthened by the terrapin respond well to medical treatment especially antibiotic therapy. Gravid terrapin predispose to elevated stress (besides presence of environmental stressors) and leads to immune-compromised that predispose to bacterial infection causing pneumonia. However, other causes of pneumonia cannot be ruled out. An optimal choice of antibiotic based on bacterial isolation and sensitivity test may facilitate good response to treatment. Concurrent egg stasis was managed medically as the condition did not require an emergency intervention.

CONFLICT OF INTEREST

None of the authors have any potential conflicts of interest to declare. C.I. Inirah equally contributed to this work.

ACKNOWLEDGEMENT

This case was investigated at the University Veterinary Hospital, Faculty of Veterinary Medicine Universiti Putra Malaysia, assisted by Large Animal Unit staff and final year students of Doctor of Veterinary Medicine program during the large animal clinical rotation.

REFERANCES

- Abdul Aziz, S., Hassan, L. and Zakaria, Z. (2008a) Salmonella in captive chelonians and other reptiles and their health implications. *Jurnal Veterinar Malaysia*. 20 (1).
- Abdul Aziz, S., Hassan, L., Zakaria, Z. and Norazrena, A. (2008b) Salmonella in pet and captive chelonians and other reptiles and their public health implications. *Jurnal Veterinar Malaysia*. 20 (1).
- Carter, S. L., Horne B.D., Herman D.W., Nichols D.K., Haas, C.A., Mitchell, J.C. (2005). Bacterial pneumonia in free-ranging bog turtles, *Glyptemys muhlenbergii*, from North Carolina and Virginia. *Journal of the North Carolina Academy of Science*. 121 (4): 170-173.
- DeNardo, D. (1996) Dystocia. In: *Reptile medicine and surgery*. Mader, D.R.(ed). W. B. Saunders., Philadelphia, 370-374.
- Duli, N. (2009). Morphometric and genetic variability of river terrapin (*Batagur baska*) and painted terrapin (*Batagur borneensis*). Master of Science (MSc) thesis. Universiti Sains Malaysia. pp: 153.
- IUCN (2012) International Union for Conservation of Nature. Asian Turtle Trade Working Group 2000. *Batagur baska*. In: IUCN 2012. IUCN Red List of Threatened Species. Version 2012.2 <www.iucnredlist.org>. Assessed on 28 April 2013.
- Jagger, T. D. (2000). *Plesiomonas shigelloides*-a veterinary perspective. *Infectious Disease Review*. 2(4): 199-210.
- Johnson, J. H. (2004). Husbandry and medicine of aquatic reptiles. *Seminar in Avian and Exotic Pet Medicine*. 13(4): 223-228.
- Kalyar, Thorbjarnarson, J. and Thirakhupt, K. (2007). An overview of the current population and conservation status of the critically endangered river terrapin, *Batagur baska* (Gray, 1831) in Myanmar, Thailand and Malaysia. *The Natural History Journal of Chulalongkorn University*. 7(1): 51-65.
- Longley, L. (2013). Non-infectious diseases associated with husbandry problems in captive chelonia. *British Chelonia Group*. <http://www.britishcheloniagroup.org.uk>. Assessed on 23/11/2013.
- Mader, D. R. (2006). *Reptile medicine and surgery* (2nd edition). Saunders Elsevier, St. Louis, USA. Pp: 1264.

- McArthur, S., Wilkinson, R., & Meyer, J. (2004). *Medicine and surgery of tortoises and turtles*. Blackwell Publishing, Oxford, UK. Pp:600.
- Martinez-Silvestre, A. and Antonio, M. (1997). Bacteriological features of rhinitis in captive Greek tortoises, *Testudo graeca*. *Association of Reptilian and Amphibian Veterinarians*. 7(2): 12-15.
- Moll, E. O. (1990). Status and management of the river terrapin (*Batagur baska*). Final Project Report, WWF Malaysia, Petaling Jaya, Selangor, 1-45.
- Murray M.J. (1996). Pneumonia and normal respiratory function. In Mader (1996) (ed): *Reptile medicine and surgery*. WB Saunders Co, Philadelphia, USA. 396-405.
- Norton, T.M. (2005). Chelonian emergency and critical care. *Seminars in Avian and Exotic Pet Medicine*. 14(2): 106-130.
- Origi, F.C. and Jacobson, E.R. (2000). Diseases of the respiratory tract of chelonians. *Veterinary Clinics of North America: Exotic Animals Practice*. 3(2): 537-49.
- Scheelings, T.F., Tesdorpf, R., Hooper, C. and Stalder, K. (2012). *Chromobacterium violaceum* isolation from a Macquarie turtle (*Emydura macquarii*). *Journal of Herpetological Medicine and Surgery*. 22 (1-2): 22-24.
- Snipes, K.P., Biberstein, E.L., and Fowler, M.E. (1980). A *Pasteurella* sp associated with respiratory disease in captive desert tortoises. *Journal of the American Veterinary Medical Association*. 177(9): 804-807.