

UNDIAGNOSED TRAUMATIC DIAPHRAGMATIC HERNIA IN TWO CATS

S.F. LAU

Faculty of Veterinary Medicine, Universiti Putra Malaysia, UPM Serdang, Malaysia

SUMMARY

Two cases of diaphragmatic hernia in cats caused by road traffic accident were undiagnosed during the initial presentation. Both cats showed no evidence of respiratory distress and clinicians did not notice the diaphragmatic hernia on thoracic radiographs. Later on, both cats showed signs of dyspnea and diaphragmatic hernia was diagnosed with repeated thoracic radiograph and ultrasound. Diaphragmatic hernia is rather common in veterinary practice, however, its diagnosis can be clinically challenging. This case report highlights the importance to re-evaluate and monitor the patient closely after the traffic accident. Repeated radiograph, different diagnostic modalities and techniques such as ultrasound, computed tomography and positive contrast peritoneography should be used in order to diagnose the diaphragmatic hernia conclusively.

Keywords: Hernia, diaphragm, radiograph, cat

INTRODUCTION

Traumatic diaphragmatic hernia in cats is commonly caused by auto mobile accident or blunt abdominal trauma (Schmiedt *et al.*, 2003; Minihan *et al.*, 2004). The mechanism of diaphragmatic hernia was related to the increased pressure gradient between the pleural and peritoneal cavities during the blunt trauma, particularly when the glottis is open (Fossum, 2002). Diaphragmatic hernia can result in life threatening respiratory compromise and herniation of the abdominal organs into the thoracic cavity may result in inability to inflate lung lobes and entrapment of the abdominal organ (Gibson *et al.*, 2005). Most of the time, these hernia are diagnosed immediately after the traumatic incident and repaired surgically. Surgical repair is necessary to relieve the respiratory compromise and to re-establish the diaphragmatic function (Fossum, 2002).

Despite of the extensive reports of diaphragmatic hernia in cats (Garson *et al.*, 1980; Voges *et al.*, 1997; Schmiedt *et al.*, 2003; White *et al.*, 2003; Minihan *et al.*, 2004; Gibson *et al.*, 2005; McClaran, 2013), recognition of diaphragmatic hernia can still pose a significant clinical challenge, particularly in those animals that have no discernable signs of breathing difficulty and lack of radiographic signs to support the diagnosis of diaphragmatic hernia. Those diaphragmatic hernia cases that are missed diagnosed may present with symptom of obstruction of herniated viscera later on.

This report describes the clinical and radiographic features in two cases of where the diaphragmatic hernia was not detected during the initial presentation. It showed the importance to repeat the thoracic radiograph in order to conclusively identify the diaphragmatic hernia.

CASE REPORT

Case 1

A seven months old male domestic shorthair cat (weighing 1.9 kg) was presented to the University Veterinary Hospital (UVH), Universiti Putra Malaysia a day after hit by car. During the presentation, cat showed non weight bearing on the right hind limb with no evidence of increased respiratory effort and thoracic auscultation was unremarkable. Soft tissue swelling and pain was elicited on palpation of the right femur. Plain radiographic examination of the thorax (ventrodorsal and right lateral views; Figure 1a and 1b) and right hind limb (craniocaudal and right mediolateral views) were performed without general anesthesia. On the ventrodorsal view, loss of the left diaphragmatic crus and increased inspection.

Cat lost approximately 400 g within two weeks and notably less active. Heart sound was pounding and lung sound was not clear during the auscultation. Second thoracic radiographic examination was carried out (ventrodorsal and right lateral views; Figure 2a and 2b). Herniation of the gastrointestinal tracts into the left thoracic cavity and obvious loss of the left diaphragmatic crus outline was detected. Cardiac silhouette was displaced to the right side on the ventrodorsal view with functioning lung capacity less than 50%. Diaphragmatic hernia was diagnosed and cat was sent for surgical repair. Unfortunately, cat did not recover from anesthesia and died due to cardiopulmonary arrest.

Case 2

A six months old male domestic shorthair cat (weighing 1.7 kg) was brought to UVH immediately after involved in an automobile accident. During the presentation, the physical examination showed unremarkable result and cat was breathing in a reasonably normal manner. Plain thoracic radiographic examination was carried out (dorsoventral and left lateral views, Figure

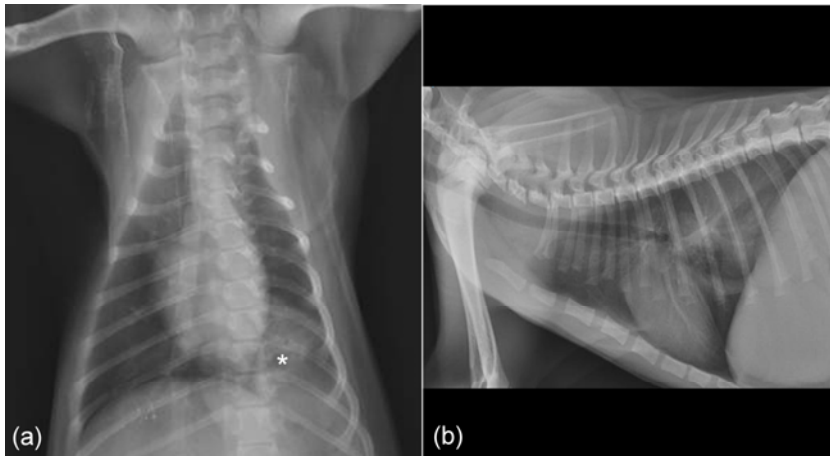


Figure 1. (a) Ventrodorsal view of thorax showing loss of the left diaphragmatic crus and increased soft tissue opacity at the left caudal lung lobe (*). (b) Right lateral view of thorax showing an increased opacity in the caudodorsal thoracic cavity during the initial presentation. (b) Herniation of the gastrointestinal tracts into the left thoracic cavity in the repeated radiograph

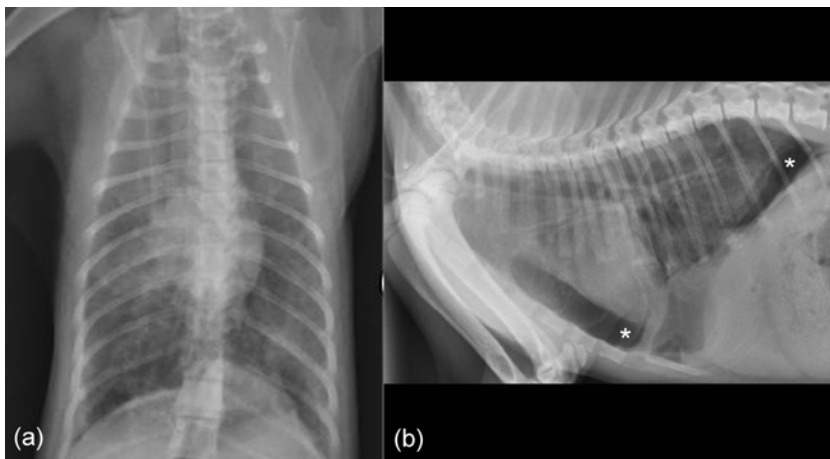


Figure 2. (a) Herniation of the gastrointestinal tracts (white arrows) into the left thoracic cavity and obvious loss of the left diaphragmatic crus in the repeated radiograph. (b) Air-filled intestinal tract (*) was herniated into the thoracic cavity

Figure 3. (a) Dorsoventral view of thorax at the initial presentation. (b) Left lateral view of thorax showing evidence of pneumothorax. Caudodorsal lung lobe was retracted from the periphery of the thorax and air (*) was found at the cranioventral and caudodorsal region. Cardiac silhouette was elevated from the sternum

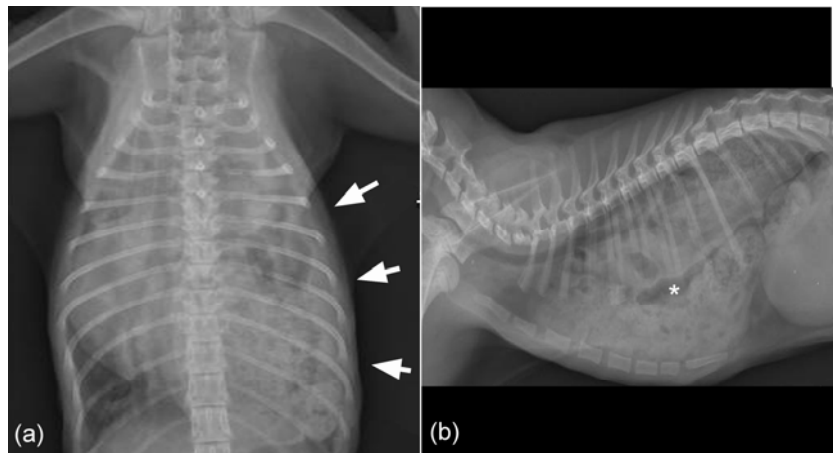
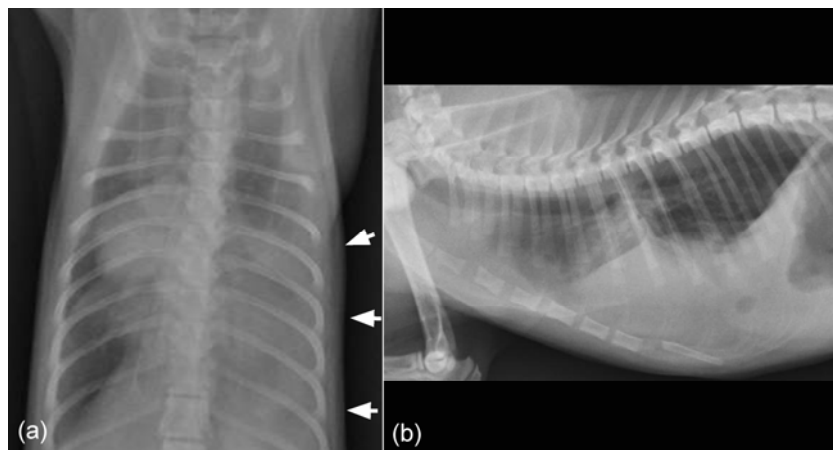


Figure 4 (a) Cardiac silhouette was displaced to the right side and loss of diaphragmatic cupula and left diaphragmatic crus outline in the repeated radiograph. Increased of soft tissue opacity can be observed at the left caudal lung lobe region (white arrows). (b) There was increased soft tissue opacity in the caudoventral lung field in the repeated radiograph



3a and 3b). Caudodorsal lung lobe was retracted from the periphery of the thorax and air was found at the cranioventral and caudodorsal region. Cardiac silhouette was elevated from the sternum. Pneumothorax was diagnosed and thoracocentesis was planned. During the establishment of the intravenous access, cat became cyanotic. In total, 100 ml of air was aspirated from both left and right pleural cavity.

During the second day of hospitalization, cat developed dyspnea and labored breathing. Second thoracic radiograph was made, comprising of and dorsoventral and left lateral views (Figure 4a and 4b). On the dorsoventral view, cardiac silhouette was displaced to the right side and loss of diaphragmatic cupula and left diaphragmatic crus outline. On the lateral view, there was increased soft tissue opacity in the caudoventral lung field. Positive contrast peritoneography was performed but the result was unremarkable. Ultrasonography was then performed. Discontinuity of the diaphragmatic outline part and part of the liver was detected herniated into the thoracic cavity. Despite surgical repair was performed, cat died within 24 hours after surgery with suspected due to other complications from the liver disease.

DISCUSSION

Radiographic signs of diaphragmatic hernia include the presence of abdominal viscera in the thoracic cavity, interruption of the diaphragmatic outline, asymmetry of the slope of the diaphragm, presence of the pleural effusion and displacement of the abdominal and thoracic organs (Sullivan and Lee, 1989; Hyun, 2004). Most traumatic diaphragmatic hernia cases involve the cupula and the herniated content tends to locate ventrally (Sullivan and Lee, 1989). Cats were often presented with clinical signs such as weight loss, anorexia, lethargy, vomiting, dyspnea and tachypnea. Apart from the diaphragmatic hernia, skeletal and multi-organs injuries were frequently reported (Schmiedt *et al.*, 2003; Minihan *et al.*, 2004). Without the conclusive radiographic findings of diaphragmatic hernia and obvious clinical signs, diaphragmatic hernia might be missed, especially when it is overshadowed by other injuries that dominate the clinical pictures and complicated by the associated clinical signs. In a case study reported in 2004 (Minihan *et al.*, 2004), more than 30% of the diaphragmatic hernia did not conclusively demonstrated with thoracic radiograph and repeated thoracic radiograph was necessary to identify the diaphragmatic hernia.

In case 1, asymmetrical of the diaphragmatic crura and displacement of the gastric cranially in ventrodorsal view should be taken as a radiographic sign for diaphragmatic hernia. The eventration of the diaphragm might have indicated the subtotal diaphragmatic tears in where the serosa of the thoracic surface of the diaphragm remains intact. In this case, clinician focused more on the fractured right femur and overlooked the eventration of the diaphragm. Despite dorsoventral radiography of the thorax is recommended all the time in dyspneic animals, ventrodorsal view was used in this case because the cat was more tolerant of dorsal recumbence. In case 2, we speculated that the diaphragm became weakened after the

accident and with all the restraining activities with the cat, eventually led to the breakdown of the diaphragm outline. The diaphragm is an anatomic barrier with tendinous and muscular portions which preventing the direct communication between the pleural and peritoneal cavities (Eren and Çiriş, 2005). During the occurrence of the blunt trauma, the pressure within the abdominal cavity rose causing the tears of the diaphragm, and this suddenly raised pressure difference forces the abdominal organs herniated into the thoracic cavity through the diaphragm defect. Minor activities, such as restraining and struggling may also cause diaphragmatic hernia via enlargement of defect on the weakened diaphragm. Both cats were having tear at the left diaphragmatic crus and this is not uncommon as the right crus is stronger in comparison to the left crus (McClaran, 2013).

In order to overcome the misdiagnosis of diaphragmatic hernia, multiple radiographic projections, gastrointestinal contrast studies, positive contrast peritoneography and ultrasound are recommended (Rendano, 1970; Stickle, 1984; Sullivan and Lee, 1989). In human, misdiagnosed diaphragmatic hernia is not uncommon. Ultrasound, computed tomography and magnetic resonance imaging are frequently used to confirm the diaphragmatic defects (Sukul *et al.*, 1991). Besides showing the abdominal organ's abnormalities, it shows diaphragm continuity and herniated organs (McClaran, 2013). According to Ball (1982), diaphragmatic hernia was diagnosed most of the time when the injury was new and tear is large with identifiable organs herniated. Appropriate diagnostic procedures play a crucial role in making the diagnosis accurately.

CONCLUSION

This report describes difference appearances of clinical and radiographic pictures of diaphragmatic hernia in two cases that was missed during the initial presentation. It highlighted the importance to re-evaluate and monitor the patient closely. Repeated thoracic radiograph is of crucial importance in order to conclusively identify the diaphragmatic hernia.

FUNDING

The authors received no specific grant from any funding agency in the public, commercial or not-for-profit sectors for the preparation of this case report.

CONFLICT OF INTEREST

None of the authors have any potential conflicts of interest to declare.

ACKNOWLEDGEMENTS

The authors would like to thank all the staffs of the Diagnostic Imaging Unit, University Veterinary Hospital, Universiti Putra Malaysia.

REFERANCES

- Ball, T., McCrory, R., Smith, J. O., et al. (1982) Traumatic diaphragmatic hernia: errors in diagnosis. *American Journal of Roentgenology* 138: 633-637.
- Eren, S. and Çiriş, F. (2005) Diaphragmatic hernia: diagnostic approaches with review of the literature. *European Journal of Radiology* 54: 448-459.
- Fossum, T.W. (2002) Surgery of the kidney and ureter. In: *Small Animal Surgery*. 2nd ed. Mosby, St Louis, MO, USA, pp 549-571.
- Garson, H. L., Dodman, N. H. and Baker, G. J. (1980) Diaphragmatic hernia. Analysis of fifty-six cases in dogs and cats. *Journal of Small Animal Practice* 21: 469-481.
- Gibson, T. W., Brisson, B. A. and Sears, W. (2005) Perioperative survival rates after surgery for diaphragmatic hernia in dogs and cats: 92 cases (1990-2002). *Journal of the American Veterinary Medical Association* 227: 105-109.
- Hyun, C.B. (2004) Radiographic diagnosis of diaphragmatic hernia: review of 60 cases in dogs and cats. *Journal of Veterinary Science* 5: 157-162.
- McClaran, J. K. (2013) Diaphragmatic and peritoneopericardial diaphragmatic hernias, In: *Small Animal Soft Tissue Surgery* (ed E. Monnet), John Wiley & Sons, Ltd, Chichester, UK, pp 278-285.
- Minihan, A. C., Berg, J. and Evans, K. L. (2004) Chronic diaphragmatic hernia in 34 dogs and 16 cats. *Journal of the American Animal Hospital Association* 40: 51-63.
- Rendano, V. T. (1979) Positive contrast peritoneography: An aid in the radiographic diagnosis of diaphragmatic hernia. *Veterinary Radiology* 20: 67-73.
- Schmiedt, C. W., Tobias, K. M. and Stevenson, M. M. (2003) Traumatic diaphragmatic hernia in cats: 34 cases (1991-2001). *Journal of the American Veterinary Medical Association* 222: 1237-1240.
- Stickle, R. L. (1984) Positive-contrast celiography (peritoneography) for the diagnosis of diaphragmatic hernia in dogs and cats. *Journal of the American Veterinary Medical Association* 185: 295-298.
- Sukul, D. M., Kats, E. and Johannes, E. J. (1991) Sixty-three cases of traumatic injury of the diaphragm. *Injury* 22: 303-306.
- Sullivan, M. and Lee, R. (1989) Radiological features of 80 cases of diaphragmatic rupture. *Journal of Small Animal Practice* 30: 561-566.
- Voges, A. K., Bertrand, S., Hill, R. C., et al. (1997) True diaphragmatic hernia in a cat. *Veterinary Radiology & Ultrasound* 38: 116-119.
- White, J. D., Tisdall, P. L. C., Norris, J. M., et al. (2003) Diaphragmatic hernia in a cat mimicking a pulmonary mass. *Journal of feline medicine and surgery* 5: 197-201.