

COMPLEMENT SYSTEM SPECIFICALLY C5a RECEPTOR, INFLAMMATION AND HYPERTROPHIC CARDIOMYOPATHY (HCM) IN CATS

K.H. Khor*

Faculty of Veterinary Medicine, University Putra Malaysia, UPM Serdang, Malaysia

The complement system

The complement cascade is a unique sequence of molecular events occurring within the vascular system in which inactive plasma proteins synthesised by the liver are activated following tissue injury (Figure) (McGavin and Zachary, 2007). The increase permeability of blood vessels during inflammation is stimulated, at least in part, by the complement system. The complement system is a complex system of 30 serum proteins. Many early components are serine proteases that are activated sequentially to form a cascade. The complement cascade is activated through any one, or more, of four pathways: the classical, the mannan-binding lectin (MBL), the alternative and the extrinsic protease pathways (Guo and Ward, 2005; Monk *et al.*, 2007; Ricklin and Lambris, 2007). For further information, refer (Manthey *et al.*, 2009).

The classic pathway can be activated when IgG and/or IgM are cross linked with C1. C1 has three

components: C1q, r and s. The first protein in the complement cascade, C1q, binds the Fc regions of IgG and/or IgM and brings C1r, which is proteolytic, into proximity to C1s, which is cleaved; through interactions with C2 and C4, and leads to the formation of classical pathway of C3 and C5 convertase. The MBL pathway is initiated by binding of the mannan-binding lectin, a serum protein, to mannose-containing carbohydrates of bacteria or viruses. Lastly, the alternative pathway of C3 and C5 convertase can be initiated when a spontaneously activated complement component binds to the surface of a pathogen (microbial surface polysaccharides). A recently discovered fourth “extrinsic” activation pathway can also occur when endogenous proteases such as thrombin directly cleave the central complement components C3 and C5 (Guo and Ward, 2005; Hogan *et al.*, 2004; Kirschfink, 1997; Monk *et al.*, 2007).

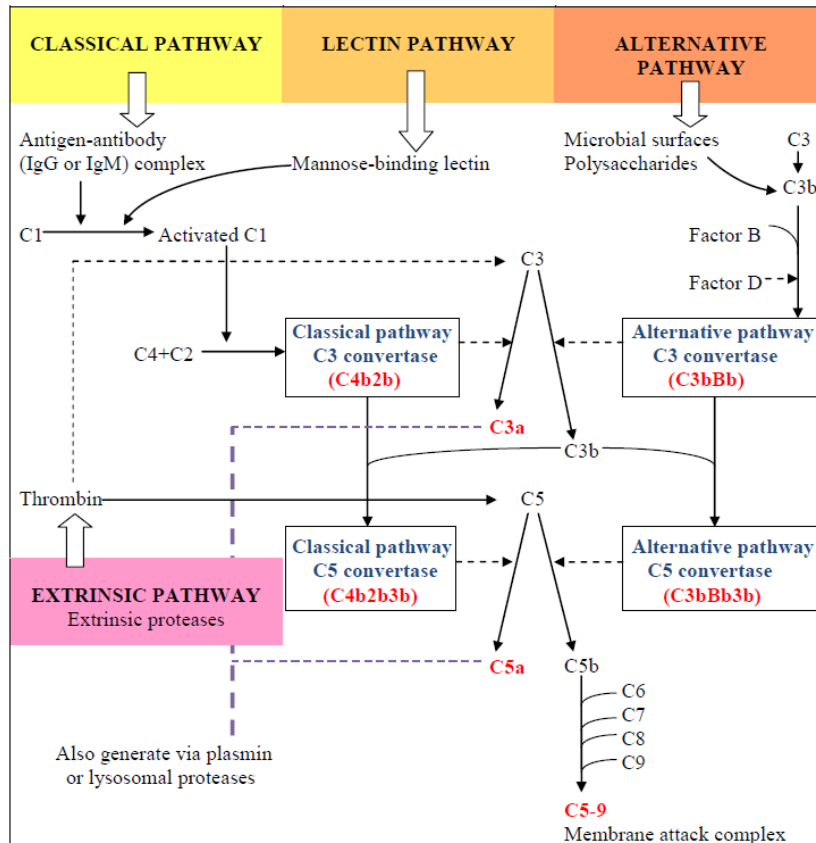


Figure 1. Component and pathways of the complement cascade

The complement system bridges the innate and adaptive immune systems, which (respectively) based on non-specific recognition of foreign carbohydrates or specific recognition of foreign protein antigens. Complement proteins are chemotactic for inflammatory cells, such as monocytes and neutrophils, which, in turn, increase vascular permeability to enhance access into the infected and damaged area. Complement activation is also essential to the process of opsonisation where antigens entering the body are coated by complement. Opsonisation assists recognition by the antibody of a particular antigen prior to formation of the antigen-antibody complex and phagocytosis (Rus *et al.*, 2005).

One of the complement of interest is the C5a that binds with similar high affinity to both C5a receptor (C5aR), CD88 and C5L2. C5aR belongs to the rhodopsin family of G-protein-coupled receptors (GPCR), and mediates most of the known activities of C5a (Gerard and Gerard, 1991; Vassilatis *et al.*, 2003). C5L2 has a similar protein structure but is not G-protein coupled. Although C5a binds with high affinity to C5L2, few biological responses have been found for this interaction (Okinaga *et al.*, 2003). C5L2 is present on neutrophils and immature dendritic cells (Ohno *et al.*, 2000). C5aR expression was originally described on myeloids cells including neutrophils, leukocytes, eosinophils, basophils and monocytes (Chenoweth and Hugli, 1978; Gerard *et al.*, 1989; Kurimoto *et al.*, 1989; Monk *et al.*, 2007; Werfel *et al.*, 1992). More recently, C5aR has also been found on a variety of non-myeloids cells in many organs, especially in the lung and liver (Haviland *et al.*, 1995; Schieferdecker *et al.*, 2001).

Possible role of C5a/C5aR, inflammation and the cardiovascular system

The complement system is an innate immune mechanism activated in response to infection or injury. The complement activation product, C5a, is the most potent anaphylatoxin produced by the pathway, and by binding to its C5aR located on numerous cell types, it induces a wide range of inflammatory and immune effects (Guo and Ward, 2005), such as sepsis (Ward, 2004), ischaemia-reperfusion injury (Arumugam *et al.*, 2002), arthritis (Woodruff *et al.*, 2002) and asthma (Drouin *et al.*, 2001). Besides that, C5a also acts as a potent chemoattractant to inflammatory cells (Guo and Ward, 2005). Activated neutrophils trigger the excessive production of reactive oxygen species (ROS) and the release of lysosomal enzymes that leads to necrosis of cells within local organs, and subsequent loss of organ function (Frangogiannis *et al.*, 2002; Guo and Ward, 2005). Thus, although complement activation may not be the initiating factor in disease, much of the subsequent damage to tissue may be complement-mediated.

The complement system, particularly anaphylatoxin C5a and its receptor, C5aR, has a role in many diseases (Manthey *et al.*, 2009), including cardiomyopathy (Afanasyeva and Rose, 2002). The complement receptor has been shown to play a significant role in myocardial ischaemia (Busche and Stahl, 2010; Monsinjon *et al.*, 2001; Yasojima *et al.*, 1998; Zhang *et al.*, 2007) and in

other ischaemic diseases (specifically CD88, (Arumugam *et al.*, 2004; Arumugam *et al.*, 2007; Thundyil *et al.*, 2012). Furthermore, exposure to C5a will decrease the contractility of cardiomyocytes *in vitro* (Niederbichler *et al.*, 2006), while inhibition of C5aR activity will reduce myocardial infarct size (Zhang *et al.*, 2007) and ameliorate inflammation in myocardium (Hoesel *et al.*, 2007; Niederbichler *et al.*, 2006; Vakeva *et al.*, 1998; van der Pals *et al.*, 2010). It is therefore possible that complement, particularly, C5aR, may play a role in the pathogenesis and/or progression of HCM. The question that must be asked is: If inflammation is evident in the myocardium of cats with HCM (Khor *et al.*, 2015), will C5aR (specifically CD88) play a major role eliciting the associated inflammatory response? In addition, do any changes in CD88 receptor density contribute to affect the activity of β -adrenoreceptors, particularly since an interaction between adrenoreceptors and the complement system has been identified.

Inflammation and Hypertrophic Cardiomyopathy

Hypertrophic cardiomyopathy (HCM) is a primary myocardial disease characterised by concentric left ventricular hypertrophy associated with diastolic dysfunction and arrhythmias. The disease progression of HCM is variable with congestive heart failure being an important clinical outcome. Treatment is challenging and usually focuses on attempts to delay onset or control signs of congestive heart failure and reduce the risk of systemic thromboembolism and sudden death.

HCM has a wide range of histopathological abnormalities but myocardial fibre disarray is a distinctive hallmark of HCM. The myocytes are arranged in chaotic, disorganised patterns at oblique and/or perpendicular angle which appeared in a bizarre disorganised cellular architecture (Figure 2) (Baty *et al.*, 2001; Fox, 2003; Khor *et al.*, 2015; Kittleson and Kienle, 1998; Liu *et al.*, 1993; Nakagawa *et al.*, 2002; Tilley *et al.*, 1977).

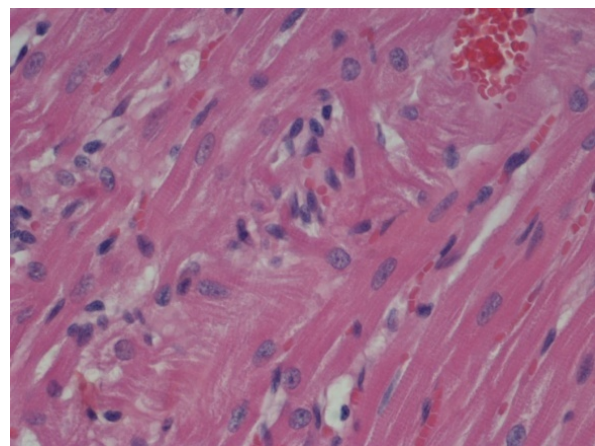


Figure 2. A cat with pre-clinical hypertrophic cardiomyopathy, the latter demonstrating an area of myocardial fibre disarray with disordered arrangement of cardiac muscle cells at oblique angles to each other (Khor *et al.*, 2015)

Other histopathological findings are hypertrophied myocytes, increased collagen deposition (Khor *et al.*, 2015) resulting interstitial fibrosis and abnormalities of the intramyocardial small vessels (Cesta *et al.*, 2005; Fox, 2003; Liu *et al.*, 1993; Nakagawa *et al.*, 2002; Varnava *et al.*, 2000). It is likely that these abnormal structural changes disrupt the transmission of electrophysiology impulses predisposing the diseased heart to diastolic dysfunction and ventricular tachyarrhythmia (Fox, 2003; Kittleson and Kienle, 1998; Liu *et al.*, 1981; Liu *et al.*, 1993; Tilley *et al.*, 1977).

The frequency of each abnormality observed varied between HCM cats (Liu *et al.*, 1993). Liu *et al.* (1981) found 25% of the HCM cats (n=51) observed with asymmetric left ventricular hypertrophy had myocardial fibre disarray in the IVS. In other HCM hearts, only myocyte hypertrophy was evident or some had moderate-to-severe interstitial. Replacement fibrosis was present in about 20 - 40% of HCM cases (Liu *et al.*, 1993). The histopathological findings differ between HCM hearts probably due to cardiac remodelling which occurs at different stages of the disease, maybe depending on the extent of the damage. The pre-clinical HCM cats have similar histopathological findings at the early stage despite detectable functional changes. Interestingly, recent study by Khor *et al.* (2015) shown that the left myocardium of cats with pre-clinical HCM has multifocal areas of inflammatory cell infiltration, predominantly lymphocytes, were observed frequently. Tissue from cats with pre-clinical HCM also had a higher number of neutrophils and a greater collagen content than the myocardium of normal cats (Khor *et al.*, 2015).

It was then hypothesised that early (pre-clinical) HCM was characterised by, and possibly initiated by, inflammatory events (Khor *et al.*, 2015; Khor *et al.*, 2013), in addition to any increase in left ventricle wall thickness in diastole and evidence of diastolic dysfunction. Infiltration of inflammatory cells into myocardial tissue (Khor *et al.*, 2013) appeared to occur prior to the onset of structural and functional changes may therefore contribute to disease pathogenesis and/or efficacy of pharmacological agents used to treat HCM. It would be interesting to determine if this observation is the same in cats with more severe HCM. Further studies that include immunohistochemical myocardial staining and evaluate circulating inflammatory cytokines are indicated to better characterise the role of inflammation in the pathogenesis and early development of fibrosis in feline HCM.

REFERENCES

Afanasyeva, M., Rose, N.R. (2002). Cardiomyopathy is linked to complement activation. *American Journal of Pathology*. 161: 351-357.

Arumugam, T.V., Shiels, I.A., Woodruff, T.M., Granger, D.N., Taylor, S.M. (2004). The role of the complement system in ischemia-reperfusion injury. *Shock*. 21: 401-409.

Arumugam, T.V., Shiels, I.A., Woodruff, T.M., Reid, R.C., Fairlie, D.P., Taylor, S.M. (2002). Protective effect of a new C5a receptor antagonist against ischemia-reperfusion injury in the rat small intestine. *Journal of Surgery Research*. 103: 260-267.

Arumugam, T.V., Tang, S.C., Lathia, J.D., Cheng, A., Mughal, M.R., Chigurupati, S., Magnus, T., Chan, S.L., Jo, D.G., Ouyang, X., Fairlie, D.P., Granger, D.N., Vortmeyer, A., Basta, M., Mattson,

M.P. (2007). Intravenous immunoglobulin (IVIG) protects the brain against experimental stroke by preventing complement-mediated neuronal cell death. *Proceeding of the Natural Academic of Science. U.S.A.* 104: 14104-14109.

Baty, C.J., Malarkey, D.E., Atkins, C.E., DeFrancesco, T.C., Sidley, J., Keene, B.W. (2001). Natural history of hypertrophic cardiomyopathy and aortic thromboembolism in a family of Domestic shorthair cats. *Journal of Veterinary Internal Medicine*. 15: 595-599.

Busche, M.N., Stahl, G.L. (2010). Role of the complement components C5 and C3a in a mouse model of myocardial ischemia and reperfusion injury. *German Medical Science* 8: 1-11.

Cesta, M.F., Baty, C.J., Keene, B.W., Smoak, I.W., Malarkey, D.E. (2005). Pathology of end-stage remodeling in a family of cats with hypertrophic cardiomyopathy. *Veterinary of Pathology* 42: 458-467.

Chenoweth, D.E., Hugli, T.E. (1978). Demonstration of specific C5a receptor on intact human polymorphonuclear leukocytes. *Proceedings of the Natural Academic of Science U.S.A.* 75: 3943-3947.

Drouin, S.M., Kildsgaard, J., Haviland, J., Zabner, J., Jia, H.P., McCray, P.B., Jr., Tack, B.F., Wetsel, R.A. (2001). Expression of the complement anaphylatoxin C3a and C5a receptors on bronchial epithelial and smooth muscle cells in models of sepsis and asthma. *Journal of Immunology*. 166: 2025-2032.

Fox, P.R. (2003). Hypertrophic Cardiomyopathy. *Clinical and pathologic correlates. Journal of Veterinary Cardiology*. 5: 39-45.

Frangogiannis, N.G., Smith, C.W., Entman, M.L. (2002). The inflammatory response in myocardial infarction. *Cardiovascular Research*. 53: 31-47.

Gerard, N.P., Gerard, C. (1991). The chemotactic receptor for human C5a anaphylatoxin. *Nature* 349: 614-617.

Gerard, N.P., Hodges, M.K., Drazen, J.M., Weller, P.F., Gerard, C. (1989). Characterization of a receptor for C5a anaphylatoxin on human eosinophils. *Journal of Biology. Chemistry*. 264: 1760-1766.

Guo, R.F., Ward, P.A. (2005). Role of C5a in inflammatory responses. *Annual Review Immunology*. 23: 821-852.

Haviland, D.L., McCoy, R.L., Whitehead, W.T., Akama, H., Molmenti, E.P., Brown, A., Haviland, J.C., Parks, W.C., Perlmutter, D.H., Wetsel, R.A. (1995). Cellular expression of the C5a anaphylatoxin receptor (C5aR): Demonstration of C5aR on nonmyeloid cells of the liver and lung. *Journal of Immunology*. 154: 1861-1869.

Hoesel, L.M., Niederbichler, A.D., Schaefer, J., Ipaktchi, K.R., Gao, H., Rittirsch, D., Pianko, M.J., Vogt, P.M., Sarma, J.V., Su, G.L., Arbabi, S., Westfall, M.V., Wang, S.C., Hemmila, M.R., Ward, P.A. (2007). C5a-blockade improves burn-induced cardiac dysfunction. *Journal of Immunology*. 178: 7902-7910.

Hogan, D.F., Andrews, D.A., Green, H.W., Talbott, K.K., Ward, M.P., Calloway, B.M. (2004). Antiplatelet effects and pharmacodynamics of clopidogrel in cats. *Journal of American Veterinary Medical Association*. 225: 1406-1411.

Khor, K.H., Campbell, F.E., Owen, H., Shiels, I.A., Mills, P.C. (2015). Myocardial collagen deposition and inflammatory cell infiltration in cats with pre-clinical hypertrophic cardiomyopathy. *The Veterinary Journal*. 203: 161-168.

Khor, K.H. and Mills, P.C. (2013). Inflammation and β 1-adrenoreceptor antagonist during feline hypertrophic cardiomyopathy, Vol 2013 AVA Annual Conference, Cairns. Australian Veterinary Association.

Kirschfink, M. (1997). Controlling the complement system in inflammation. *Immunopharmacology*. 38: 51-62.

Kittleson, M.D., Kienle, R.D., 1998, *Small Animal Cardiovascular Medicine*. Mosby, St. Louis, USA, 603 p.

Kurimoto, Y., de Weck, A.L., Dahinden, C.A. (1989). Interleukin 3-dependent mediator release in basophils triggered by C5a. *Journal of Experimental. Medicine*. 170: 467-479.

Liu, S.K., Maron, B.J., Tilley, L.P. (1981). Feline hypertrophic cardiomyopathy: Gross anatomic and quantitative histologic features. *American Journal of Pathology*. 102: 388-395.

Liu, S.K., Roberts, W.C., Maron, B.J. (1993). Comparison of morphologic findings in spontaneously occurring hypertrophic cardiomyopathy in humans, cats and dogs. *American Journal of Cardiology*. 72: 944-951.

- Manthey, H.D., Woodruff, T.M., Taylor, S.M., Monk, P.N. (2009). Complement component 5a (C5a). *International Journal of Biochemistry and Cell Biol.* 41: 2114-2117.
- McGavin, M.D., Zachary, J.F. (2007). *Pathological basis of veterinary disease*, 4 Edition. Mosby Elsevier, St. Louis, Missouri, USA.
- Monk, P.N., Scola, A.M., Madala, P., Fairlie, D.P., 2007, Function, structure and therapeutic potential of complement C5a receptors. *British Journal of Pharmacology.* 152: 429-448.
- Monsinjon, T., Richard, V., Fontaine, M. (2001). Complement and its implications in cardiac ischemia/reperfusion: strategies to inhibit complement. *Fundamental Clinical Pharmacology.* 15: 293-306.
- Nakagawa, K., Takemura, N., Machida, N., Kawamura, M., Amasaki, H., Hirose, H. (2002). Hypertrophic cardiomyopathy in a mixed breed cat family. *Journal of Veterinary Medicine Science.* 64: 619-621.
- Niederbichler, A.D., Hoesel, L.M., Westfall, M.V., Gao, H., Ipaktchi, K.R., Sun, L., Zetoune, F.S., Su, G.L., Arbabi, S., Sarma, J.V., Wang, S.C., Hemmila, M.R., Ward, P.A. (2006). An essential role for complement C5a in the pathogenesis of septic cardiac dysfunction. *Journal of Experimental Medicine.* 203: 53-61.
- Ohno, M., Hirata, T., Enomoto, M., Araki, T., Ishimaru, H., Takahashi, T.A. (2000). A putative chemoattractant receptor, C5L2, is expressed in granulocyte and immature dendritic cells, but not in mature dendritic cells. *Molecular Immunology.* 37: 407-412.
- Okinaga, S., Slattery, D., Humbles, A., Zsengeller, Z., Morteau, O., Kinrade, M.B., Brodbeck, R.M., Krause, J.E., Choe, H.R., Gerard, N.P., Gerard, C. (2003). C5L2, a non-signaling C5A binding protein. *Biochemistry (Mosc).* 42: 9406-9415.
- Ricklin, D., Lambris, J.D. (2007). Exploring the complement interaction network using surface plasmon resonance. *Advance Experimental Medical Biology.* 598: 260-278.
- Rus, H., Cudrici, C., Niculescu, F. (2005). The role of the complement system in innate immunity. *Immunology Research.* 33: 103-112.
- Schieferdecker, H.L., Schlaf, G., Jungermann, K., Gotze, O. (2001). Functions of anaphylatoxin C5a in rat liver: direct and indirect actions on nonparenchymal and parenchymal cells. *International Immunopharmacology* 1: 469-481.
- Thundyil, J., Pavlovski, D., Hsieh, Y.H., Gelderblom, M., Magnus, T., Fairlie, D.P., Arumugam, T.V. (2012). C5a Receptor (CD88) Inhibition Improves Hypothermia-Induced Neuroprotection in an In Vitro Ischemic Model. *Neuromolecular Medicine.* 14: 30-39.
- Tilley, L.P., Liu, S.K., Gilbertson, S.R., Wagner, B.M., Lord, P.F. (1977). Primary myocardial disease in the cat. A model for human cardiomyopathy. *American Journal of Pathology.* 86: 493-522.
- Vakeva, A.P., Agah, A., Rollins, S.A., Matis, L.A., Li, L., Stahl, G.L. (1998). Myocardial infarction and apoptosis after myocardial ischemia and reperfusion: Role of the terminal complement components and inhibition by anti-C5 therapy. *Circulation* 97: 2259-2267.
- van der Pals, J., Koul, S., Andersson, P., Gotberg, M., Ubachs, J.F., Kanski, M., Arheden, H., Olivecrona, G.K., Larsson, B., Erlinge, D. (2010). Treatment with the C5a receptor antagonist ADC-1004 reduces myocardial infarction in a porcine ischemia-reperfusion model. *BMC Cardiovascular Disorders* 10: 45.
- Varnava, A.M., Elliott, P.M., Sharma, S., McKenna, W.J., Davies, M.J., (2000). Hypertrophic cardiomyopathy: The interrelation of disarray, fibrosis, and small vessel disease. *Heart* 84: 476-482.
- Vassilatis, D.K., Hohmann, J.G., Zeng, H., Li, F., Ranchalis, J.E., Mortrud, M.T., Brown, A., Rodriguez, S.S., Weller, J.R., Wright, A.C., Bergmann, J.E., Gaitanaris, G.A. (2003). The G protein-coupled receptor repertoires of human and mouse. *Proceeding of Natural Academic of Science U.S.A.* 100: 4903-4908.
- Ward, P.A. (2004). The dark side of C5a in sepsis. *Nature Review Immunology.* 4: 133-142.
- Werfel, T., Oppermann, M., Schulze, M., Krieger, G., Weber, M., Gotze, O. (1992). Binding of fluorescein-labeled anaphylatoxin C5a to human peripheral blood, spleen, and bone marrow leukocytes. *Blood* 79: 152-160.
- Woodruff, T.M., Strachan, A.J., Dryburgh, N., Shiels, I.A., Reid, R.C., Fairlie, D.P., Taylor, S.M. (2002). Antiarthritic activity of an orally active C5a receptor antagonist against antigen-induced monarticular arthritis in the rat. *Arthritis Rheumatism.* 46: 2476-2485.
- Yasojima, K., Schwab, C., McGeer, E.G., McGeer, P.L. (1998). Human heart generates complement proteins that are upregulated and activated after myocardial infarction. *Circulation Research.* 83: 860-869.
- Zhang, H., Qin, G., Liang, G., Li, J., Barrington, R.A., Liu, D.X., 2007, C5aR-mediated myocardial ischemia/reperfusion injury. *Biochemical and Biophysical Research Communication.* 357: 446-452.