

***Nigella sativa* Meal Alleviates Injury against Benzo[a]Pyrene Exposures in Broilers**

Latif, I.K.^{1,2}, Karim, A.J.¹, Zuki, A.B.¹, Zamri-Saad, M.¹ and Noordin, M.M.^{1*}

¹*Department of Pathology and Microbiology, Faculty of Veterinary Medicine, Universiti Putra Malaysia, 43400 UPM, Serdang, Selangor, Malaysia*

²*Department of Pathology and Avian Diseases, Faculty of Veterinary Medicine, University of Baghdad, 10071 Baghdad, Iraq*

*E-mail: noordin@vet.upm.edu.my

ABSTRACT

This study was conducted to evaluate the effects of *Nigella sativa* (Ns) meal on such influences of Benzo[a]Pyrene (BaP) on the broilers performance, pulmonary index (PI), and histopathological changes. Chicks were assigned into four equal groups, namely as controls, Ns, BaP and BaP with Ns. Six birds were sacrificed at days 7, 14, 21, and 35. The results revealed that there were significant decreases ($p < 0.05$) in the mean body weight (BW) values and body weight gain (BWG) in the BaP alone group. Pulmonary weight (PW) and index increased ($p < 0.05$) in the same group compared to the control groups. Pulmonary morphology showed heavy infiltration and denudation of ciliated epithelium in the trachea, with infiltration by polymorphonuclear and mononuclear cells in the parabronchi of the lung, in the BaP exposed chickens. *Nigella sativa* (Ns) supplementation significantly alleviated these alterations, and thereby showing a potent anti-inflammatory effect after 14 days in the treated group. A key finding from this study is that BaP triggers inflammatory disorders and this transient effect is believed to be fatal if an infection occurs warranting a reassessment of the health status on exposure, and Ns was found to be helpful in alleviating such effects in broiler chickens.

Keywords: Benzo[a]pyrene, *Nigella sativa*, pulmonary morphological, broiler

INTRODUCTION

Poultry industry has continuously been hit by adverse respiratory conditions, which are economically and scientifically important (Toth, 2000) since the lung is a major target organ for numerous atmospheric pollutants and micro-organisms. Among the atmospheric pollutants, polycyclic aromatic hydrocarbons (PAHs) are ubiquitous in distribution.

Benzo[a]pyrene (BaP) is a member of the PAH family and a potent mutagen, carcinogen, and/or developmental toxicant (Castellano *et al.*, 2003). There is a dearth of information on the

effects of BaP as environmental contaminants on a non-mammalian species. Birds have been shown to be a suitable indicator of environmental pollution (Brown *et al.*, 1997) to which intra-tracheal (i.t) administration of 15 mg/kg BW BaP impairs the respiratory macrophage activity and induces hemato and hepatotoxicity in broilers (Latif *et al.*, 2009; 2010).

Nigella sativa (Ns) is a multipurpose medicinal plant used in folk medicine for the treatment and prevention of a wide number of diseases all over the world (Ramadan, 2007). Feeding growing chicks on diet containing

Received: 20 July 2010

Accepted: 23 September 2010

*Corresponding Author

natural feed additives, such as Ns, has been reported to improve chicks' performance, digestibility and decreased abdominal fat (Ashayerizadeh *et al.*, 2009). One of the potential properties of Ns seeds is to reduce inflammatory activity as a result of their antioxidant activities (Salem, 2005). The aim of the study was to assess the effects of i.t exposure of BaP on broiler performance, pulmonary index (PI) and morphological changes of the trachea and lung.

MATERIALS AND METHOD

A total of 96 newly hatched male broiler chicks were weighed and randomly divided into four equal groups of 24 chicks in cages and provided with recommended management protocols, including provision of feed and water *ad libitum*. The first group was chosen as a control group, and it was given i.t tricapyrylin only for 5 consecutive days and fed on commercial broiler diet only or with additional Ns 20 g/kg diet. The BaP groups were instilled with BaP 15 mg/kg body weight (BW) that was initially dissolved in tricapyrylin by the same route and period and fed either with commercial broiler diet only or in addition to Ns. All the chickens were individually weighed every week to determine their BW, body weight gain (BWG), feed intake (FI), and feed conversion ratio (FCR). Six birds from each group were sacrificed at 7, 14, 21, and 35 days post instillation (p.i), while necropsy was performed immediately. Trachea and lungs were lightly blotted and collectively weighed (pulmonary weight [PW]).

Hence, the pulmonary index was calculated as follows: $\{PWg/BWg\} \times 100$. Meanwhile, the morphological changes were observed by light microscopy using routine processing methods. The statistical analysis was determined by the analysis of variance (ANOVA) and when the differences were significant, the Tukey's tests were used and the value of $p < 0.05$ was considered as significant.

RESULTS AND DISCUSSION

All the groups recorded an increase in BW (Table 1) throughout the experiment. Commencing from day 7 until the end of the experiment, the BW of the broilers from the BaP alone group was almost always the lowest ($p < 0.05$). However, that of the BaP+Ns was only significantly higher ($p < 0.05$) than the BaP alone group at days 21 and 35.

Likewise, the BWG of the BaP was the lowest ($p < 0.05$) than the other groups at days 1-21 and 1-35 (Table 2). The calculated FI and FCR yielded a similar trend albeit without being subjected to statistical test due to single sampling (Table 3) during the experimental trail.

The findings of the present study have indicated that the i.t administration of BaP significantly impairs broiler performance (BW, BWG, FI and FCR) which is synonymous with the findings that the BaP administered at any route produces a systemic toxic effect (Sun *et al.*, 1982). Such phenomenon, if converted into economic terms (farm scale basis), is inevitably defined as a substantial loss. On the other hand oral supplementation of Ns reduced the adverse

TABLE 1
The body weight of broilers throughout the trail (mean ± SD)

Organs	Groups	Days p.i			
		7	14	21	35
Body weight (g)	Control	180 ± 7.50 ^a	509 ± 18.0 ^a	971 ± 19.4 ^a	1981 ± 43 ^a
	Ns	177 ± 6.50 ^a	512 ± 44.4 ^a	981 ± 40.7 ^a	1990 ± 24 ^a
	BaP	150 ± 10.6 ^b	429 ± 30.0 ^b	844 ± 36.4 ^b	1853 ± 48 ^b
	BaP+Ns	159 ± 7.32 ^b	468 ± 24.0 ^{ab}	922 ± 58.0 ^a	1929 ± 34 ^a

^{a, b} Values bearing similar superscript/s within the column do not differ at $p < 0.05$

TABLE 2
The body weight gain of broilers throughout the experiment (mean ± SD)

Groups	Days p.i		
	1-21	21-35	1-35
Control	926 ± 18.8 ^a	1010 ± 56 ^a	1936 ± 42 ^a
Ns	939 ± 41.0 ^a	1008 ± 62 ^a	1947 ± 26 ^a
BaP	800 ± 36.2 ^b	1009 ± 29 ^a	1810 ± 48 ^b
BaP+N _s	880 ± 58.4 ^a	1004 ± 84 ^a	1884 ± 38 ^a

^{a, b} Values bearing similar superscript/s in the same row do not differ at p< 0.05

TABLE 3
The FI, FCR of broilers throughout the experiment

Groups	Days p.i					
	1-21		21-35		1-35	
	FI	FCR	FI	FCR	FI	FCR
Control	1082	1.168	2125	2.103	3207	1.656
Ns	1085	1.155	2168	2.150	3253	1.670
BaP	1028	1.285	2230	2.210	3258	1.800
BaP+N _s	1073	1.219	2202	2.193	3257	1.738

effects of BaP shown by an improvement of the broiler performance (BW, BWG, FI, and FCR). This is in consonance with the finding that feeding growing chicks on diet containing natural feed additives, such as N_s improved chicks performance, digestibility and decreased abdominal fat (Ashayerizadeh *et al.*, 2009).

A trend of increased of PW was seen in all the groups during the course of the experiment (Table 4), but this increments were always higher (p<0.05) in the BaP groups at days 7 and 14. Nonetheless, a decreasing pattern of the PI was seen in all the groups as time advanced. Such a decrement was almost always lower (p<0.05) only in the BaP group, although significant changes were observed at day 7 in the BaP+N_s group as compared to the BaP group alone.

Organ and its relative body weight are important criteria for the evaluation of organ toxicity (Sellers *et al.*, 2007). The reduction in PI, despite an increase in PW, was due to a much higher weight gain. The higher the PI in the BaP group suggests that pulmonary

pathology is arising from BaP toxicity (Bailey *et al.*, 2004) and is due to the massive invasion of inflammatory cells, congestion and atelectasis (*Fig. 1b, 2b*) invoked by the instilled BaP (Slauson, 1982; Kontoni *et al.*, 1999).

In the BaP+N_s, it was found that N_s improved the broilers organ and its relative body weights via alleviation of BaP effects by reducing damages to cells as a result of their antioxidant activity (Ramadan, 2007), enhancing the immunity of the host (Soliman *et al.*, 1999) or by their anti-inflammatory action (Ali and Blunden, 2003).

While normal histology was observed in the trachea of the control and N_s groups (*Fig. 1a*), that of the BaP group displayed degenerative and inflammatory lesions (*Fig. 1b*). This was composed of mononuclear cell infiltration, necrosis and sloughing of the epithelial mucosa.

Similarly, the parabronchial sections of the lung of the control group (*Fig. 2a*) were within normal limits, but that of the BaP group showed mononuclear cell infiltration, atelectasis,

TABLE 4
The pulmonary weight and indices of broilers throughout the trail (mean ± SD)

Parameter	Group	Days p.i			
		7	14	21	35
Pulmonary weight (g)	Control	1.596 ± 0.082 ^a	4.122 ± 0.319 ^a	7.556 ± 0.375 ^a	12.53 ± 0.395 ^a
	Ns	1.622 ± 0.061 ^a	4.123 ± 0.420 ^a	7.697 ± 0.535 ^a	12.74 ± 0.470 ^a
	BaP	2.095 ± 0.151 ^b	5.316 ± 0.319 ^b	8.436 ± 1.142 ^a	13.11 ± 0.685 ^a
	BaP+Ns	2.053 ± 0.170 ^b	5.328 ± 0.508 ^b	8.146 ± 0.803 ^a	12.60 ± 0.965 ^a
Pulmonary index* Mean ×10 ²	Control	0.884 ± 0.010 ^a	0.808 ± 0.045 ^a	0.777 ± 0.031 ^a	0.622 ± 0.037 ^a
	Ns	0.914 ± 0.023 ^a	0.804 ± 0.027 ^a	0.783 ± 0.023 ^a	0.639 ± 0.015 ^{ab}
	BaP	1.395 ± 0.048 ^c	1.240 ± 0.084 ^b	0.998 ± 0.121 ^b	0.708 ± 0.051 ^b
	BaP+Ns	1.287 ± 0.053 ^b	1.136 ± 0.090 ^b	0.882 ± 0.051 ^{ab}	0.653 ± 0.040 ^{ab}

^{a, b, c} Values bearing similar superscript/s within the column do not differ at p < 0.05

* Pulmonary index: pulmonary weight (g)/body weight (g) (PWg/BWg) × 100

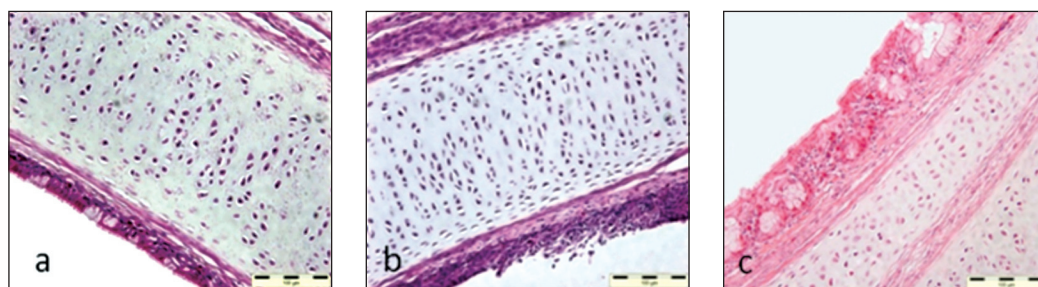


Fig. 1: Photomicrographs of the trachea of chickens necropsied at 21 days p.i (a) control group showing normal epithelium and lamina propria. (b) BaP group that is heavily infiltrated by mononuclear cells (predominantly lymphocytes and macrophages) in the lamina propria and exhibited denudation of ciliated epithelium. (c) BaP+Ns group showed reduction in severity as revealed by normal epithelium with slight thickening of the mucosa, and there is a mild infiltration by mononuclear cells in the lamina propria

whereas inter-parabronchial vascular congestion also revealed compactness with minimal air space (Fig. 2b). In that instance, the BaP+Ns was able to reduce these changes after 14 days (Fig. 1c, 2c).

In the present study, the histopathological results revealed that the i.t. administration of BaP was able to trigger a network of inflammatory responses (Slauson, 1982; Kontoni *et al.*, 1999) and induced migration of leukocytes into the respiratory tract. These leukocytes were probably mobilized in response to the damage which was inflicted either by the BaP itself or its reactive

intermediate compounds onto the lung epithelial surface (Vrzal *et al.*, 2004). The accumulation of leukocytes in the tissue induces tissue injury was through the production and release of reactive oxygen metabolites and cytotoxic proteins (e.g. proteases, myeloperoxidase, lactoferrin) into extracellular fluid (Kettle and Winterbourn, 1994).

Thus, the consumption of Ns leads to less damage seen in the treated group receiving Ns. The Ns group shows a better performance, less production of heterophils and macrophages compared to the BaP alone. Likewise, the

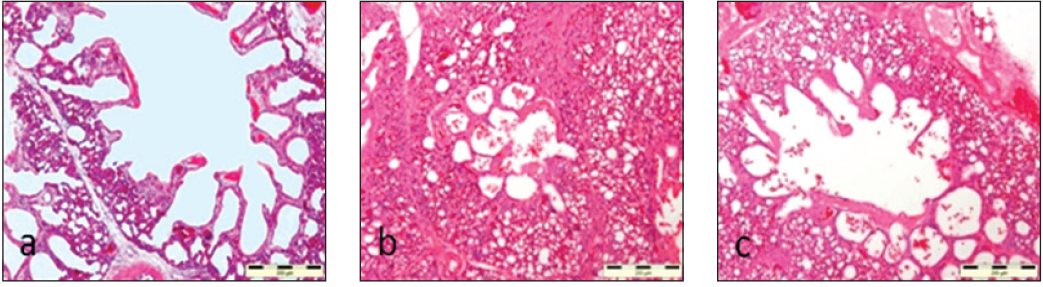


Fig. 2: Photomicrographs of the lung of chickens necropsied at 21 days p.i; (a) control group with normal atria, atrial muscles, infundibula, interparabronchial septae and inter-parabronchial vessels. Note that most areas contained ample air spaces that were devoid of inflammatory cells. (b) BaP group with infiltration by polymorphonuclear and mononuclear cells in the parabronchi of the lung, especially around the blood vessel also revealed compactness with minimal air space due to this heavy infiltration and interparabronchial vascular congestion. (c) BaP+Ns group showed reduction in severity revealed by more air space and milder mononuclear infiltration (H&E)

reversal or alleviation of toxic effects of BaP by Ns is attributed to the pharmacological properties existing in this particular herb.

In conclusion, these data, together with the histological findings suggests that i.t BaP induced oxidative inflammatory injuries in the tissues. Although the effect may be transient owing to the half-life of BaP, it is sufficient to lead to disastrous results if an infection sets in during this period. Attenuating the adverse effects of BaP can be achieved by treatment with Ns harnessing their potent antioxidant role, immune-modulation and their anti-inflammatory action.

REFERENCES

- Ali, B.H. and Blunden, G. (2003). Pharmacological and toxicological properties of *Nigella sativa*. *Phytotherapy Research*, 17, 299-305.
- Ashayerizadeh, O., Dastar, B., Shargh, M.S., Ashayerizadeh, A., Rahmatnejad, E. and Hossaini, S.M. (2009). Use of garlic (*Allium sativum*), black cumin seeds (*Nigella sativa* L.) and wild mint (*Mentha longifolia*) in broiler chickens diets. *Journal of Animal and Veterinary Advances*, 8, 1860-1863.
- Bailey, S., Zidell, R. and Perry, R. (2004). Relationships between organ weight and body/brain weight in the rat: What is the best analytical endpoint? *Toxicologic Pathology*, 32, 448-466.
- Brown, R., Brain, J. and Wang, N. (1997). The avian respiratory system: A unique model for studies of respiratory toxicosis and for monitoring air quality. *Environmental Health Perspectives*, 105, 188-200.
- Castellano, A., Cancio, J., Alemán, P. and Rodríguez, J. (2003). Polycyclic aromatic hydrocarbons in ambient air particles in the city of Las Palmas de Gran Canaria. *Environment International*, 29, 475-480.
- Kettle, A.J. and Winterbourn, C.C. (1994). Superoxide-dependent hydroxylation by myeloperoxidase. *The Journal of Biological Chemistry*, 269, 17146-17151.
- Kontoni, N., Hashimoto, H., Sessler, D., Yasuda, T., Ebina, T., Muraoka, M. and Mastsuki, A. (1999). Expression of genes for pro-inflammatory cytokines in alveolar macrophages during propofol and isoflurane anesthesia. *Anesthesia and Analgesia*, 89, 1250-1256.
- Latif, I.K., Karim, A.J., Zuki, A.B.Z., Zamri-Saad, M., Niu, J.P. and Noordin, M.M. (2009). Respiratory macrophage activity and pulmonary morphology following exposure to benzo(a)pyrene in broilers. *Online Journal of Veterinary Research*, 13, 128-135.

- Latif, I.K., Karim, A.J., Zuki, A.B.Z., Zamri-Saad, M., Niu, J.P. and Noordin, M.M. (2010). Pulmonary modulation of benzo[a]pyrene-induced hemato and hepatotoxicity in broilers. *Poultry Science*, 89, 1379-1388.
- Ramadan, M.F. (2007). Nutritional value, functional properties and nutraceutical applications of black cumin (*Nigella sativa* L.). *International Journal of Food Science and Technology*, 42, 1208-1218.
- Salem, M.L. (2005). Immunomodulatory and therapeutic properties of the *Nigella sativa* L. seed. *International Immunopharmacology*, 5, 1749-1770.
- Sellers, R.S., Morton, D., Michael, B., Roome, N., Johnson, J., Yano, B., Perry, R. and Schafer, K. (2007). Society of toxicologic pathology position paper: Organ weight recommendations for toxicology studies. *Toxicologic Pathology*, 35, 751-755.
- Slauson, D. (1982). The mediation of pulmonary inflammatory injury. *Advances in Veterinary Science and Comparative Medicine*, 26, 99-153.
- Sun, J., Wolff, R. and Kanapilly, G. (1982). Deposition, retention, and biological fate of inhaled benzo[a]pyrene adsorbed onto ultrafine particles and as a pure aerosol. *Toxicology and Applied Pharmacology*, 65, 231-244.
- Toth, T. (2000). Nonspecific cellular defense of the avian respiratory system: A review. *Developmental and Comparative Immunology*, 24, 121-139.
- Vrzal, R., Ulrichová, J. and Dvořák, Z. (2004). Aromatic hydrocarbon receptor status in the metabolism of xenobiotics under normal and pathophysiological conditions. *Biomedical Papers of the Medical Faculty of the University Palacký, Olomouc, Czechoslovakia Republic*, 148, 3-10.