

Effects of Image Processing Techniques on Mammographic Phantom Images: A Pilot Study

Mostafa Langarizadeh^{1*}, Rozi Mahmud¹, Abd. Rahman Ramli², Suhaimi Napis³,
Mohammad Reza Beikzadeh⁴ and Wan Eny Zarina Wan Abdul Rahman⁵

¹Faculty of Medicine and Health Sciences,

²Faculty of Engineering,

³Information and Communication Development Centre (iDEC),

Universiti Putra Malaysia,

43400 UPM, Serdang, Selangor, Malaysia

⁴MIMOS BHD, Malaysia

⁵Faculty of Mathematics and Quantitative Research, UiTM, Malaysia

*E-mail: langarizadeh2001@yahoo.com

ABSTRACT

Breast cancer is one of the most important diseases among females. According to the Malaysian Oncological Society (Wahid, 2007), about 4% of women who are 40 years old and above are suffering from breast cancer. Masses and microcalcifications are two important signs for breast cancer diagnosis on mammography. In this research, the effects of different image processing techniques which include enhancement, restoration, segmentation, and hybrid methods on phantom images were studied. Three different phantom images, which were obtained at 25kv (63.2 MAS), 28kv (29.8 MAS) and 35kv (9.5 MAS), were manipulated using image processing methods. The images were scored by two expert radiologists and the results were compared to explore any significant improvements. Meanwhile, the Wilcoxon Rank test was used to compare the quality of the manipulated images with the original one ($\alpha=0.05$). Each image processing method was found to be effective on some particular criteria for image quality. Some methods were effective on just one criterion while some others were effective on a few criteria. The statistical test showed that there was an average improvement of 41 percent when the images were manipulated using the histogram modification methods. It could be concluded that different image processing methods have different effects on phantom images which generally improve radiologists' visualization. The results confirm that the histogram stretching and histogram equalization methods lead to higher improvement in image quality as compared to the original image ($p < 0.05$).

Keywords: Image processing, enhancement, mammogram, breast phantom

INTRODUCTION

Cancer is one of the most important causes of death around the world. In USA, the second cause of death is cancer (American Cancer Society, 2006). Cancer is not limited to a specific gender or a group of people. It can involve anybody and no one is spared. In USA, one out of two men and one out of three women have some forms of cancer (American Cancer Society, 2006; World Health Organization, 2008).

World Health Organization reported that in 2005, cancer caused 7.6 million deaths and more than 70% of these deaths occurred in non-rich countries. It is expected that deaths due to cancer would increase up to nine million in 2015 and 11.4 million in 2030 (World Health Organization, 2008).

Received: 5 November 2009

Accepted: 22 March 2010

*Corresponding Author

In the women population, breast cancer is one of the most important diseases (Cheng and Xu, 2002). It was reported that 8% of the women population in the USA and 5% in the UK have breast cancer (Cancer Help, 2002; Cheng and Xu, 2002; Wahid, 2007). According to the Malaysian Oncological Society, about 4% of Malaysian women have breast cancer (Elm, 2005; Wahid, 2007). This malignancy was the 10th cause of hospitalization and 3rd cause of deaths in Malaysia in 2006 (Ministry of Health, 2006).

Masses and microcalcifications are two important signs for breast cancer diagnosis on mammograms. Mass detection is more difficult than microcalcification because the earlier may have almost the same density as normal breast tissue and they have different shapes and possibly ill-defined boundaries than the latter (Cheng and Xu, 2002; Kang *et al.*, 2006).

Phantom refers to a test object that is used to simulate radiographic characteristics of compressed tissue and contains components that are radio-graphically model aspects of breast disease and cancer (Collectible, 2008). The mammographic phantom was designed to simulate x-ray attenuation of 4.2 cm compressed human breast comprising of 50% adipose and 50% glandular tissue. The test objects of different sizes, shapes and densities are embedded in a wax insert, which is enclosed in an acrylic base. These test objects consist of five circles which represent masses, six lines which represent fibrils and there are five groups of specks (micro-calcifications).

Cheng and Xu (2002) argued that “(1) low-contrast of mammographic images, (2) hard to read masses in mammogram, (3) the general variation of the intensities of the masses such that radiopaque mass with high-density and radiolucent mass with low-density in comparison with the background”. These issues are the basis for image manipulation to increase enhancement and easier detection of the signs of breast cancer. He further stated that an important stage in low level image processing is pre-processing. He concluded that histogram modification is one of the methods used for image enhancement. However, Computer Assisted Diagnosis (CAD) can increase the accuracy of cancer detection, and hopefully to differentiate lesions which are benign and malignant (Cheng and Xu, 2002).

Singh and Bovis (2005) compared different enhancement methods to improve the quality of mammogram. They used different techniques, such as the following:

1. Histogram equation (HISTEQ)
2. Adaptive Contrast Enhancement (ACE)
3. Density Weighted Contrast Enhancement (DWCE)
4. Adaptive Contrast Enhancement based on Local Entropy (ACELE)
5. Adaptive Contrast Enhancement based on Fractal Dimension (ACEFD)

The researchers applied these techniques on 200 mammograms which had been extracted from a screening database. Based on the results of their research, ACE and ACELE methods could not improve the contrast of the target area against its background. Although the ACEFD could not obtain a good enhancement score for contrast enhancement, it could distinguish between the target and background. The DWCE method has better effect, and fuzzy even have better contrast enhancement of the background. HISTEQ has a clear enhancement on the target against its background.

Meanwhile, other researchers have suggested using texture, segmentation or wavelet methods. Li *et al.* (2001) suggest a new morphological enhancement algorithm. They tested this method on 200 mammograms consisting of 50 normal and 150 abnormal images which had been confirmed by biopsy. The results showed that the suggested method has effects in the suspected mass patterns and reduced noises, as well as removing background noises. The researchers further claimed that using this method twice could be effective on dense mammograms and useful to remove fibroglandular background.

Based on other research carried out in Malaysia, different wavelet filters were applied to enhance the mammograms which had been obtained from a group of Malaysian women. The investigators used 35 images that were derived from the 3 main races in Malaysia, namely, Malay, Chinese, and Indians (Al-qdah *et al.*, 2003). These images were taken from different breast density categories. The researchers further applied three different wavelet methods (DB4, SYM4, and COIF2) and concluded that the DB4 method is the best technique, particularly to detect microcalcifications (Al-qdah *et al.*, 2003); however, no exact report has been given on the improvement rate of this particular technique.

The main purposes of this paper are to study the effects of different image processing techniques on phantom standard images and to identify more useful and helpful method for a better image visualization and thus increase the level of sensitivity and specificity to detect abnormalities on digital mammogram images.

METHODS AND MATERIALS

Three different phantom images, which had been produced using 25kv (63.2 MAS), 28kv (29.8 MAS), and 35kv (9.5 MAS), were collected from the National Cancer Society of Malaysia (NCSM) and used in this research (*Fig. 1*).




Fig. 1: Original phantom images, (a) 25kV, (b) 28kV, (c) 35kV

As clearly shown in *Fig. 1*, there is a very large unnecessary area (which does not have any information) in the original images. All these areas were cropped to make processing faster. The images were then resized (256 by 256 pixels as in *Fig. 2*), while different image processing methods, such as histogram equation, border slicing, histogram stretching, median filter, gray map, wavelet, sharpening, and some hybrid methods, were applied on these phantom images.

The manipulated images were scored by two expert radiologists from the Imaging Department, UPM and Hospital Serdang, and the results were analyzed using SPSS version 15. Meanwhile, the Wilcoxon ranked test was used to study the improvement in the quality of the images.




Fig. 2: Original resized phantom images: (a) 25kV, (b) 28kV, (c) 35kV

“The present criteria for the number of objects to pass the ACR Mammography Accreditation are the minimum of the four largest fibrils, three largest speck groups, and the three largest masses” (Collectible, 2008). The scoring criteria are shown in Table 1. The total score for a good image quality should be more than 10. All the procedures are summarized in *Fig. 3*.

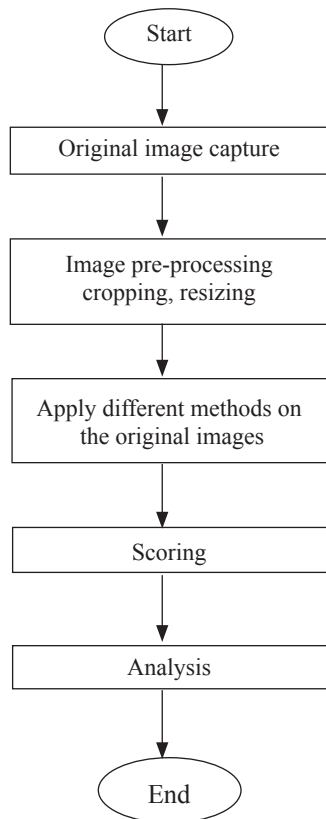


Fig. 3: Flowchart of the research material

TABLE 1
Phantom minimum requirements for image quality

CRITERIA	FIBRIL	SPECKS	MASS
MIN. REQUIREMENT	4	3	3

RESULTS

The manipulated images having very poor quality were excluded from the study. Many of the methods have caused artefacts on the images. This could be harmful because it could cause image degradation (not clear). In the original image of 25kv (Table 2), four fibrils, one speck and four masses were seen. As there were just four fibrils in the phantom images of the present study, it is not surprising that there was no improvement in this criterion after manipulation. Only one speck could be seen in the original image. Based on the results of this study, the number of specks which observed in the image of 25kv were improved using histogram equation (with a gray level of 153), histogram stretch, filter + histogram stretch, histogram equation +border slicing, gray map (with gray level of 102) +border slicing, and sharpening. The authors found that many of the methods could increase the number of masses that were seen in the image. These include histogram equation (with gray level of 51, 102, 153, 204, 255), histogram stretch, filter + histogram, filter +histogram equation, filter + gray map (with gray level of 102, 153, 204, 255), histogram equation (with gray level of 51, 204) + border slicing, and histogram equation + wavelet. The improvement for each method used is as shown in Table 2.

TABLE 2
Phantom 25kv image improvement

Criteria		Fibril	Specks	Mass	Total	Artifact	Quality percent	Quality improvement %
Method								
Original image		4	1	4	9	0	81.82	0
	51	4	1	5	10	1	90.91	9.09
Histogram	102	4	1	5	10	1	90.91	9.09
Equation	153	4	2	5	11	1	100	18.18
	204	4	1	5	10	1	90.91	9.09
	255	4	1	5	10	1	90.91	9.09
Histogram stretch		4	2	5	11	0	100	18.18
Filter + Histogram		4	2	5	11	1	100	18.18
	51	4	1	5	10	1	90.91	9.09
Filter	102	4	1	5	10	1	90.91	9.09
+Histogram	153	4	1	5	10	1	90.91	9.09
Equation	204	4	1	5	10	1	90.91	9.09
	255	4	1	5	10	1	90.91	9.09
Filter + Gray Map	204	4	1	5	10	0	90.91	9.09
	102	4	2	5	11	0	100	18.18
Gray Map	153	3	2	5	10	0	90.91	9.09
	204	4	2	5	11	0	100	18.18
	255	4	2	5	11	0	100	18.18
	51	4	2	5	11	1	100	18.18
Histogram	102	4	2	4	10	1	90.91	9.09
Equation +	153	4	2	4	10	1	90.91	9.09
Border	204	4	2	5	11	1	100	18.18
	255	4	2	4	10	1	90.91	9.09
Gray Map + Border	102	4	2	4	10	1	90.91	9.09
Histogram	153	4	1	5	10	1	90.91	9.09
Equation +	255	3	2	5	10	1	90.91	9.09
Wavelet		4	2	4	10	0	90.91	9.09
Sharpening		4	2	4	10	0	90.91	9.09

In the original image of 28kv (Table 3), two fibrils, two speck and four masses were seen. The methods which gave a better visualization of the fibrils were histogram equation (with gray level of 255), filter + histogram equation (with gray level of 51, 153, 204), and histogram equation (with gray level of 51, 102, 153, and 204) + border slicing. Nonetheless, none of the methods could increase the number of specks that were observed in the manipulated images as compared to the original one. Many manipulation methods have been shown to increase the visualization of the masses, and these include histogram equation (with gray level of 51, 102, 153, 204, 255), histogram stretch, filter + histogram, filter + histogram equation, filter + gray map (with gray level of 102, 153, 255), gray map (with gray level of 102, 153, 204, 255), histogram equation (with gray level of 51, 102, 153, 204, 255) + border slicing, and histogram equation + wavelet. Table 3 shows the experimental data and percentages of improvement.

TABLE 3
Phantom 28kv image improvement

Criteria		Fibril	Specks	Mass	Total	Artifact	Quality percent	Quality improvement %
Method								
Original image		2	2	4	8	0	72.73	0
Histogram Equation	51	3	2	5	10	1	90.91	18.18
	102	3	2	5	10	1	90.91	18.18
	153	3	2	5	10	1	90.91	18.18
	204	3	2	5	10	1	90.91	18.18
	255	4	2	5	11	1	100	27.27
Histogram stretch		3	2	5	10	1	90.91	18.18
Filter + Histogram		3	2	5	10	1	90.91	18.18
Filter + Histogram Equation	51	4	2	5	11	1	100	27.27
	102	3	1	5	9	1	81.82	9.09
	153	4	2	5	11	1	100	27.27
	204	4	1	5	10	1	90.91	18.18
	255	3	2	5	10	1	90.91	18.18
Gray Map	153	2	2	5	9	0	81.82	9.09
	204	3	1	5	9	0	81.82	9.09
	51	4	2	5	11	1	100	27.27
Histogram Equation + Border	102	4	2	5	11	1	100	27.27
	153	4	2	5	11	1	100	27.27
	204	4	2	5	11	1	100	27.27
	255	3	2	5	10	1	90.91	18.18
	Gray Map + Border	102	3	2	4	9	0	81.82
Histogram Equation + Wavelet	51	2	2	5	9	1	81.82	9.09
	102	2	2	5	9	1	81.82	9.09
	153	3	2	5	10	1	90.91	18.18
	204	2	2	5	9	1	81.82	9.09
	255	2	2	5	9	1	81.82	9.09

In the original image of 35kv (Table 4), zero fibrils, zero specks, and four masses were also observed. All the manipulation methods have been found to improve the visualization of the fibrils, except for border slicing, filter + border slicing, filter + gray map (with gray level of 51 and 102), gray map (with gray level of 51), gray map (with gray level of 51, 153, 204 and 255) + border slicing, wavelet, filter + wavelet, border slicing + wavelet, gray map (with gray level of 51, 102, 153, 204, 255), and sharpening. As for the original image, no specks were detected. All the manipulation methods improved the number of specks detected, except for border slicing, median filter, filter + border slicing, filter + histogram equation (with gray level of 51, 102, 153, 255), filter + gray map, gray map (with gray level of 51, 102, 255), gray map (with gray level of 51, 153, 204, 255) + border, wavelet, filter + wavelet, border slicing + wavelet, gray map + wavelet.

Many manipulation methods could increase the number of masses that have been observed in the original image except border slicing, median filter, filter + border, filter + gray map, gray map (with gray level of 51, 102, 255), gray map (with gray level of 51, 204, 255) + border slicing, wavelet, filter + wavelet, border slicing + wavelet, gray map + Wavelet. The percentages of the improvement are shown in Table 4.

DISCUSSION

The results have shown that some of the pre-processing techniques as well as median filter, histogram stretching and histogram equation are more effective for mammogram phantoms ($p < 0.05$). In addition, in 25kv and 28kv images, many techniques such as sharpening and gray map may have more effects on the phantom image quality; however, the author found that none of the methods had improved the quality of image for all the criteria. In addition, the authors found that the median filter was effective since it reduced the noise and produced a better visualization for radiologists. This technique changes all the pixels values based on the median of each pixel neighbours. On the other hand, the histogram stretching tries to reform the pixels between the minimum of 0 and the maximum of 255. It means that the contrast between the different parts of the image will be increased. In addition, this particular technique also produces higher contrast in mammographic phantom images and gives a better visualization for radiologists and consequently a better detection of objects.

CONCLUSIONS

With the various image processing methods, the ideal image quality and resolution present a challenge to radiologists to examine mammogram images, analogue, as well as digital. The research aims to explore the effects on the mammographic phantom using different image processing methods. The ideal contrast and axial resolution of image were selected to represent the most effective methods. The effects of the selected methods on the actual mammographic images were explored for further study. In particular, the image processing method has different effects on the phantom images and it gave a better visualization for the radiologists for early detection of masses and classifications. It explores the positive effects of image processing method; however, some methods could not improve all the image quality criteria. Thus, the histogram stretching and histogram equalization were the most effective methods on mammographic phantom images, especially on 35kv ($p < 0.05$).

TABLE 4
Phantom 35kv image improvement

Criteria		Fibril	Specks	Mass	Total	Artifact	Quality percent	Quality improvement %
Method								
Original image		0	0	2	2	0	18.18	0
Histogram Equation	51	3	2	5	10	1	90.91	72.73
	102	4	1	4	9	1	81.82	63.64
	153	3	2	5	10	1	90.91	72.73
	204	3	2	5	10	1	90.91	72.73
	255	3	2	5	10	1	90.91	72.73
Histogram stretch		3	1	5	9	1	81.82	63.64
Median Filter		1	0	2	3	0	27.27	9.09
Filter + Histogram		3	2	5	10	1	90.91	72.73
Filter + Histogram Equation	51	2	0	4	6	1	54.55	36.37
	102	2	0	4	6	1	54.55	36.37
	153	3	0	5	8	1	72.73	54.55
	204	3	1	4	8	1	72.73	54.55
	255	3	0	4	7	1	63.64	45.46
Filter + Gray Map	153	2	0	2	4	0	36.36	18.18
	204	2	0	1	3	0	27.27	9.09
	255	2	0	2	4	0	36.36	18.18
Gray Map	102	1	0	2	3	1	27.27	9.09
	153	1	1	3	5	0	45.45	27.27
	204	3	1	5	9	0	81.82	63.64
	255	2	0	2	4	0	36.36	18.18
	51	3	1	5	9	1	81.82	63.64
Histogram Equation + Border	102	3	1	4	8	1	72.73	54.55
	153	4	1	4	9	1	81.82	63.64
	204	3	1	4	8	1	72.73	54.55
	255	3	1	5	9	1	81.82	63.64
Gray Map + Border	102	1	1	3	5	0	45.45	27.27
	153	0	0	3	3	0	27.27	9.09
Histogram Equation + Wavelet	51	3	2	5	10	1	90.91	72.73
	102	2	2	4	8	1	72.73	54.55
	153	2	2	5	9	1	81.82	63.64
	204	2	2	5	9	1	81.82	63.64
	255	3	2	5	10	1	90.91	72.73
Sharpening		0	1	3	4	0	36.36	18.18

LIMITATIONS

1. Phantom has no breast parenchyma background as compared to human breast tissues. Therefore, the real representation of cancer detection is not challenged in phantom images.
2. Cropped images are small sized. Larger mammogram images may take time to referent the results.
3. More radiologists should score the images.

REFERENCES

- Al-Qdah, M., Ramli, A. R., Wirza, R., Mahmud, R. and Taysir, M. (2003). Detection of calcifications in mammography using wavelets. Paper presented at the *Student Conference on Research and Development*.
- American Cancer Society. (2006). What is Cancer? Retrieved on February 6, 2008 from http://www.cancer.org/docroot/CRI/content/CRI_2_4_1x_What_Is_Cancer.asp.
- Cancer Help. (2002). The mammogram. Retrieved on February 6, 2008 from www.cancerhelp.org.uk.
- Cheng, H. D. and Xu, H. (2002). A novel fuzzy logic approach to mammogram contrast enhancement. *Information Sciences*, 148(1-4), 167-184.
- Collectible, Q. A. (2008). Mammography phantom image quality evaluation. Paper presented at the *Conference of Radiation Control Program Directors*, Frankfurt.
- Elm, H. (2005). Accreditation in Mammography – Pain or Gain? *Biomedical Imaging and Intervention Journal*, 1(1), e6-18.
- Kang, H. K., Ro, Y. M. and Kim, S. M. (2006). A microcalcification detection using adaptive contrast enhancement on wavelet transform and neural network. *IEICE Transactions on Information and Systems*, E89-D(3), 1280-1287.
- Li, H., Wang, Y., Liu, K. J. R., Lo, S. C. B. and Freedman, M. T. (2001). Computerized radiographic mass detection. i. lesion site selection by morphological enhancement and contextual segmentation. *IEEE Transactions on Medical Imaging*, 20(4), 289-301.
- Ministry of Health. (2006). Health facts 2006. Retrieved on February 6, 2008 from <http://www.moh.gov.my/MohPortal/index.jsp?lang=en>.
- Singh, S. and Bovis, K. (2005). An evaluation of contrast enhancement techniques for mammographic breast masses. *IEEE Transactions on Information Technology in Biomedicine*, 9(1), 109-119.
- Wahid, M. I. (2007). Breast cancer. Retrieved on February 6, 2008 from www.malaysiaoncology.org.
- World Health Organization. (2008). Cancer. Retrieved on February 6, 2008 from <http://www.who.int/cancer/en/>.