

Case Study

Whole Body Imaging Using 18-Fluorine Fluorodeoxyglucose (¹⁸F-FDG) Positron Emission Tomography/Computed Tomography (PET/CT) with or without Contrast Enhanced Computed Tomography (CT) in Diagnosing Arteritis

¹N Abdul Jalil, ²AR Noraini, ³C Rossetti, ⁴PLind & ⁴E Kresnik

¹Nuclear Imaging Unit, Faculty of Medicine and Health Sciences
Universiti Putra Malaysia, 43400 UPM Serdang, Selangor, Malaysia

²Radiology Department, Hospital Serdang, Serdang, Selangor, Malaysia

³Department of Nuclear Medicine, Ospedale Niguarda, Milan, Italy

⁴Department of Endocrinology and PET/CT Centre, Teaching Department
University of Innsbruck, State Hospital Klagenfurt, Austria

ABSTRACT

Introduction: Takayasu's Arteritis and Horton's Arteritis are two rare cases of auto-immune complex diseases resulting in sterile inflammatory reactions affecting the wall of large and medium sized arteries. Various radiological and interventional methods employed are inconclusive and become diagnostic only when complications begin to set in. The new non-invasive hybrid Positron Emission Tomography Computed Tomography (PET/CT) using 18Fluorine-Fluorodeoxyglucose (¹⁸F-FDG) imaging technique could detect arteritis in an early clinical stage when routine conventional cross-sectional imaging was inconclusive. **Method:** Two cases from Klagenfurt Hospital, Austria and Milan General Hospital, Italy were compared with image acquisition being done in the respective hospitals. In Klagenfurt, PET/CT image acquisition was performed using intravenous contrast administration and in Milan, CT parameters were used as attenuation correction and anatomical correlation of PET images. **Results:** CT performed using both methods, with or without iodinated contrast media, were useful in detecting arteritis. **Conclusion:** It is concluded that PET/CT aside from being a useful tool in cancer imaging, is also useful for pyrexia of unknown origin. PET/CT should be employed early in managing this clinical condition where arteritis is a possible diagnosis.

Keywords: Attenuation correction, auto-immune complex disease, Horton's Arteritis, low dose CT, Takayasu's Arteritis

INTRODUCTION

A 68-year-old Caucasian having a known hypertension and coronary heart disease from Klagenfurt Hospital and on regular treatment, presented with non-specific symptoms with low grade fever and fatigue for the past several weeks.

*Corresponding author: Assoc Prof Dr Abdul Jalil Nordin
Email: drimaging@yahoo.com

Another 80-year-old Caucasian patient from Milan presented with vague generalised malaise and moderate fever for the past few weeks.

In both patients, the Erythrocyte Sedimentation Rate (ESR) and C-Reactive Proteins (CRP) were found to be elevated. Conventional methods employed including Computed Tomography (CT) and Magnetic Resonance Imaging (MRI) suggested non-conclusive findings. Combined PET/CT examination using 18F-FDG was done in both cases to detect any occult foci of infection.

METHODS

Protocol A

PET/CT performed in the Department of Nuclear Medicine and PET/CT Centre Klagenfurt Hospital, Klagenfurt, Austria using Integrated PET/CT system (Biograph®, LSO, Siemens MS) combined a third-generation dual slice spiral CT with a dedicated full-ring lutetium oxyorthosilicate (LSO) PET scanner.

18F-FDG intravenous injection (6 MBq/kg) was given after overnight fasting. After complete resting, examination started with CT scannogram followed by axial CT image acquisition using the following parameters: 5 mm slices in spiral mode with 13.6 table increment with the exposure factors 100 mAs and 130 kV. In the CT protocol, an intravenous contrast agent was administered using 140 mls of Visipaque® 270. While the patient was still immobilised in the gantry, examination continued with PET image acquisition using the following protocol:

- 1 First acquisition was performed from the lung to the thighs in 3-dimensional mode. Second acquisition was performed for the head and neck from the upper border of the orbital region to the upper region of the lung.
- 2 Reconstruction of the emission data performed using iterative algorithm with the software Somaris/5 VA40C and stored in a 128 matrix.
- 3 CT-data were used for attenuation correction. Volume projected images (transaxial, coronal and sagittal slices) and fusion images were generated for combined interpretation by a radiologist and physician.

Protocol B

In Milan, PET/CT was performed in the Department of Nuclear Medicine using integrated PET/CT system (Biograph, Siemens) combine dual slice spiral CT with a dedicated full-ring Bismuth Germanate (BGO) crystal PET scanner. 18F-FDG PET/CT image acquisition was accomplished without intravenous contrast administration. The following protocol was used;

- 1 CT Scannogram was performed to plan the CT and PET study.
- 2 Low dose CT acquisition was performed with parameters of 2.5 mm slices, spiral mode at 50 mAs and 130 kV for anatomical correlation and attenuation correction of PET images.

Table 1: Comparison of protocols utilised by Klagenfurt Hospital (Protocol A) and Milan General Hospital (protocol B) for 18F-FDG PET/ CT image acquisition

		Protocol A	Protocol B
1	PET Crystal	LSO	BGO
2	CT slices	Dual	Dual
3	Timing	90 mins	60 mins
4	Acquisition	3 Dimensional	3 Dimensional
5	Exposure factors	100mAs 130kV	50mAs 130 kV

- 3 Immediately after CT image acquisition, the table was positioned for PET image acquisition (5 min/bed position).
- 4 Acquisition was performed from the lung to the thighs in 3-dimensional mode.
- 5 Reconstruction of the emission data was performed by using an iterative algorithm with software Somaris/5 VA40C and stored in a 128 matrix. CT-data were used for attenuation correction. Volume projected images (transaxial, coronal and sagittal slices) and fusion images were generated for interpretation. A summary of the protocols are given in Table 1.

Image Review

Visual analysis of both 18F-FDG PET/CT findings were compared using standardised viewing parameters to detect gross differences in images acquired from both institutions using two different CT protocols. Both series were viewed on Siemen's PET/CT Biograph 2 with software using Color Lock Up Table 8 bit for Grey scale and Hot Body. Window value of CT viewing parameter was fixed at grey scale mode 40C and 300W. The images were reviewed systematically at the level of mid-cardiac in axial plane and manipulated in three dimensions to view the descending aorta in sagittal and coronal planes. Images at these fixed levels were reviewed at 100% CT, 50% fused and 100% PET settings.

RESULTS

In both patients, PET and fused PET/CT images demonstrated increased metabolic activity with avid FDG uptake along the walls of the thoracic and abdominal aorta. There were also multifocal calcifications seen along the wall of the aorta. Evaluation of these abnormal increased metabolic activities along the wall of the aorta revealed high reading of Maximum Standardised Uptake Values (SUV max) of between 4 to 6 (Figures 1-3).

DISCUSSION

Routine radiological imaging methods have long been utilised by clinicians in managing clinical conditions like pyrexia of unknown origin. Morphological information in these modalities like size of tissues and organs can no longer be used as the sole expression of significant abnormalities ever since PET modality was discovered.

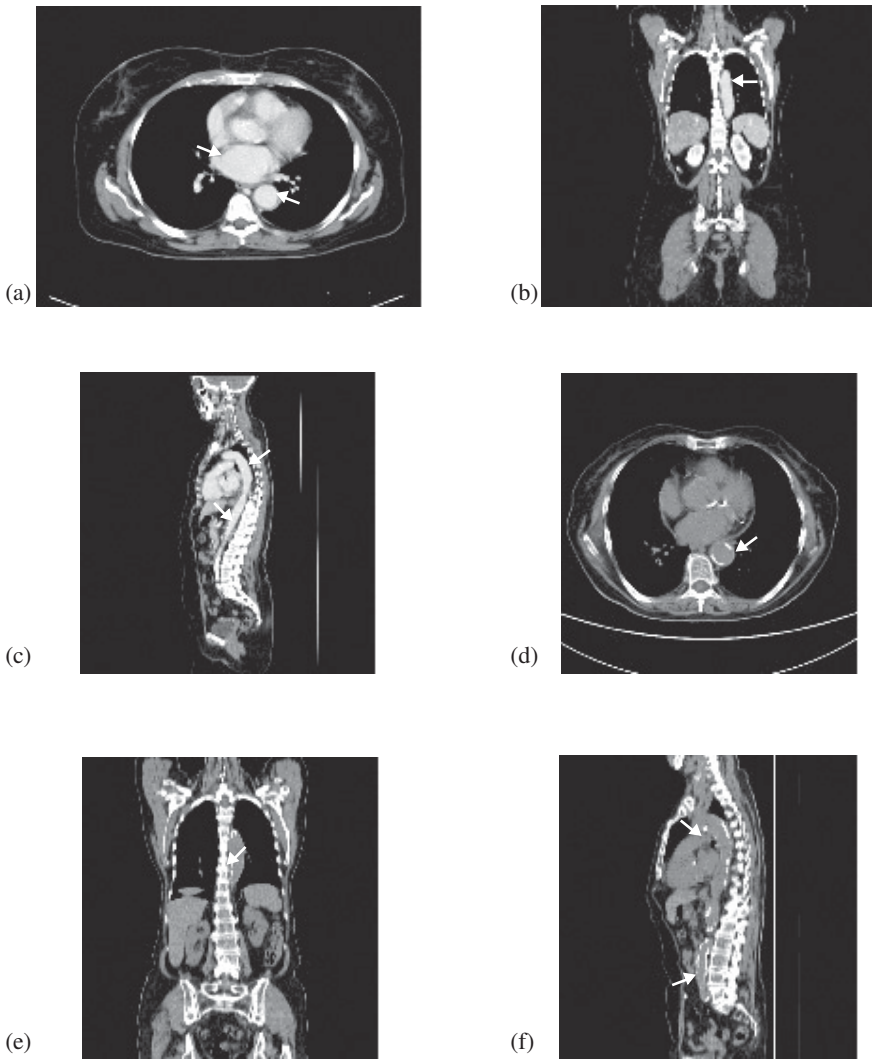


Figure 1. (a,b,c): Three-dimensional MultiPlanar Reconstructed (MPR) Computed Tomography images in axial, coronal and sagittal views. Images were acquired using intravenous contrast administration as in Protocol A. There is clear demarcation of contrast in the blood vessels (thick arrow). There is no intensity difference between the wall and the lumen of the aorta. Portions of the wall of the great vessels are irregular and thickened.
(d,e,f): Demonstrate images acquired using Protocol B where low dose CT was performed for anatomical correlation. Multiple foci of calcifications (thin arrows) can be seen along the wall of the aorta.

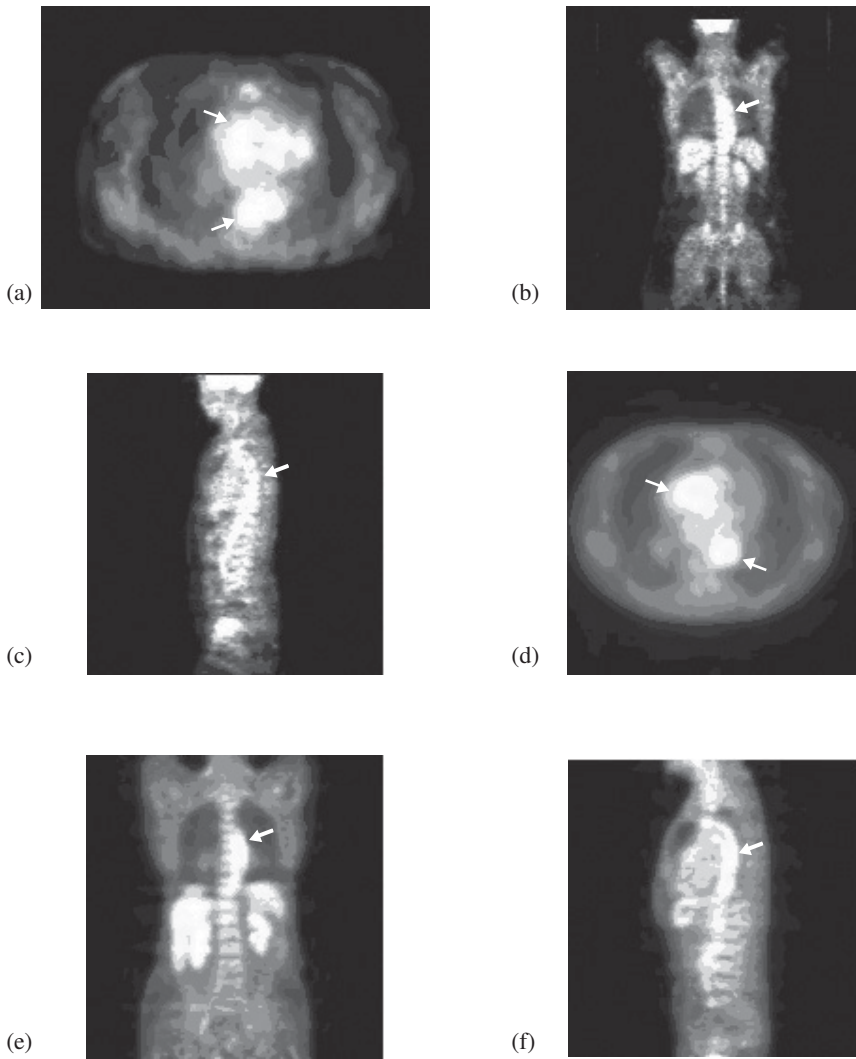


Figure 2. (a,b,c): Illustration of PET images acquired after CT image acquisition using intravenous contrast administration in Protocol A. **(d,e,f):** Protocol B where low dose CT was performed for anatomical correlation. In both, the CT parameters were used for attenuation correction of PET images. Both illustrations are in axial, coronal and sagittal planes. Both studies demonstrated 'double tract' appearance (arrows) found along the wall of the arch of aorta and descending aorta. There is overall increase of FDG uptake along the wall of aorta demonstrated in Protocol A study (**a, b** and **c**). Smoothened overall effect of images acquired using Protocol B is seen in **d, e, f**.

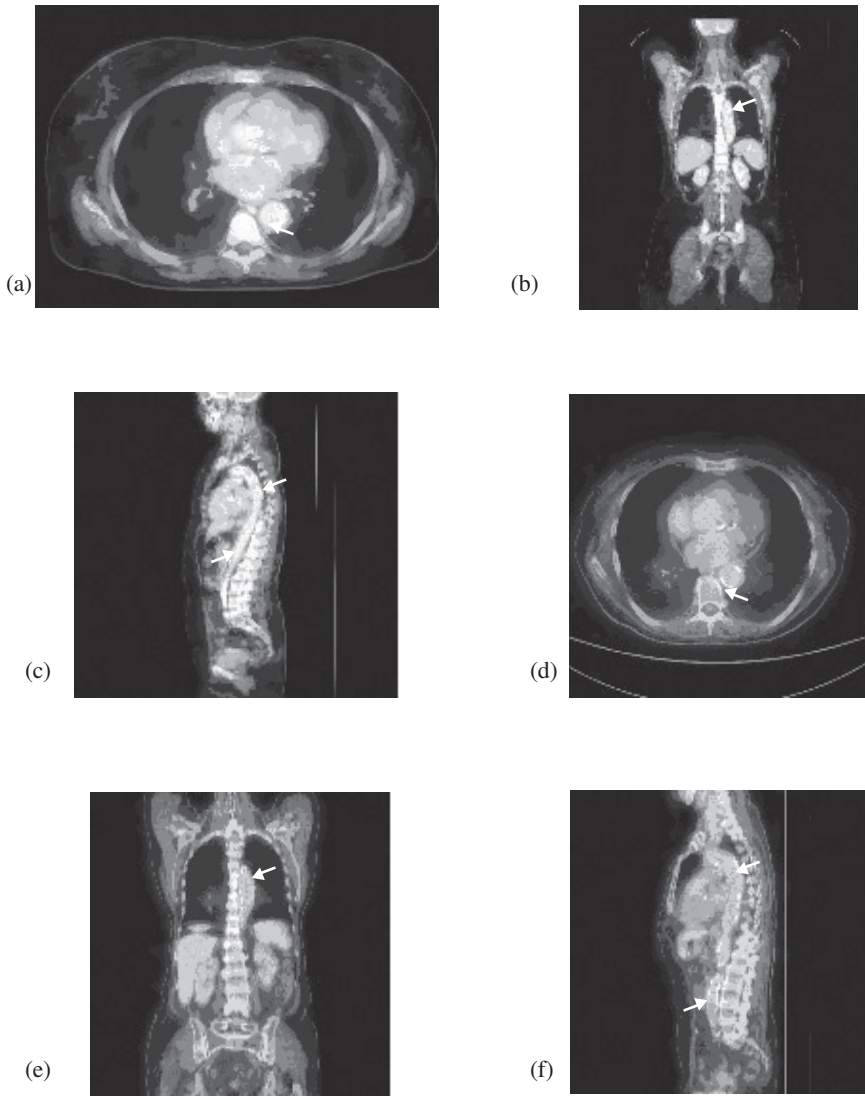


Figure 3. Illustration of fused hybrid images of PET and CT in axial, coronal and sagittal view acquired in Protocol A (a,b and c) and Protocol B (d,e and f). Multiple foci of calcifications (arrows) found along the wall of the arch of aorta and descending aorta. There is also generalised increased FDG uptake along the wall. In both, cross-correlates of two contemporaneous examinations in PET/CT further demonstrate the anatomical localisation of increased FDG accumulation (arrows).

The uptake of FDG mimicking the physiological distribution of glucose molecule is the most valuable property of this element to be utilised as an important biological marker in transporting the positron emitted radiopharmaceutical agents to different parts of the body. However, PET as a sole functional imaging is limited by its poor anatomical landmarks due to low spatial resolution. This results in inferior ability in precise localisation of pathology.

The introduction of integrated PET/CT imaging contributes significantly towards clinical impact on patients' management in terms of increased lesion detectability, localisation, and characterisation.

In our case study, interpretation of CT images without the PET component was inconclusive apart from multiple foci of calcifications seen along the wall of the arch of aorta and descending aorta. This indicator may have been the only clue leading to localised inflammatory reactions along the wall.

In addition, CT findings, with intravenous contrast injection as in Protocol A, was also inconclusive aside from irregular thickening of the aortic wall. There was no significant information gathered from this contrast enhancing imaging technique.

Therefore, in our study, non conclusive results obtained through CT scan examination was overcome with the appearance of increased metabolic activity along the wall of the aorta in PET (Figures 2 and 3). We named this appearance of linear increased metabolic activities which runs parallel to each other as the 'double tract' appearance. This description is suitable when the large vessel is affected in contrast to 'tram tract' appearance of medium and small vessels' involvement.^[1] When the images were fused in PET/CT, the abnormalities were well demonstrated and anatomically well correlated. Abnormal metabolic increases in FDG uptake along the aortic walls were not normally seen in normal subjects. Eventually, the diagnosis of both cases was confirmed through arterial biopsies.

Therefore we conclude that, CT with or without intravenous contrast injection in hybrid PET/CT imaging, for anatomical correlation and attenuation correction, are acceptable techniques. Cross-correlates of two contemporaneous examinations in this study resulted in the detection of the subtle disease entity.

Several previous reports on the use of intravenous contrast in PET/CT image acquisition stated that this technique can be employed without untoward effects on PET image quantification.^[2] Antoch *et al.*^[3] carried out a standardised scanning protocol and showed that oral and intravenous (IV) contrast materials improved CT image quality in dual-modality PET/CT imaging, resulting in increased diagnostic capability. These findings led to potential improvement of the technique. Additional diagnostic benefits of intravenous contrast in PET/CT have also been reported by Siewart *et al.*^[4] and Suh *et al.*^[5] They showed that diagnostic CT with intravenous contrast may be used for attenuation correction of PET data without affecting the standard uptake values

Both cases demonstrated increased overall appearance of FDG uptake especially, more intense uptake along the wall of the aorta as demonstrated in the study with intravenous CT contrast injection (Figures 3a, b and c) and smoothed overall effect of images acquired using protocol B without contrast (Figures 3d, e and f). The varied appearance in our cases was acceptable with no significant loss of information. However, the parameters used in

both studies are not absolute recommendations as they may vary from one vendor to another.^[6]

Finally, both patients were treated using steroid therapy and were found to be in clinical remission.

CONCLUSION

Both techniques can be employed to image cases of arteritis satisfactorily with promising end results despite minimal acceptable differences in the images displayed. Computed tomography can be performed using low dose parameters for anatomical correlation or with intravenous CT contrast enhancement as a diagnostic tool. Both techniques are fast and superior to conventional imaging methods routinely employed to diagnose sterile inflammatory arteritis. Indication for PET/CT in tumour-related cases should be expanded to include inflammatory conditions especially for use as an early diagnostic tool in patients with pyrexia of unknown origin.

ACKNOWLEDGEMENT

I am thankful to IAEA for support to this Continuous Medical Education activity. This manuscript will benefit medical professions especially those involved in Nuclear Medicine and will be a useful future reference. My appreciation to Professor Dr P. Lind and colleagues from PET/CT Centre, Klagenfurt Hospital, Austria, Professor Dr C. Rossetti from Ospedale Niguarda, Milan, Italy and other colleagues for their permission and contribution as co-authors to this article.

This results of this study were presented at *The International Scientific Session on Nuclear Medicine and Radiopharmaceutics* organised by the Russian Academy of Medical Sciences, Medical Radiological Research Centre in collaboration with International Atomic Energy Agency (IAEA) and World Nuclear University (WNU) in Obninsk, Russia from 4- 14 December 2006).

REFERENCES

- [1] Abdul Jalil N, Abdul Rahim N, Md Shalleh N, Rossetti C. 18F-FDG positron emission tomography computed tomography and the 'underground map' appearance in imaging Horton's arteritis. *Singapore Medical Journal* 2008; 49: 7.
- [2] Nakamoto Y, Bennett B Chin, Dara LK, Leo PL, Laura TM, Richard LW. Effects of nonionic intravenous contrast agents at PET/CT imaging: phantom and canine studies. *Radiology* 2003; 227: 817-824.
- [3] Antoch G, Lutz S. Freudenberg, Joerg Stattaus, Walter Jentzen, Stefan P. Mueller, Joerg F. Debatin *et al.* Whole-body positron emission tomography - CT: optimized CT using oral and IV contrast materials *AJR* 2002; 179: 1555-1560.
- [4] Siewert B, Hill TC, Raptopoulos VD. Added value of contrast enhancement for PET-CT in the management of patients with colon cancer. Program and abstracts of the Radiological Society of North America 91st Scientific Assembly and Annual Meeting, p.428. 27 Nov-2 Dec 2005. Chicago, Illinois.

- [5] Suh J, Lanham K, Chen L *et al.* The effect of intravenous CT contrast on PET image quantification. Program and abstracts of the Radiological Society of North America 91st Scientific Assembly and Annual Meeting, p. 536. 27 Nov-2 Dec 2005. Chicago, Illinois.
- [6] Reske SN, Kotzerke J. FDG-PET for clinical use: results of the 3rd German Interdisciplinary Consensus Conference, Onko-PET III, 21 July and 19 September 2000. *Eur J Nucl Med* 2001; 28: 1707 -1723.