

Case Report

Gorham's Disappearing Bone Disease: A Rare Cause of Extensive Bone Destruction

*Subapriya Suppiah,^{1, 2} Roziah Muridan³

¹Centre for Diagnostic Nuclear Imaging, Universiti Putra Malaysia, 43400 UPM Serdang, Selangor, Malaysia.

²Imaging Department, Faculty of Medicine and Health Sciences, Universiti Putra Malaysia, 43400 UPM Serdang, Selangor, Malaysia.

³Department of Biomedical Imaging, Faculty of Medicine, University Malaya, 50603 Kuala Lumpur, Malaysia.

ABSTRACT

Osteolytic disease of the bones have a myriad range of aetiology. One rare cause is Gorham's disease or disappearing bone disease. This disease is a diagnosis by exclusion using correlation made with clinical presentation, radiological findings and histopathological confirmation. Although many different therapies have been advocated, none have been successful in fully controlling this disease. We present a case that was detected in a Chinese lady using diagnostic imaging, confirmed with computed tomography guided biopsy and successfully treated with joint reconstruction using endoprosthesis.

Keywords: Gorham's disease, Disappearing bone, Osteolysis, Computed tomography

INTRODUCTION

Gorham's disappearing bone disease is a rare idiopathic disorder characterized by rapid bone destruction. An overview of this disorder was reported in 1954 by Gorham and colleagues and subsequently described by Gorham and Stout who recognised it as a syndrome in 1955. This disorder does not have any evidence of a malignant, immunologic, neuropathic, or infectious component involved in its pathophysiology. This case report aims to highlight a histologically studied case of disappearing bone disease in a Chinese woman who had the disease involving multiple joints of the lower limbs.

CASE REPORT

A 41-year-old Chinese woman, presented with a 6 months history of left knee swelling. Except for a past medical history of hypertension, she had been previously well. There was no preceding history of trauma or fever. Her left knee had become progressively swollen with limited range of movement. Her vital signs were stable. Her left knee was swollen, warm and tender. The range of movement was between 10-60 degrees of flexion. Radiograph of her knee joints showed bony destruction with sclerosis of the left tibial plateau (Figure 1a), proximal shaft of the left tibia and distal third of the left femur. Apart from minimal degenerative changes evidenced by osteophytes, the right knee joint was normal. Laboratory tests were all within normal limits. Her haemoglobin level was 14.2g/dL, white blood count $6.7 \times 10^9/L$, serum calcium 2.12mmol/L and ALP 103 IU/L. C-reactive protein levels were <0.4mg/dL and renal function test was normal. She was given analgesics and discharged home.

Unfortunately, she came back with a new complaint of recent onset right knee and right hip pain. Upon further questioning, the joint pains were not migratory in nature. She had a low grade fever but did not have any features of connective tissue disease such as rashes, deformity of her hands, etc. Nevertheless, considering she was a female, a provisional diagnosis of connective tissue disorder was entertained. Several radiological and laboratory investigations were undertaken. There was no significant abnormality noted in the pelvic x-ray (Figure 1b). However, three months later her left knee pain and right hip pain became progressively worse. Serial pelvic radiographs showed bony destruction of the head of right femur. Just within one year there was total bone resorption of the head of the right femur (Figure 1c). Her serum C-reactive protein was only slightly elevated (30.4mg/dL) and ESR was within normal

*Corresponding Author: Dr. Subapriya Suppiah
subapriya@upm.edu.my

limits. A differential diagnosis of septic arthritis due to tuberculosis was made. However, blood cultures were negative and left knee joint aspirates as well as sputum for AFB were also negative. Serum complement level of C3 and C4 were not significantly decreased to suggest an autoimmune aetiology. ANCA and ANF were within normal range.

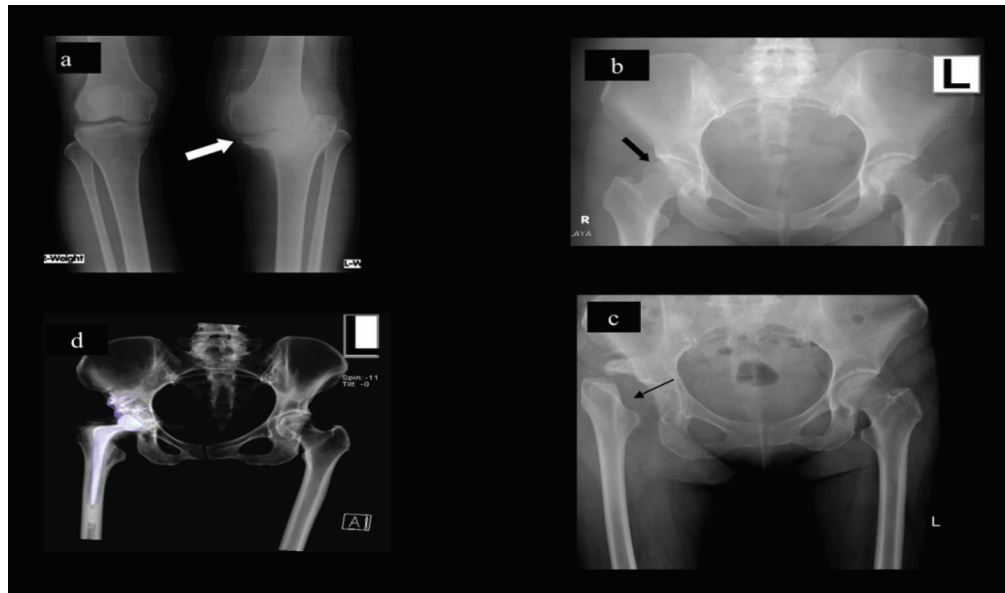


Figure 1: (a) Marked bony destruction of the left proximal tibia noted (white arrow). (b) Pelvic radiograph showing a normal head of right femur (black thick arrow). (c) The head of right femur is completely destroyed (black thin arrow) within one year of patient presenting with right hip pain. (d) Coronal MPR CT scan showing right THR metal prosthesis that had been inserted for the patient to replace the destroyed head of right femur.

As the cause of her rapid osteolysis remained unanswered, bone biopsies of the left knee and right hip were performed approximately 1 month later. Histopathological findings of the left knee biopsy were irregular trabeculae of lamellar bone with occasional intervening vascularized fibrous tissue (Figure 2a). Foci of granulation and vascular proliferation in which capillary type and thicker-walled vessels, many dilated, were seen on high powered field in the right femur specimen (Figure 2b). There were also areas of non-viable bone with intervening fibrous tissue that exhibited vascular proliferation. There was no evidence of malignancy. The pathologist concluded that in the absence of other aetiological factors, features were compatible with Disappearing Bone Disease.

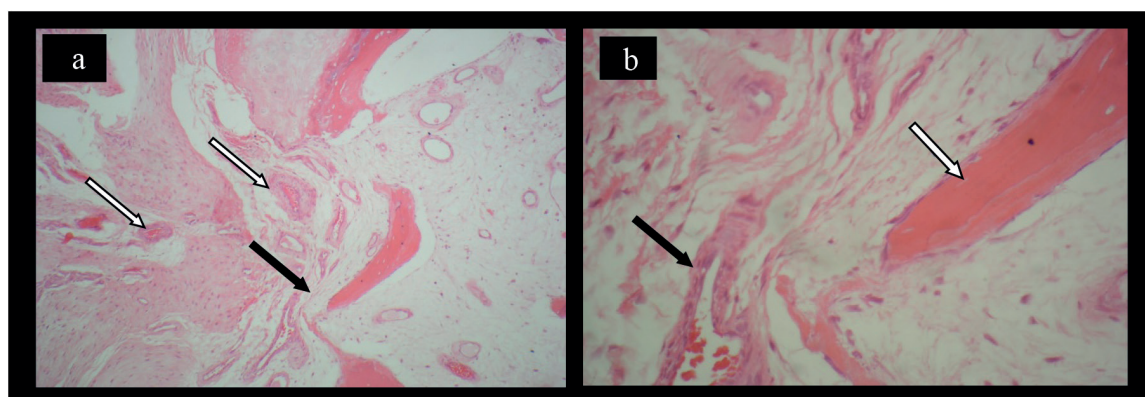


Figure 2: Histopathological findings from the bone biopsy. (a) Left tibia (b) Right hip. Foci of granulation and vascular proliferation in which capillary type and thicker-walled vessels (white arrows), many dilated, were seen. There were also areas of non-viable bone with intervening fibrous tissue (black arrows) that exhibited vascular proliferation. There was no evidence of malignancy.

Six months later, she was planned for an elective left total knee replacement (TKR) due her limited range of movement affecting her activities of daily living. Intra-operative findings were hypoplasia and deformity of the left lateral femoral condyle. There was extensive bone loss noted in the central and medial aspect of the left tibial plateau. Avulsion of the patella tendon was noted and stitched. TKR was done and she was then put on knee brace. She was able to ambulate with the aid of a walking frame. Nine months after the knee surgery, she complained of worsening right hip pain. Subsequently, a right total hip replacement (THR) was performed (Figure 1d). Approximately one month later, she was again warded for the complication of dislocated right THR. Closed manual reduction was successful in reducing the dislocation and the patient was discharged well.

DISCUSSION

Disappearing bone disease is a rare disorder manifested by massive osteolysis associated with vascular endothelial proliferation within involved bones (1). It is known by many eponyms among which include Gorham's syndrome, Gorham-Stout Syndrome, Morbus Gorham-Stout Disease, Massive Osteolysis, idiopathic massive osteolysis, progressive massive osteolysis, massive Gorham osteolysis, vanishing bone disease and phantom bone disease (2).

As of date, there are less than 200 cases reported in English literature and mostly it affects men (3). The disease may occur at any age, but is common in adolescents and young adults. There is no racial prevalence nor is there any evidence that it is hereditary. A history of occasional minor trauma can be found in many patients (4). The aetiology of this condition is unknown. Therefore, it is a disease by exclusion of other causes of osteolysis such as neuropathy, infection, tumour, trauma (Sudeck's atrophy), gout, reticuloses and scleroderma (4). As in our patient who presented with swelling, the clinical presentation of a patients suffering from vanishing bone disease includes, most frequently, pain, functional impairment and swelling of the affected region (1).

The pathophysiology of this poorly understood disease is uncertain and the stimulus causing osteolysis is unknown. Nevertheless, in all cases, there is replacement of normal bone by an aggressively expanding but non-neoplastic vascular tissue similar to a hemangioma or lymphangioma. This proliferating neovascular tissue causes massive bone osteolysis. Initially, the bone undergoes resorption, and is replaced by hypervascular fibrous connective tissue and angiomatous tissue (1). Although the exact mechanism leading to the massive bone destruction is unknown, there has been some research done that suggest interleukin-6 (IL-6) cytokine as a tumoral mediator causing the rapid progressive osteolysis of Gorham-Stout disease (6).

Histologically, involved bones show a non-malignant proliferation of thin-walled vessels. This proliferation may be capillary, sinusoidal or cavernous type. In the late stage, there is progressive dissolution of the bone leading to massive bone loss, with the osseous tissue being replaced by fibrous tissue (3).

In patients with joint involvement, such as in our patient, Charcot's arthropathy, septic arthritis and avascular necrosis should be considered as differential diagnoses. Radiological imaging and laboratory tests can help in narrowing down the diagnosis. Ultimately, in cases where the aetiology is uncertain, a bone biopsy can help shed light to make a definitive diagnosis as was done for our patient.

Most cases report a single bone involvement and multiple sites involvement is rare. Although any part of the skeleton can be affected, the disease shows a predilection for maxilla, shoulder girdle, ribs and pelvis (4). The disease is usually progressive but may eventually stabilize. Although very rare, there have been isolated cases where spontaneous regression has been noted to occur (1).

Apart from skeletal involvement, this disease can also affect the thorax, causing pleural effusion and chylothorax, which can have a fatal outcome. There have been many different treatment modalities have been employed for the management of chylothorax in patients with Gorham's disease, including pleurectomy and pleurodesis, thoracic duct ligation, and radiation therapy, interferon therapy, oral clodronate, and bleomycin (3).

In general, major treatment modalities for this phantom bone disease are surgery and radiation therapy. Agents that inhibit bone resorption (bisphosphonates, calcitonin) and radiotherapy have been empirically used for treatment (3). Surgical options include resection of the lesion and reconstruction using bone grafts or prostheses (4). Radiation therapy appears to result in a good clinical outcome with few long-term complications. Fractionated radiotherapy and interferon- α 2b are advocated as they inhibit angiogenesis and can be potentially beneficial in treating this disease (3). Several medical treatments have been advocated, including vitamin D, sodium fluoride, calcitonin, bisphosphanates, androgens, interferon, interleukins, but with little evidence of benefit (6). The disease prognosis remains unpredictable and more research is needed to identify an effective treatment for this debilitating condition.

REFERENCES

1. Nikolaou VS, Chytas D, Korres D, and Efstathopoulos N. Vanishing bone disease (Gorham-Stout syndrome): A review of a rare entity. *World J Orthop.* 2014 Nov 18; 5(5): 694–698.
2. El-Kouba G, de Araújo Santos R, Pilluski PC, Osvandré Lech, et al. *Revista Brasileira de Ortopedia (English Edition)*. Nov–Dec 2010; 45 (6); 618–622.
3. Patel DV. Gorham’s Disease or Massive Osteolysis. *Clinical Medicine and Research.* 2005. Volume 3, No.2: 65-74.
4. Baba AN, Bhat YJ, Paljor SD, et al. Gorham’s disease of femur. *Indian J Orthop.* 2011 Nov-Dec; 45(6): 565–568.
5. Devlin RD, Bone HG, Rodman GD. Interleukin-6: A potential mediator of the massive osteolysis in patients with Gorham-Stout disease. *Journal of Clinical Endocrinology and Metabolism.* 1996; 81(5): 1893-1897.
6. Yalniz E, Alicioglu B, Benlier E, Yilmaz B, Altaner S. Gorgam Stout Disease of the Humerus. *JBR–BTR*, 2008, 91: 14-17.