

Review Article

Potential of 3'-Fluoro-3' Deoxythymidine as a Cellular Proliferation Marker in PET Oncology Examination

Hishar, H.^{1*}, R. Price², Fathinul Fikri, A. S.¹, Eddie Lau, W. F.³, Assunta, C.⁴ and A. J. Nordin¹

¹Centre for Diagnostic Nuclear Imaging, Universiti Putra Malaysia, 43400 Serdang, Selangor, Malaysia

²Department of Medical Technology & Physics and RAPID PET Technologies, Sir Charles Gairdner Hospital, Western Australia, Australia

³Centre for Cancer Imaging, Molecular Imaging and Targeted Therapeutics Laboratory the Peter MacCallum Cancer Centre, 12 St. Andrew's Place, East Melbourne, Australia

⁴Department of Nuclear Medicine and PET Centre, San Raffaele Hospital, Milan, Italy

ABSTRACT

Development of the positron emission tomography (PET) diagnostic radiopharmaceutical (¹⁸F) fluoro-2-deoxy-D-glucose (¹⁸F-FDG) subsequently facilitated the discovery and clinical evaluation of several new tracers as imaging markers for cancer. While ¹⁸F-FDG is a widely employed marker for enhanced intracellular glycolysis and metabolic function, one of the newer tracers, (¹⁸F)-3'-fluoro-3' deoxythymidine (¹⁸F-FLT), has been developed as a biomarker for cell proliferation. In this review, the potential of ¹⁸F-FLT as a biomarker for cancer imaging is discussed.

Keywords: ¹⁸F-FLT, ¹⁸F-FDG, Positron Emission Tomography (PET), cellular proliferation

INTRODUCTION

Positron emission tomography (PET) is a rapidly developing imaging tool, with a clinical role that exceeds 15 years (Fathinul *et al.*, 2013). It is a quantitative imaging technique that

produces cross-sectional images that are composites of volume elements (NIH, 2006). The signal intensity for images especially in PET, corresponds to the concentration of radionuclide within the target tissue volume. PET is applied mainly in the clinical areas of cardiology, neurology and oncology, with the latter accounting for about 90% of all PET.

Article history:

Received: 12 March 2015

Accepted: 2 June 2015

E-mail addresses:

hishar.hassan@gmail.com (Hishar, H.),
roger.price@uwa.edu.au (R. Price),
ahmadsaadi@gmail.com (Fathinul Fikri, A. S.),
Eddie.Lau@petermac.org (Eddie Lau, W. F.),
assunta.carpinelli@ibfm.cnr.it (Assunta, C.),
drimaging@yahoo.com (A. J. Nordin)

*Corresponding author

The glucose derivative, (^{18}F) fluorodeoxy glucose (^{18}F -FDG), is the ubiquitous PET marker. However, there are numerous other tracers under development and with proven capability in highlighting a broad range of tissue metabolic functions. In a large meta-analysis, PET technique was found to change patients' management to almost 30% (Gambhir *et al.*, 2001). Though ^{18}F -FDG is now widely used as a frontier in management of cancer patients, numerous studies have suggested that this marker is not universally selective for tumour imaging. This is because ^{18}F -FDG is a glucose analogue and it is utilised by many cell types, which limits its specificity (Shields *et al.*, 1998; Yun *et al.*, 2003).

To overcome this limitation, radioisotope-labelled thymidine derivatives have been developed to image cellular proliferation by PET. Radioisotope-labelled thymidine has a long history. Pyrimidine nucleoside was first labelled with radioisotope in 1969 by Langen and his collaborators. In their study, they described the radio-labelled form of pyrimidine nucleoside as a selective inhibitor of DNA synthesis. However, only in 1991, was fluorothymidine (FLT) labelled with ^{18}F successfully introduced as carrier-added ^{18}F -FLT (Wilson *et al.*, 1991). Wilson and his collaborators monitored the efficacy of 3'-fluoro-3'-deoxy-thymidine (FDT) in HIV treatment. FDT is a fluorinated analogue of 3'-azido-thymidine (AZT), which was also found to be active against the HIV. However, FDT is more toxic than AZT (Wilson *et al.*, 1991). Wilson and his collaborators successfully labelled the 3'-fluoro-3'-deoxy-thymidine (FDT) with the ^{18}F to monitor the drug's distribution and targeting in the body (Grierson *et al.*, 1997).

Development of the FLT marker was subsequently continued by Grierson *et al.* in 1997 and it successfully introduced no-carrier-added ^{18}F -FLT. The next year, ^{18}F -FLT was first applied in imaging. The study was carried out to investigate animals and non-small cell lung cancer (NSCLC) patients (Shields *et al.*, 1998). From that study, it was found that ^{18}F -FLT was specifically taken up by tissues that actively proliferate, including bone marrow (Barthel *et al.*, 2003). Although ^{18}F -FLT appears to be a most promising marker, the major hurdle for its routine use is its low radiochemical yield during production. Nevertheless, it provides greater advantages to the clinicians in management of cancer patients.

THE BASIS OF ^{18}F -FLT AS A PROLIFERATION MARKER

The ^{18}F -FLT marker is administered to the patient by intravenous injection. It is taken up in the cell via both passive diffusion and also by Na^+ -dependent carriers. The ^{18}F -FLT marker, which is trapped in the cell, will undergo the phosphorylation process by thymidine kinase (TK1) and be converted into ^{18}F -FLT-monophosphate (Been *et al.*, 2004). Intracellular trapping and accumulation of ^{18}F makes it possible to be detected by PET camera, which in turn gives a measure of the TK1 activity.

In the physiological pathway, both thymidine and ^{18}F -FLT encounter the same initial fate (Fig.1). Both of them will be phosphorylated by TK1 for DNA synthesis. However, for the ^{18}F -FLT marker, the DNA replication is inhibited due to the lack of the hydroxyl (-OH) group attached at the carbon number 3'-position on the sugar ring. Hence, the ^{18}F -FLT marker will be trapped inside the proliferating cells, and its radioactive signature will continue to accumulate there.

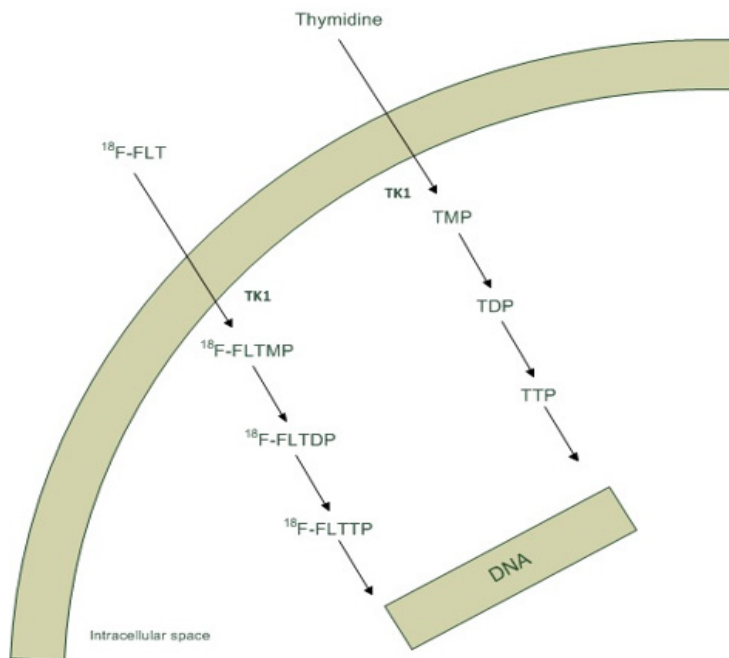


Fig.1: Uptake mechanism of thymidine and ¹⁸F-FLT.

The uptake of ¹⁸F-FLT by cells is correlated with TK1 activity (Barthel *et al.*, 2003; Chen *et al.*, 2005). TK1 activity in proliferating cells is noted to be 3 to 4 times higher in malignant cells compared to benign cells (Been *et al.*, 2004). The enzymatic activity of TK1 reaches maximum level in the late G1 phase and S phase of the cell proliferative cycle. Therefore, monitoring of TK1 activity should give an early indication as to whether a cell population is in proliferative malignant state, or in benign state.

POTENTIALS OF ¹⁸F-FLT IN ONCOLOGY

¹⁸F-FDG marker is known for its relative non-specificity. Hence, there are many active inflammatory diseases and some aggressive benign tumours that inevitably give high ¹⁸F-FDG uptake in cells. Furthermore, some disease processes healed by fibrosis leave a significant residual mass, thereby limiting categorisation of a complete response to ¹⁸F-FDG.

In comparison, the FLT marker has the ability to demonstrate an increased rate of cellular proliferation and is potentially helpful in the setting of therapeutic monitoring as it has less affinity to inflammatory conditions. ¹⁸F-FLT is potentially a more specific marker than ¹⁸F-FDG with a high positive predictive value for malignancy. ¹⁸F-FLT marker is also potentially useful in the evaluation of cerebral malignancy due to the lack of background cerebral uptake, unlike the high cerebral activity normally seen in ¹⁸F-FDG.

In addition, there is good evidence that ¹⁸F-FLT uptake is closely correlated with cellular proliferation with correlation between the intensity of uptake in lung cancer as measured by SUV with proliferation indices such as Ki-67 staining in a resected specimen (Hofman *et al.*,

2012). The ability of ^{18}F -FLT to identify tissue with a high proliferative rate has potential applications in the assessment of haemopoietic tissue and high grade disease transformation in haematological malignancy. The assessment of bone marrow reserve is important in considering patients for chemotherapy or radionuclide therapy, which is potentially myelotoxic. ^{18}F -FLT has the ability to document the extent and distribution of haemopoietic tissue, including the presence of extramedullary haemopoiesis, which can guide subsequent treatment choice. There are occasions when bone marrow sampling does not provide a representative picture of the true haemopoietic status due to sampling error and heterogeneous distribution of haemopoietic tissue (Fig.2).

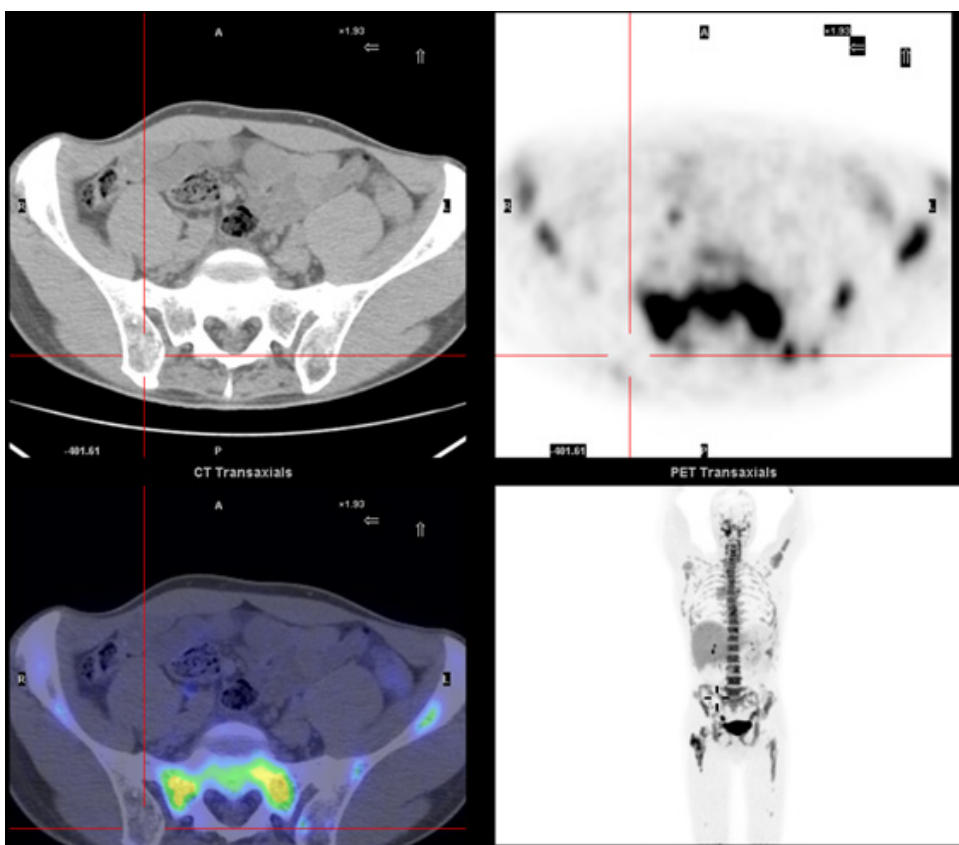


Fig.2: A 55-year-old man with stage IV diffuse large B cell lymphoma with nodal and multifocal bony disease and the pre-treatment bone marrow biopsy from the right posterior ilium showing hypocellular marrow and aplasia, in the presence of normal peripheral blood counts. ^{18}F -FLT PET/CT was performed, which demonstrated absence of proliferative tissue in the right posterior ilium but fairly normal distribution of hyperproliferative bone marrow elsewhere with no evidence of extramedullary haemopoiesis in the spleen or elsewhere. The ^{18}F -FLT PET/CT findings suggested that the initial bone marrow biopsy result was non-representative of his true bone marrow status and the patient went on to undergo systemic chemotherapy treatment without any myelotoxicity problem (Image courtesy of The Peter Mac Callum Centre).

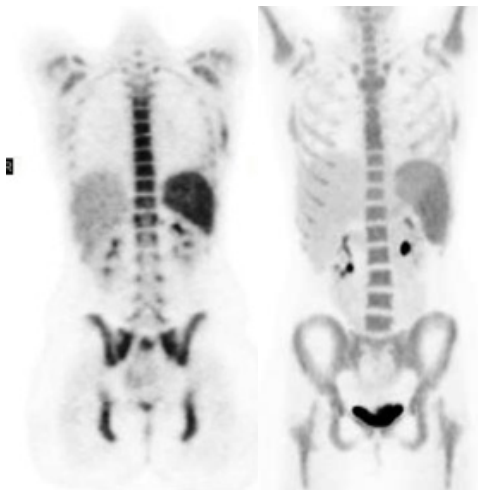


Fig.3: Coronal MIP-PET images using ^{18}F -FLT in the assessment of skeletal sarcoma before (left) and after treatment (right). The images show an increased ^{18}F -FLT intensity in the left lateral chest wall (marked), which appears less proliferative after treatment (right). (Image courtesy of The Peter Mac Callum Centre).

DIAGNOSIS EVALUATION: ^{18}F -FLT VERSUS ^{18}F -FDG

Pancreatic Cancer

^{18}F -FLT has been used in imaging pancreatic-cancer-specific cell lines, SW-979 and BxPc-3. The study was performed by Seitz *et al.* (2002) to prove that ^{18}F -FLT has greater specificity than ^{18}F -FDG. In that study, the ^{18}F -FLT uptake was 18.4% and 5.2%, respectively. In comparison, ^{18}F -FDG was also administered to the same cell lines. It was observed that the ^{18}F -FDG uptake was only 0.6% and 0.3% for the corresponding cells. Evidence such as no increased ^{18}F -FLT uptake was observed in normal pancreatic lobules in comparison with large ^{18}F -FDG uptake detected in normal pancreatic lobules confirmed that ^{18}F -FLT has higher specificity for pancreatic cancer.

The previous work by Seitz was supported by the Herrmann group's findings in 2008. In the study consisting of 21 patients diagnosed with malignant pancreatic tumours, 15 patients had an increased ^{18}F -FLT uptake. Herrmann and his colleagues were able to demonstrate that ^{18}F -FLT was a specific marker for pancreatic cancer (Herrmann *et al.*, 2008). They also suggested that ^{18}F -FLT may be used to differentiate pancreatic cancer from pancreatic pseudotumors that were subjected to arise from chronic pancreatitis (Herrmann *et al.*, 2008). As any other studies, Herrmann acknowledged that although the ^{18}F -FLT showed high specificity for pancreatic cancer, it turned out that the sensitivity was reduced for malignant lesions (Herrmann *et al.*, 2008).

Contrary to the Seitz *et al.* (2002) and Herrmann *et al.* (2008) studies, initial evaluation of ^{18}F -FLT for primary pancreatic study led by Quon *et al.* (2007) demonstrated the opposite. In a pilot study consisting of five patients who were newly diagnosed with unresectable pancreatic

cancer, the visual interpretation of the primary site was assessed using ^{18}F -FLT PET/CT and ^{18}F -FDG PET/CT. In ^{18}F -FLT PET/CT, the primary lesion was detectable in only two of the five patients, while all five showed lesions in the ^{18}F -FDG PET/CT imaging (Quon *et al.*, 2007). Throughout the study, ^{18}F -FLT showed poor lesion detectability and low levels of uptake in the primary tumour compared to ^{18}F -FDG. Hence, it was suggested that the use of ^{18}F -FLT was not promising for characterisation of pancreatic cancer and it offered no benefit in monitoring therapy due to poor baseline scan (Quon *et al.*, 2007).

Pulmonary Nodes and Lung Cancer

In pulmonary nodes and lung cancer, one expected difficulty in differentiating malignant from benign solitary pulmonary nodes (Been *et al.*, 2004). Although ^{18}F -FDG has proved to be a helpful and accurate diagnostic tool, with excellent sensitivity of 96.8% and good specificity of 77.8%, reports of false-positives still originate, mainly from granulomatous and inflammatory disease. Thus, a more specific tracer that does not show uptake in inflammatory tissues would be useful. In the non-small cell lung cancer (NSCLC) patient, image with low background activity was acquired with the administration of ^{18}F -FLT on patients (Been *et al.*, 2004). Buck *et al.* (2003) further investigated 30 patients diagnosed with solitary pulmonary nodes (SPN) and deployed ^{18}F -FLT as a marker. They reported 86% ^{18}F -FLT uptake by the malignant lesions, whereas no ^{18}F -FLT uptake was observed in benign lesions. This demonstrated that in distinguishing the malignant SPN, ^{18}F -FLT had higher specificity than ^{18}F -FDG.

Breast Cancer

On the contrary, in breast cancer cases, although multiple studies have been carried out by many groups using ^{18}F -FLT, the results have not been consistent. In an early investigation in patients diagnosed with breast cancer, it was observed that ^{18}F -FLT was taken up in breast cancer cells (Been *et al.*, 2004). In another study by Silverman and his colleagues in 2002, there was a 1.3 to 2.3 times higher ^{18}F -FLT uptake reported in primary breast cancers as compared to ^{18}F -FDG uptake. However, in 2004, Smyczek-Gargya and his colleagues, investigated 12 patients with breast cancer with ^{18}F -FLT and compared it to ^{18}F -FDG, concluding that ^{18}F -FDG uptake was higher than ^{18}F -FLT. Scientists agree that it is still unclear what will be the role for ^{18}F -FLT in patients with breast cancer as inconsistent findings from multiple studies have led to uncertainty in the role of ^{18}F -FLT in breast cancer management. Interestingly, the study of Been and his colleagues showed that ^{18}F -FLT uptake predicted tumour marker response to chemotherapy better than ^{18}F -FDG (Been *et al.*, 2004). The latter work was supported by Pio and his colleagues in 2006 and also Kenny *et al.* (2007). Pio and his colleagues had evaluated the treatment response with ^{18}F -FLT PET in patients diagnosed with breast cancer over ^{18}F -FDG PET. Scans were done prior to chemotherapy treatment or anti-hormonal therapy two weeks after completion of the first treatment cycle and after the end of treatment or over a year if the treatment had not yet been completed. In the study, they found that changes in levels of the serum marker, CA27.29, were more strongly correlated with tumour ^{18}F -FLT uptake than with ^{18}F -FDG (Pio *et al.*, 2006). Meanwhile, Kenny and his colleagues reported a significant association between tumour ^{18}F -FLT uptakes with the Ki-67 labelling index (Kenny *et al.*,

2007). Hence, it was proposed that measuring the early response to chemotherapy for locally advanced breast cancer is probably the most interesting research question for ^{18}F -FLT studies in patients with breast cancer (Been *et al.*, 2004; Pio *et al.*, 2006; Kumar, 2007; Kenny *et al.*, 2007).

Brain Cancer

In the management of brain tumours, PET provides information on the tumour grade and also assists in assessing the optimal site for biopsy. Several PET radiopharmaceutical markers have been used for brain cancer imaging. These include ^{18}F -FDG, ^{18}F -FLT, and 11C-Met (L-methyl-[11C] methionine). Chen and his colleagues systematically compared ^{18}F -FLT with ^{18}F -FDG in human gliomas, in relation to sensitivity, in the evaluation of recurrent high-grade glioma (Chen *et al.*, 2005). They discovered that uptake of ^{18}F -FLT in glioma was relatively rapid. ^{18}F -FLT typically showed a similar uptake as for ^{18}F -FDG. However, an interesting finding was that the ^{18}F -FLT background uptake in normal brain tissue was low, and this could be due to a slow proliferation rate. This feature significantly showed that ^{18}F -FLT has potential to derive a better mean standardised uptake value (SUV) in PET imaging of a tumour, as compared with ^{18}F -FDG.

Although ^{18}F -FDG has been used extensively in brain tumour imaging, one of the several major drawbacks of ^{18}F -FDG in this context is its difficulty in characterising tumours in the brain. This is due to the high basal glucose metabolic rate of normal brain tissue. ^{18}F -FDG uptake of low-grade tumours is generally similar to that of normal white matter, whereas high-grade tumour uptake can be similar to that of normal grey matter, resulting in limited sensitivity of lesion detection. In addition, in recurrent tumours the ^{18}F -FDG uptake could be lower than the normal white matter, whereas in necrotic cells the ^{18}F -FDG uptake could be higher than the normal white matter. It can be assumed that ^{18}F -FLT has a theoretical advantage in detecting tumour recurrence as there is little uptake in normal brain. It has been agreed that ^{18}F -FLT may help to define tumour activity by imaging tumours with greater sensitivity than ^{18}F -FDG (Nitzsche *et al.*, 2003). Another significant finding arose from a study by Nitzsche and his colleagues in 2003, who determined that ^{18}F -FLT was greater to ^{18}F -FDG for the detection of recurrent brain tumours after brachytherapy.

A study by Dohmen and colleagues in 2000 compared the use of ^{18}F -FLT with L-methyl-11C-methionine (11C-MET) for the detection of brain tumours. They discovered that ^{18}F -FLT showed higher tumour contrast compared to 11C-MET. However, low-grade brain tumours limit the application of ^{18}F -FLT in brain tumour imaging as it showed poor visual distinction in that case (Been *et al.*, 2004). Garlip (2003) discovered that the ^{18}F -FLT standardised uptake value was higher than that of 11C-MET. Even though ^{18}F -FLT has shown some advantages compared with ^{18}F -FDG and 11C-MET, relatively small and therefore inconclusive studies have been published. There is a need to provide anatomical information and to further determine whether ^{18}F -FLT is able to differentiate between benign and malignant tissues and between residual tumour and radionecrosis. If ^{18}F -FLT proves to be a sensitive and specific marker for the brain, it will be very useful for the next stages in management; namely establishing the best site for tumour biopsy and for planning of radiotherapy in heterogeneous tumour (Been *et al.*, 2004).

Colorectal Cancer (CRC)

Francis and his colleagues in 2003 successfully imaged colorectal cancer using both ^{18}F -FDG and ^{18}F -FLT. Both markers displayed 100% sensitivity when imaging primary colorectal cancer. For visualisation of extra hepatic lesions, ^{18}F -FDG and ^{18}F -FLT demonstrated sensitivities of 100% and 92% respectively (Francis *et al.*, 2003).

However, his study also demonstrated an increased uptake of ^{18}F -FDG from non-malignant inflammatory peritoneal lesions, which were thus presumed to be malignant. This would lead to false-positive scans when using ^{18}F -FDG. In contrast, such lesions showed no avidity for ^{18}F -FLT, demonstrating a specificity that may be useful for further characterisation of equivocal lesions (Francis *et al.*, 2003). His study concluded that in colorectal cancer, ^{18}F -FLT demonstrated lower cellular trapping compared to ^{18}F -FDG. The poor sensitivity displayed by ^{18}F -FLT makes it a poor candidate as a diagnostic tool for colorectal cancer. Although it lacks in sensitivity (inclusion of free positives), ^{18}F -FLT has the potential to improve the specificity (rejection of false positives) for the detection of colorectal cancer.

Another study led by Wang *et al.* (2009) investigated whether the use of dual-tracers, ^{18}F -FDG and ^{18}F -FLT, could predict the biologic character of metastases in colorectal cancer. Wang *et al.* (2009) used animal modelling to prove that higher uptake of ^{18}F -FLT could be correlated to a higher incidence of metastasis. The human colorectal cancer cell lines SW480 and SW620 were generated in 20 mice, whereby the former was generated in the left front leg and latter was generated in the right front leg. Wang observed high uptake of ^{18}F -FLT in mice from small animal PET/CT which correlated well with the overexpression of HSP27 and integrin $\beta 3$ in the left front leg of the mice (SW480) (Wang *et al.*, 2009). On the other hand, high uptake of ^{18}F -FDG was observed in the right front leg, which had been generated with SW620 cell lines but not by ^{18}F -FLT. The overexpression of HSP27 and integrin $\beta 3$ in SW480, which observed higher uptake of ^{18}F -FLT, was believed to reflect a higher rate of metastasis to lung and liver (Wang *et al.*, 2009). Meanwhile, high uptake of ^{18}F -FDG in SW620 cell lines can possibly correlate with lymphatic metastases (Wang *et al.*, 2009). From the study, Wang and his colleagues (2009) suggested that a combination of the dual-tracers ^{18}F -FLT and ^{18}F -FDG could be used to predict the biologic behaviour of colorectal cancer.

Lymphoma

Lymphoma is a type of malignancy that originates in lymphocytes of the immune system; particularly in lymph nodes and presenting as an enlargement of these nodes. For high-grade lymphoma visualisation, there is no dispute that ^{18}F -FDG has been proven to be a sensitive method. However, for the low-grade (indolent) lymphoma, the value of ^{18}F -FDG is still unclear (Been *et al.*, 2004). Hence, ^{18}F -FLT could in theory have an additional value as a tracer of proliferative tissues. Been (2004) also compared ^{18}F -FLT and ^{18}F -FDG in lymphoma patients. It was found that the mean standardised uptake value (SUV) for ^{18}F -FLT was 4.5 whereas the mean SUV for ^{18}F -FDG was 5. This showed that ^{18}F -FDG had higher uptake in lymphoma. In terms of sensitivity, both markers were found to be comparable. As ^{18}F -FLT uptake in lymphoma is closely correlated with the rate of proliferation, problems may arise during the prognosis in lymphoma. In the case of prognosis in lymphoma, the rate of proliferation is not always

correlated with lymphoma's prediction (Been *et al.*, 2004). In haematopoietic dysfunction cases, the ^{18}F -FLT marker is able to determine the activity, extent and distribution of bone marrow reserve and hence, assist in decision making for a variety of clinical indications. ^{18}F -FLT findings complement results of bone marrow aspiration and trephine biopsy (BMAT) and could be a useful tool for assessing response to novel treatments in patients with myeloproliferative diseases (Hofman *et al.*, 2012).

Melanoma

Melanoma is a malignant tumour of pigment cells (melanocytes), which are found predominantly in skin but also in the bowel and eye. Cobben and colleagues in 2003 used ^{18}F -FLT in imaging of melanoma to compare with ^{18}F -FDG. They discovered that the specificity and sensitivity of ^{18}F -FLT in imaging of melanoma was 60% and 88%, respectively. In contrast, the specificity and sensitivity using ^{18}F -FDG was 83% and 92%, respectively. This indicates that the specificity and sensitivity of ^{18}F -FLT for melanoma are lower than those of ^{18}F -FDG. It appears that ^{18}F -FLT is not a preferential marker when it comes to detection of melanoma.

LIMIT OF ^{18}F -FLT AS A CELLULAR PROLIFERATION MARKER

The extent of the agreement on whether ^{18}F -FLT shows a net benefit in cellular proliferation has been continuously debated. The dispute arises due to the nature of DNA synthesis mechanisms: the thymidine salvage pathway and de novo synthesis pathway. In thymidine salvage pathway, thymidine is transported across the cell membrane and phosphorylated by TK1 into thymidine monophosphate (TMP) before it is further phosphorylated into thymidine diphosphate (TDP) and thymidine triphosphate (TTP) (McKinley *et al.*, 2013). TTP then is incorporated into the DNA.

In contrast to thymidine salvage, the de novo synthesis pathway uses deoxyuridine monophosphate as an alternative for conversion into TMP through the action of the thymidylate synthase (TS) enzyme. TPM is then further phosphorylated and incorporated into the DNA. Due to this nature of the DNA synthesis mechanism, it is assumed that previous studies using ^{18}F -FLT may underestimate cell proliferation in de novo pathway-dependent tumours. In 2013, McKinley and his colleagues conducted a study to demonstrate that ^{18}F -FLT is poorly reflected as a proliferative index in some tumours that utilise the de novo pathway. They generated the human colorectal cancer cell lines, HCT-116 (parental line) and HCT-116p21 in the cell lines and also in the xenografts to explore the effect of p21 deletion on ^{18}F -FLT. Interestingly, in HCT-116p21 cells, elevated levels of the TS enzyme was observed. Meanwhile, the level of TK1 diminished. When ^{18}F -FLT PET was performed on the xenografts to demonstrate the sensitivity of ^{18}F -FLT to de novo pathway utilisation, the HCT-116 xenografts manifested greater uptake than the analogous HCT-116p21 xenografts (McKinley *et al.*, 2013). The finding were supported by the findings of a previous study led by Moroz *et al.* (2011) who suggested that ^{18}F -FLT uptake was unrepresentative of xenografts growth in tumours utilising the de novo pathway. From the findings, McKinley *et al.* (2013) concluded that ^{18}F -FLT PET cannot discriminate moderately proliferative, thymidine salvage-driven tumours from high-proliferative index tumours that rely primarily upon the de novo pathway.

CONCLUSION

It is well accepted that ^{18}F -FDG is the ubiquitous marker in PET oncological practice. Nevertheless, ^{18}F -FLT is an exciting marker with improved specificity that could be the number one candidate for therapeutic monitoring. Thereby, future research should continue to probe the potential of ^{18}F -FLT as a powerful marker for cellular proliferation.

REFERENCES

- Barthel, H., Cleij, M. C., Collingridge, D. R., Hutchinson, O. C., Osman, S., & He, Q. (2003). 3'-Deoxy-3' [^{18}F]Fluorothymidine as a new marker for monitoring tumour response to antiproliferative therapy in vivo with positron emission tomography. *Cancer Research*, *63*, 3791-3798.
- Been, L. B., Suurmeijer, A. J. H., Cobben, D. C. P., Jager, P. L., Hoekstra, H. J., & Elsinga, P. H. (2004). [^{18}F]FLT-PET in oncology: current status and opportunities. *European Journal of Nuclear Medicine and Molecular Imaging*, *31*(12), 1559-1672.
- Buck, A. K., Halter, G., Schirmmeister, H., Kotzerke, J., Wurziger, I., & Glatting, G. (2003). Imaging proliferation in lung tumours with PET: ^{18}F -FLT versus ^{18}F -FDG. *Journal of Nuclear Medicine*, *44*(9), 1426-1431.
- Cancer Imaging Program. (2006). An investigational positron emission tomography (PET) radiopharmaceutical for injection and intended for use as an in vivo diagnostic for imaging active cellular proliferation of malignant tumours. *Division of Cancer Treatment and Diagnosis* (4th ed.). National Institute of Health.
- Chen, W., Cloughesy, T., Kamdar, N., Satyamurthy, N., Bergsneider, M., & Liau, L. (2005). Imaging proliferation in brain tumours with ^{18}F -FLT PET: Comparison with ^{18}F -FDG. *Journal of Nuclear Medicine*, *46*(6), 945-952.
- Cobben, D. C. P., Jager, P. L., Elsinga, P. H., Maas, B., Suurmeijer, A. J. H., & Hoekstra, H. J. (2003). 3'- ^{18}F -fluoro-3'-deoxy-L-thymidine: A new tracer for staging metastatic melanoma? *Journal of Nuclear Medicine*, *44*, 1927-1932.
- Dohmen, B. M., Shield, A. F., Grierson, J. R., Kuntzsch, M., Reimold, M., & Sloan, A. (2000). [^{18}F]FLT-PET in brain tumours. *Journal of Nuclear Medicine*, *41*(supplementary), 216P.
- Fathinul, F., Nordin, A. J., & Lau, W. F. E. (2013). ^{18}F FDG-PET/CT is a useful molecular marker in evaluating tumor aggressiveness; A revised understanding of an in-vivo FDG PET imaging that alludes the alteration of cancer biology. *Cell Biochemistry and Biophysics*, *66*(1), 37-43.
- Francis, D. L., Visvikis, D., Costa, D. C., Arulampalam, T. H. A., Townsend, C., & Luthra, S. K. (2003). Potential impact of [^{18}F]3'-deoxy-3'-fluorothymidine versus [^{18}F]fluoro-2-deoxy-D-glucose in positron emission tomography for colorectal cancer. *European Journal of Nuclear Medicine and Molecular Imaging*, *30*(7), 988-994.
- Gambhir, S. S., Czermin, J., Shcwimmer, J., Silverman, D. H., Coleman, R. E., & Phelps, M. E. (2001). A tabulated summary of the FDG PET literature. *Journal of nuclear medicine*, *42*(5 suppl), 1S-93S.
- Garlip, G., Dittmar, C., Kracht, L., Thomas, A. V., Herholz, K., & Heiss, W. D. (2003). Identification of DNA and amino acid metabolism in human gliomas by PET. *Journal of Nuclear Medicine*, *44*(5), 167P-167P.

- Grierson, J. R., Shields, A. F., & Eary, J. F. (1997). Development of a radiosynthesis for 3'-[F-18] fluoro-3'-deoxynucleosides. *Journal of Labelled Compounds and Radiopharmaceuticals*, 40, 60-62.
- Herrmann, K., Eckel, F., Schmidt, S., Schneidhauer, K., Krause, B. J., & Kleeff, J. (2008). In vivo characterization of proliferation for discriminating cancer from pancreatic pseudotumors. *Journal of Nuclear Medicine*, 49(9), 1437-1444.
- Hofman, M., Segard, T., Khan, Z., Seymour, J., & Hicks, R. (2012). Clinical utility of ¹⁸F-fluoro-L-thymidine (FLT) PET to evaluate bone marrow distribution and proliferation in patients with haematopoietic dysfunction. *Journal of Nuclear Medicine*, 53(S1), 538.
- Kenny, L., Coombes, R. C., Vigushin, D. M., Al-Nahhas, A., Shousha, S., & Aboagye, E. O. (2007). Imaging early changes in proliferation at 1 week post chemotherapy: a pilot study in breast cancer patients with 3'-deoxy-3'-[¹⁸F]fluorothymidine positron emission tomography. *European Journal of Nuclear Medicine and Molecular Imaging*, 34(9), 1339-1347.
- Kumar, R. (2007). Assessment of therapy response in malignant tumours with ¹⁸F-fluorothymidine. *European Journal of Nuclear Medicine and Molecular Imaging*, 34(9), 1334-1338.
- Langen, P., Etzol, G., Hintsche, R., & Kowollik, G. (1969). 3'-deoxy-3'-fluorothymidine, a new selective inhibitor of DNA-synthesis. *Acta biologica et medica Germanica*, 23(6), 759-766.
- McKinley, E. T., Ayers, G. D., Smith, R. A., Saleh, S. M., Zhao, P., Washington, M. K., Coffey, R. J., & Manning, H. C. (2013). Limits of [¹⁸F]-FLT PET as a biomarker of proliferation in oncology. *Plos One*, 8(3), 1-9.
- Moroz, M. A., Kochetkov, T., Cai, S., Wu, J., & Shamis, M. (2011). Imaging colon cancer response following treatment with AZD1152: A preclinical analysis of [¹⁸F]fluoro-2-deoxyglucose and 3'-deoxy-3'-[¹⁸F]fluorothymidine imaging. *Clinical Cancer Research*, 17(5), 1099-1110.
- Nitzsche, E. U., Walter, M., Schirp, U., Machulla, H. J., & Mueller, J. (2003). Combined PET imaging of proliferation and glycolysis for follow up of brachytherapy in brain tumours. *Society of Nuclear Medicine 50th Annual Meeting*.
- Pio, B. S., Park, C. K., Pietra, R., Hsueh, W. A., Satyamurthy, N., & Pegram, M. D. (2006). Usefulness of 3'-[F-18]Fluoro-3'-deoxythymidine with positron emission tomography in predicting breast cancer response to therapy. *Molecular Imaging and Biology*, 8(1), 36-42.
- Quon, A., Chang, S. T., Chin, F., Kamaya, A., Dick, D. W., Loo, J. B. W., Gambhir, S. S., & Koong, A. C. (2008). Initial evaluation of ¹⁸F-fluorothymidine (FLT) PET/CT scanning for primary pancreatic cancer. *European Journal of Nuclear Medicine and Molecular Imaging*, 35(3), 527-531.
- Seitz, U., Wagner, M., Neumaier, B., Wawra, E., Glatting, G., & Leder, G. (2002). Evaluation of pyrimidine metabolising enzymes and in vitro uptake 3'-[¹⁸F]fluoro-3'-deoxythymidine [¹⁸F]FLT in pancreatic cancer lines. *European Journal of Nuclear Medicine and Molecular Imaging*, 29(9), 1174-1181.
- Shields, A. F., Grierson, J. R., Dohmen, B. M., Machulla, H. J., Stayanoff, J. C., & Lawhorn-Crews, J. M. (1998). Imaging proliferation in vivo with [¹⁸F]FLT and positron emission tomography. *Nature Medicine*, 4(11), 1334-1336.
- Silverman, D. H., Pio, B. S., Satyamurthy, N., Park, C. K., Chap, L., & Pegram, M. (2002). Monitoring effects of breast cancer chemotherapy with fluorodeoxyglucose and fluoro-L-thymidine. *Journal of Nuclear Medicine*, 43(5), 311.

- Smyczek- Gargya, B., Fersis, N., Dittmann, H., Vogel, U., Reischl, G., & Machulla, H. J. (2004). PET with [¹⁸F]fluorothymidine for imaging of primary breast cancer: A pilot study. *European Journal of Nuclear Medicine and Molecular Imaging*, 31(5), 720-724.
- Wang, H., Jinming, Z., Jiahe, T., Baolin, Q., Tianran, L., Yingmao, C., Jian, L., & Shan, W. (2009). Using dual-tracer PET to predict the biologic behaviour of human colorectal cancer. *Journal of Nuclear Medicine*, 50(11), 1857-1864.
- Wilson, I. K., Chatterjee, S., & Wolf, W. (1991). The use of 3'-fluoro-3'-deoxythymidine and studies of its ¹⁸F-labelling, as a tracer for the non-invasive monitoring of the biodistribution of drugs against AIDS. *Journal of Fluorine Chemistry*, 55, 283-289.
- Yun, M., Oh, S. J., Ha, H. J., Ryu, J. S., & Moon, D. H. (2003). High radiochemical yield synthesis of 3'-deoxy-3'-[¹⁸F]fluorothymidine using (5'-O-dimethoxytrityl-2'-deoxy-3'-O-nosyl-β-D-threo pentofuranosyl)thymine and its 3-N-BOC-protected analogue as a labelling precursor. *Nuclear Medicine and Biology*, 30(2), 151-157.