

The Effects of Commercial Flower Honey and Turmeric on Dermal Wound in Rats

Noor Idzatul Khairiah Ithnin, ¹Kalthum Hashim & ²Md Sabri Mohd Yusoff

¹Department of Veterinary Clinical Studies

²Department of Veterinary Pathology and Microbiology

Faculty of Veterinary Medicine, Universiti Putra Malaysia, Serdang, Selangor.

Abstract

Twenty healthy rats, ten adults (2-month-old) and ten young (1-month-old), were used in this study. Four skin biopsies were created at the dorsum of each rat under general anesthesia. The wound was each treated with honey, turmeric powder, turmeric-honey paste and a blank (control). The wounds were photographed on day 0, 1, 3, 5, 7 and 9. Wound area reduction was measured on day 9 after which the rats were euthanized. The skin samples were taken for histology. The results showed that there was no significant difference in the healing between treatments in young and adult rats. However, honey was the best treatment with the highest healing scores, followed by control, turmeric and honey-turmeric paste. Honey-turmeric paste resulted in a severe wound infection thus delayed healing.

Keywords: flower honey, turmeric, honey-turmeric paste

Introduction

Alternative medicine using herbs is another option in treating acute or chronic wound. The herbs are easily available in Malaysia and normally used by the Malay community for treatment.

Turmeric or *Curcuma longa*, a rhizomatous herbaceous perennial plant of the ginger family (Zingiberaceae), contains up to 5% essential oil and 3% curcumin, a polyphenol. curcumin or natural Yellow 3 is the active substance of turmeric and thought to have many medicinal properties (Goel et al., 2008; Ravindranath and Chandrasekara, 1980). In South Asia, it is used as an antiseptic and antibacterial for cuts, burns and bruises also to treat skin, heart, liver and lung diseases, for epilepsy and bleeding disorders, and to purify the body-mind. Other properties of turmeric include as an analgesic, anti-inflammatory, anti-tumour, anti-allergic, antioxidant, antiseptic, antispasmodic, appetizer, astringent, and cardiovascular, carminative, digestive and diuretic stimulant (Ramdev, 2009).

Flower honey is a sweet element produced by honey bees and derived from the nectar of the flowers. For 2700 years, honey has been used to treat a variety of ailments mainly by topical application, but only recently the antiseptic and antibacterial properties of honey have been chemically explained (Wikipedia, 2009). Honey is composed of sugars such as glucose and fructose and minerals such as magnesium, potassium, calcium, sodium

chlorine, sulphur, iron and phosphate. It contains vitamins B1, B2, B3, B5, B6 and C, each quantity of which determine the qualities of the nectar and pollen. There are also traces of copper, iodine and zinc.

Wound healing refers to the replacement of destroyed body tissues by living tissues (Walter and Israel, 1987) and comprises of two essential stages; regeneration and repair. In regeneration, specialized tissues are replaced by the proliferation of surrounding undamaged ones. In repair, lost tissue is replaced by granulation tissues which mature from scar tissue (Watson, 2003).

This study was conducted to determine the duration of wound healing using turmeric, honey and turmeric-honey combination, and secondly to study their effects on wound healing in different age groups of rats.

Materials and Methods

Twenty healthy rats were used and they were divided into two groups. Group 1 (G1) consisted of ten 5 weeks old rats weighing 100 g each and Group 2 (G2) 10 adults aged 9 weeks weighing 250 g each. Honey and turmeric used in this study were commercially available. Honey was 'Flower honey' containing energy, protein, fat, cholesterol, carbohydrate, fibre and sodium. Turmeric is in powder form that contains seventy percent pure turmeric.

The dorsal area of each rat was shaved and cleaned with 50% alcohol, followed by povidone iodine. Skin was stretched and four circular wells were made using a biopsy punch (Figure 1) 8 mm in diameter. Skin biopsy was carried out under anaesthesia using Ketamine HCl 35 mg/kg and Xylazine HCl 5 mg/kg intramuscularly. The rats were allowed to recover in a cage, fed with pellet and water *ad-libitum*. Treatments were applied immediately after inducing the wound as follows: well no. 1= Control, 2= honey, 3=turmeric and 4=honey-turmeric paste. The wounds were observed and photographed on day 0, 1, 3, 5, 7 and 9. The healing progress of the wounds was scored as 0=no healing, 1=slight, 2=moderate, 3=good, 4=very good and 5=excellent.

Raw wound areas were measured by drawing their boundaries on a transparent plastic and the area squares within the boundaries were counted using graph paper. The values for each treatment were averaged and presented in mm²:

The percentage of wound reduction (healing) was calculated using the formula as follows:

$$\% = \frac{\text{wound area day 0} - \text{wound area day 9}}{\text{wound area day 0}} \times 100$$

For histology studies, wound tissues were preserved in 10% formalin, and later subjected through different grades of alcohol to ensure complete dehydration before embedded in paraffin wax. Serial sections of paraffin embedded tissues of 3 mm thickness were cut

using a microtome and stained with haemotoxylin and eosin. Sections were qualitatively assessed under the light microscope for infiltration of inflammatory cells, fibroblastic proliferation and epithelisation.

Data obtained were analysed using a two-way ANOVA. A value of $P \leq 0.05$ was considered as significant.

Results

Results showed on days 5, 7 and 8 that there was no significant difference in wound healing between young and adult group. On day 9 the results showed that control and honey healed significantly faster than other treatments.

Honey was the best treatment with highest healing scores, followed by control, turmeric and honey turmeric paste (Figure 2).

In adult, results showed that control group healed fastest compared to other treatments (Figure 3). Two of ten adults in control group showed complete healing where the skin regained most of its tensile strength.

In young rats, wound treated with honey had the fastest rate of healing compared to other groups (Figure 3). Three of ten treated with honey showed complete healing on day 9 when the skin surface has completely apposed.



Figure 1. Circular wells were made using a biopsy punch

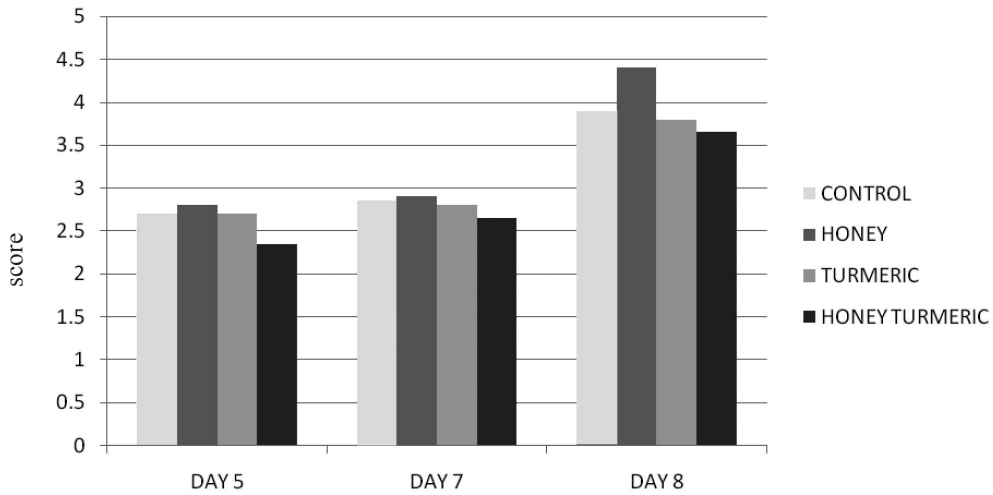


Figure 2. Wound healing score

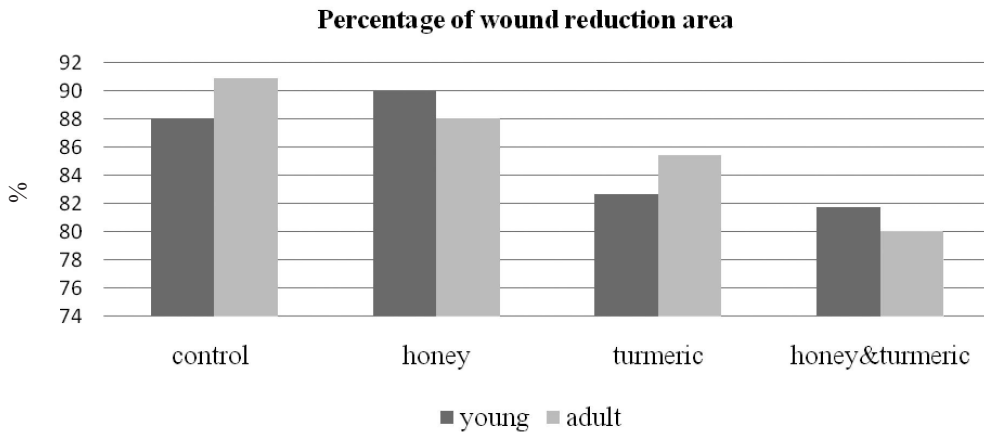


Figure 3. Mean percentage of wound reduction area 9 days post-treatment

Discussion

In this study, topical application of powdered honey has significantly better wound healing activities. These results were similarly found by Rasik and Raghbir (1999) and Efem (1988) although they used the extract form. This may be attributed to the angiogenic and mitogenic properties of honey. This study also showed that there was no significant difference in the duration of wound healing for turmeric and honey. Honey and turmeric in combination (paste), was found to be not suitable to heal wound as they produced severe reaction making the wound raw and puss-filled. However, infection could not be ruled out as the rats were placed in an open cage. Another factor was the

two items may be not chemically compatible and there was not much work done to study the chemical reaction of the two in healing wound.

According to Stashak and Theorel (1991), generally, wound in young animals healed more rapidly than wound in adults which showed sluggish inflammatory response to injury and delayed wound contraction. Conversely was true in this study which showed no significant difference in wound healing in both young and adult groups. One reason probably be due to a small difference in the ages of the two groups.

The study showed that in the young rats, the wound treated with honey-turmeric paste initially allowed infection to set in which was evident by the presence of pus which eventually healed. The non-sterile honey and turmeric may have a latent period before the bacteria succumbed to treatment. This finding was also reported by Lusby et al. (2002) which stated that the suppression and resolution of infections that were found under the dressing of honey may be the result of bactericidal action from prolonged exposure or as a result of the natural defense system being more successful with multiplication of bacterial cells held in check. According to Efem (1988) following topical application of honey, 51 out of 59 wounds were infected at the beginning of the treatment, and became sterile after 1 week of treatment. This study found that there was no significant difference in healing between control and honey as application was done only once but according to Efem (1988) the results may be significantly different if treatments were applied daily for 7days.

The results obtained from the study indicated that treatment using flower honey healed the fastest followed by turmeric and honey-turmeric paste. There was no significantly difference in wound healing between young and adult rats.

For future studies, it is recommended to use one treatment per rat. This facilitates monitoring of the progress of the wound. Frequent application of treatments such as daily or on alternate days may give a significant outcome. 'Three-week' age difference was not sufficient to compare age-group relation in rats, ideally they should be at least 6 months apart.

Referances

- Efem, S. (1988). Clinical observation on the wound healing properties of honey. *Br J Surg* **75**: 679-681.
- Lusby, P.E., Coombes, A. and Wilkinson, J.M. (2002). Honey: A potent agent for wound healing? *J Wound Ostomy Continence Nurs* **29(6)**: 295-300.
- Ramdev (2009). <http://www.info@turmeric.co.in> (Accessed on 15.7.10)
- Rasik, A. M. and Raghubir, R. (1999). Healing potential of *Calotropis procera* on dermal wounds in Guinea Pigs. *J Ethnopharmacol* **68**: 261-266.
- Ravindranath, H. and Chandrasekaara, N (1980). Absorption and tissue distribution of the Curcumin in rats. *Toxicol* **16(3)**: 259-265.

Stashak, T. S. and Theoret, C. L. (1991). Selected factors that negatively impact healing. *Equine Wound Healing*. Lea Febiger (Ed) 2nd edition. Wiley-Blackwell, Ames, Iowa, USA. Pp71-77.

Watson T. (2003) Soft tissue wound healing. *Review* **104**:2-9.