

Diffusion Tensor Imaging in Determining Atypical Peripheral Nerve Neuroma in a Patient with a Painless Mass

Fathinul Fikri Ahmad Saad¹ , Razinul Syamim Fathinul Fikri¹ , Ahmad Danial Ahmad Shahrir² 



Cite this article as: Fikri Ahmad Saad F, Syamim Fathinul Fikri R, Danial Ahmad Shahrir A. Diffusion tensor imaging in determining atypical peripheral nerve neuroma in a patient with a painless mass. *Eurasian J Med.* 2024;56(2):146-147.

¹Centre for Diagnostic Nuclear Imaging, Universiti Putra Malaysia Faculty of Medicine and Health Science, Selangor, Malaysia

²Nuclear medicine Unit, Hospital Universiti Putra Malaysia Faculty of Medicine and Health Science, Selangor, Malaysia

Received: June 15, 2023

Revision requested: February 5, 2024

Last revision received: March 20, 2024

Accepted: April 4, 2024

Publication Date: May 9, 2024

Corresponding author: Fathinul Fikri Ahmad Saad
E-mail: ahmadsaadff@gmail.com

DOI 10.5152/eurasianjmed.2024.23149



Content of this journal is licensed under a Creative Commons Attribution 4.0 International License.

To the Editor,

Diffusion tensor imaging (DTI) promises further scrutiny in determining the functional and structural defects of the affected peripheral nerves (PNs) via differences in nerve stiffness and information of early regeneration. The report by Zhang et al¹ in their study on DTI of axonal and myelin changes in classical trigeminal neuralgia has substantiated that significantly increased fusion anisotropy (FA) is sufficiently sensitive to different pathologic states. In this regard, we emphasize that the reliability of the functional metric of the demyelination in peripheral neuropathy has more favorable credit than conventional diffusion-weighted imaging (DWI) in understanding patients with atypical presentations of the causative factors of peripheral neuropathy. We presented a case of a 71-year-old man who presented with a painless, protracted

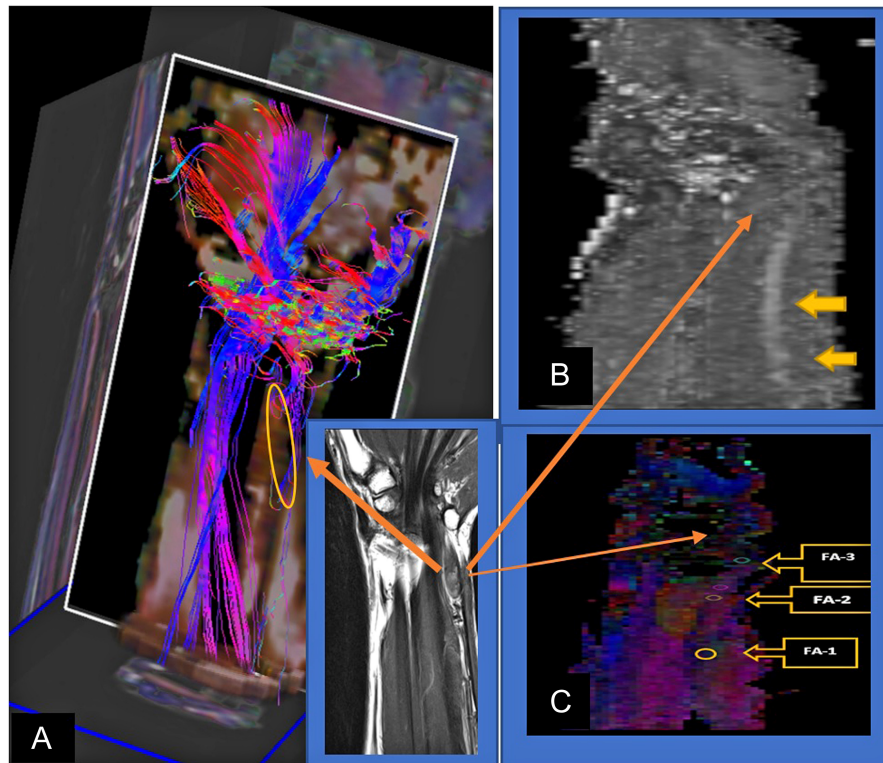


Figure 1. (A) (Inset) T1-weighted reference MR image of the ulnar nerve. Coronal color-coded map shows ulnar nerve (left arrow, eclipse marker). The direction of maximum diffusivity is mapped with triple colors—red, green, and blue color coding. (B) The ADC map confirms the tracked ulnar nerve fiber showing the high signal intensity of the normal caliber (right top arrow). (C) The FA map shows the tracked ulnar nerve fiber with decreasing values of the mean FA values toward the soft tissue lesion at the distal forearm—FA1 (0.96), FA2 (0.86), and FA3 (0.79).

subcutaneous tissue lump on the medial side of his left forearm, with associated numbness over the first and second web space. The lump was soft and non-tender, with a negative Tinel's sign on examination. Diffusion tensor imaging scanning protocols were performed on the 3.0 T scanner (Prisma, Siemens Healthineers, Erlangen, Germany), consisting of 13 volumes (45 slices, 128 × 128 voxel, slice thickness 2.2 mm, in-plane voxel size 1.5 mm × 1.5 mm), representing 12 gradient directions and 1 scan with gradient 0 (B0) centered at the left wrist. Echo time (TE) and repetition time (TR) were 93 ms and 8000 ms, respectively. B value was 800 s/mm², 5 scans were k-space averaged online by the Siemens SYNGO operating software. A T1-weighted magnetization-prepared rapid-acquisition gradient echo sequence consisting of 160-200 sagittal partitions depending on head size was used. Written informed consent was obtained from the patient who agreed to take part in the study.

The FA values denoting axonal injury showed reducing values, attributed to the biopsy-proven neuroma tissue (Figure 1).²⁻⁵ On magnetic resonance imaging, the lesion exhibited an intermediate signal on T1W images and water restriction on the DWI images. The DTI image exhibited a lack of regional nerve ramification and associated functional degeneration on the FA parameter (Table 1). Diffusion tensor imaging enhances the functional characterization of nerve regeneration and tissue microstructure and generates parameters on myelination composite, axonal diameter, fiber density, and organization.^{6,7} There is a limited report on the role of DTI in the atypical presentation of neuroma, for which its utility is deemed essential to ascertain accurate

Table 1. Reported FA Values of the Normal and Pathological of the Peripheral Nerve Axons			
	Nerve Tissue	FA Value (Normal)	FA Value (Abnormal/ Pathology)
1	Median nerve	0.58 ± 0.04	0.45 ± 0.05
2	Ulnar nerve	0.48 ± 0.09	0.08 ± 0.14
3	Trigeminal nerve	0.56 ± 0.05	0.43 ± 0.08
4	Tibial nerve	0.45 ± 0.04	0.36 ± 0.04

diagnosis and would serve as a potent marker in monitoring neuronal repairs post treatment. Its utility has limitations in standard data acquisition on different scanning models. Motion artifacts and soft tissue edema may affect the accurate delineation of its virtual anatomical mapping for surgical planning. In the future, DTI could constantly improve virtual surgical planning and influence precision in medical therapeutics with progress in artificial intelligence on the mathematical algorithms and savvy use of analytical parameters for researchers on personal computers for end users of varied disciplines.

Informed Consent: Written informed consent was obtained from the patient who agreed to take part in the study.

Peer-review: Externally peer-reviewed.

Author Contributions: Concept – F.F.A.S.; Design – F.F.A.S.; Supervision – F.F.A.S.; Resources – F.F.A.S.; Materials – R.S.F.F.; Data Collection and/or Processing – R.S.F.F.; Analysis and/or Interpretation – F.F.A.S., R.S.F.F.; Literature Search – A.D.A.S.; Writing – F.F.A.S.; Critical Review – R.S.F.F.

Acknowledgments: The authors would like to thank the Centre for Diagnostic Nuclear Centre,

Universiti Putra Malaysia for supporting in providing a database for the subjects recruited in this study.

Declaration of Interests: The authors have no conflict of interest to declare.

Funding: The authors declared that this study has received no financial support.

References

1. Zhang Y, Mao Z, Cui Z, et al. Diffusion tensor imaging of axonal and myelin changes in classical trigeminal neuralgia. *World Neurosurg.* 2018;112: e597-e607. [\[CrossRef\]](#)
2. Naik S, Mahanty S, Bhoi SK, Lahre Y, Bag ND, Mohakud S. MRI of wrist and diffusion tensor imaging of the median nerve in patients with carpal tunnel syndrome. *J Neurosci Rural Pract* 2023;14:302.
3. Mueller HP, Unrath A, Sperfeld AD, Ludolph AC, Riecker A, Kassubek J. Diffusion tensor imaging and tractwise fractional anisotropy statistics: quantitative analysis in white matter pathology. *Biomed Eng OnLine.* 2007;6:42. [\[CrossRef\]](#)
4. Elkholy SF, Gadalla AAEH, Mohammad ME, Mahmoud BE. Diffusion tensor imaging in trigeminal neuralgia: beyond the normal morphology. *Egypt J Radiol Nucl Med.* 2023;54(1):154. [\[CrossRef\]](#)
5. Wang X, Luo L, Xing J, et al. Assessment of peripheral neuropathy in type 2 diabetes by diffusion tensor imaging. *Quant Imaging Med Surg.* 2022;12(1):395-405. [\[CrossRef\]](#)
6. Heckel A, Weiler M, Xia A, et al. Peripheral nerve diffusion tensor imaging: assessment of axon and myelin sheath integrity. *PLoS One.* 2015;10(6):e0130833. [\[CrossRef\]](#)
7. Chhabra A, Thakkar RS, Andreisek G, et al. Anatomic MR imaging and functional diffusion tensor imaging of peripheral nerve tumors and tumor-like conditions. *AJNR Am J Neuroradiol.* 2013;34(4):802-807. [\[CrossRef\]](#)