

## CASE REPORT

# Langerhans Cell Histiocytosis Mimicking Otitis Media

Noor Liza Ishak<sup>1</sup>, Tan Sui Teng<sup>2</sup>, Nor Eyzawiah Hassan<sup>3</sup>, Azila Alias<sup>4</sup>

<sup>1</sup> Otorhinolaryngology Department, Faculty of Medicine and Health Sciences, Universiti Putra Malaysia, 43400 Serdang, Selangor.

<sup>2</sup> Otorhinolaryngology Department, Hospital Serdang, Jalan Puchong, 43000 Kajang, Selangor.

<sup>3</sup> Faculty of Medicine and Health Sciences, Universiti Sains Islam Malaysia (USIM), Persiaran Ilmu, Putra Nilai, 71800. Nilai, Negeri Sembilan

<sup>4</sup> Hospital Kuala Lumpur. Jalan Pahang. 50586 Kuala Lumpur. Wilayah Persekutuan Kuala Lumpur.

### ABSTRACT

Langerhans cell histiocytosis (LCH) is a spectrum of disease characterised by proliferation of Langerhans cells causing local or systemic manifestations. We report a two-year old boy who presented with a two-month history of progressive painless swelling over the right zygomatic region with ipsilateral otorrhea. Radiological investigation revealed an expansile hypodense lesion within the temporal bone with erosion of surrounding structures and meningeal enhancement. An ultrasound-guided biopsy of the lesion confirmed the diagnosis of LCH. LCH of the temporal bone may masquerade as otitis media with intra-temporal complications. A high index of suspicion is essential to avoid delay in diagnosis and management.

*Malaysian Journal of Medicine and Health Sciences* (2023) 19(SUPP19):25-27. doi:10.47836/mjmhs.19.s19.7

**Keywords:** Otitis media, otorrhea, Langerhans cell histiocytosis

### Corresponding Author:

Noor Liza Ishak, MS (ORL-HNS)

Email: noorliza@upm.edu.my

Tel: +603-97692360

### INTRODUCTION

Langerhans cell histiocytosis is an idiopathic rare disorder with an incidence of one in every two million children. It is characterised histologically by neoplastic proliferation of histiocytes and other inflammatory cells. The accumulation and pathological dissemination of these cells leading to destruction of the underlying hard and soft tissue. The aetiology of the disease is controversial up to date due to its relatively low incidence. Several factors such as infection, immunology, environmental, genetic, and neoplastic process that may contribute to the pathogenesis.

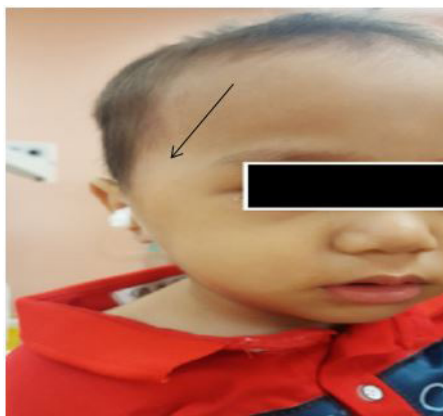The disease has been generally categorised into Eosinophilic Granuloma (EC), Hand-Schuller-Christian (HSC) disease and Letterer-Siwe (LS) disease with different prognostic values. Head and neck region involvement of this disease is relatively common. The manifestation may include cervical lymphadenopathy, skin rashes, neoplastic lesion over the skull and temporal bone. The symptoms of the above condition may point towards the more common diagnoses such as otitis media, otitis externa, acute mastoiditis, and lymphoma instead of making such an uncommon diagnosis during

the initial visit (Kleijnung 2003). Furthermore, the confirmation of the disease can only be done upon immunohistochemical staining of the tissue with CD1a and S10 hence establishing the diagnosis becomes more challenging. The purpose of this study is to present a case of temporal bone LCH that masquerade as the otitis media with intra-temporal complication.

### CASE REPORT

A two-year old boy was admitted with a two-month history of right ear purulent discharge with right zygomatic swelling that was gradually increasing in size (Figure 1). He was otherwise well without any systemic or neurological symptoms. He was seen by a general practitioner and was treated as right acute otitis media. The symptoms did not resolve despite multiple doses of oral and topical antibiotics.

The right zygomatic swelling measured about 3x4cm with regular borders with normal overlying skin. There was no tenderness and was fixed to the underlying zygomatic bone. There was no mastoid swelling or tenderness. Otoscope examination showed polypoidal tissue arising from the anterior wall of the right external auditory canal. The tympanic membrane couldn't be visualised. The laboratories' results were within normal range. Histopathological examination of the polypoidal tissue showed granulation tissue in origin.

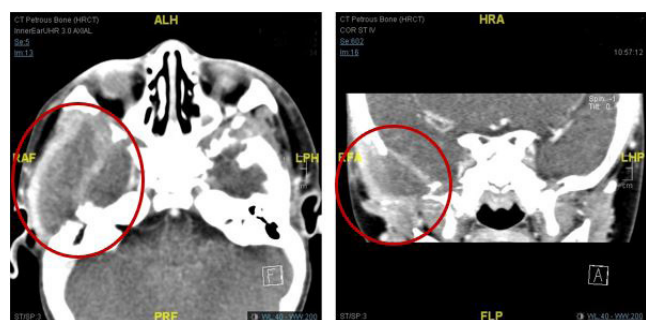


**Figure 1: Diffusely swollen neck especially at submandibular and submental region bilaterally**

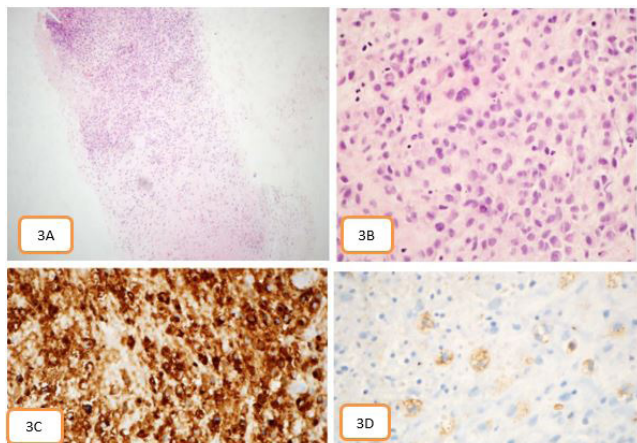
Our initial working diagnosis for this child was acute otitis media with intra-temporal complication. High Resolution Computed Tomography (HRCT) temporal bone with contrast showed a large rim enhancing hypoechoic lesion on the right side of the infratemporal fossa, measuring 4.8x 2.3x1.9cm with the epicentre of the lesion at the squamous part of the right temporal bone with surrounding meningeal enhancement.

Magnetic Resonance Imaging (MRI) of the brain showed partially liquefied abscess at the right masticator space with extension into right medial cranial fossa and involvement of the right middle ear cavity. There was right mastoiditis with sinus tract evidenced by small collections within the right mastoid air cell, which was associated with bony erosions, osteomyelitis and extradural extension into the right temporal bone.

The patient was given a third generation of cephalosporin antibiotic in view of the intracranial extradural extension of the lesion, and he was scheduled for ultrasound guided right zygomatic mass biopsy. Histopathological report showed fragmented lesion tissue with large area of necrosis exhibiting sheets of oval mononuclear cells characterised by irregular nuclei with pale cytoplasm. Further immunohistochemical stains of the tissue confirmed the diagnosis of Langerhans cell histiocytosis, as evidenced by positive CD1a and S100 (Figure 3).



**Figure 2: HRCT temporal bone(Contrasted, axial and coronal view) showed there was a large rim enhancing hypoechoic lesion on the right side of the infratemporal fossa, measuring 4.8x 2.3x1.9cm with the epicentre of the lesion at the squamous part of the right temporal bone with surrounding meningeal enhancement.**

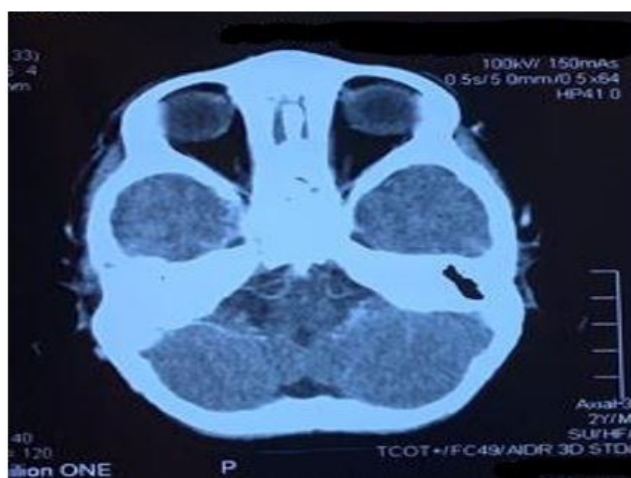


**Figure 3: (A) Sections showed fragmented lesional tissue with large area of necrosis. (Hematoxylin & Eosin, x10 ). (B)The lesional cells exhibit sheets of oval mononuclear cells characterized by irregular nuclei with pale cytoplasm. (Hematoxylin & Eosin, x 60 ). (C) The lesional cells are positive for CD1-alpha staining. (x 60). (D) Presence of bubbling signs within the cytoplasm of lesional cells with CD 68 staining confirmed the cells are histiocytes in origin. ( x 60 )**

The patient was diagnosed to have Langerhans cell histiocytosis of the temporal bone and was sent to the Paediatric Oncology Department for initiation of chemotherapy. He has completed chemotherapy with intravenous Vinblastine three weekly for the past one year. CT brain upon completion of chemotherapy showed significant reduction of the extrasosseous soft tissue. He responded well with the chemotherapy and is currently on surveillance visit with the oncology clinic (Figure 4).

## DISCUSSION

Langerhans cell histiocytosis is a rare disease in the paediatric and adult age group of patient, especially in the otolaryngology field. This poses a big diagnostic dilemma as symptoms of LCH in otology are nonspecific ranging from otorrhoea, temporal bone swelling, hearing



**Figure 4: Repeated CT Brain after completion of chemotherapy show significant reduction in extrasosseous soft tissue which indicates good response of the tumour with chemotherapy.**

loss and facial nerve palsy that mimics otitis media [1,2]. The clinical spectrum was divided into three categories namely Eosinophilic Granuloma (EG), Hand-Schuller-Christian disease (HSC) and Letterer-Siwe disease (LS). However, in recent years, the nomenclature has been abandoned and was replaced by the classification of a single system or multisystem involvement to guide the management and prognosis.

The course of the disease is unpredictable and may be varied. The case we have reported here is the single system disease which involved the unilateral temporal bone, which carries a better prognosis as compared to multisystem disease. [3,5]. Anonsen and Donaldson reported that 42% of the LCH involved the cranial bone, with 20-30% involvement of the temporal bone [3,4]. Simultaneous involvement of bilateral temporal bone involvement was extremely rare.

We are reporting this case because the symptoms of LCH can be varied depending on the disease extension. It may masquerade as other disease condition such as otitis media, cholesteatoma, and mastoiditis or Tuberculous Otitis Media hence making the disease diagnostically challenging.

This patient presented with right otorrhea with ipsilateral zygomatic swelling and polypoidal soft tissue in the ear canal for the past two months. This fulfils the clinical picture of otitis media with an intra-temporal complication such as sub-periosteal abscess. HRCT temporal bone showed large rim-enhancing lesion over the squamous part of the temporal bone mimicking an abscess.

Despite the overwhelming physical and radiological findings, he was clinically well and afebrile with normal range of septic parameters. This raised the suspicion on our initial working diagnosis of otitis media with sub-periosteal abscess. Surgical drainage was not performed despite poor progress with initial medical treatment. Subsequent ultrasound-guided biopsy with immunohistochemical staining further confirmed the diagnosis of LCH.

Symptoms of LCH are non-specific and can be masqueraded as otitis media. However, it is essential to establish the correct diagnosis of LCH to avoid delay in treatment. A high index of suspicion and further diagnostic tests is indicated when conservative management of otitis media has failed to give the expected improvement.

The only way to establish the diagnosis is via histopathological examination and immunohistochemical staining. The tissue showed lesional cell with oval mononuclear cell and positive for the CD1a and S100 immunohistochemical staining, which confirmed the diagnosis of LCH.

This patient has a good prognosis given that the disease involved only the single system and the early age of diagnosis. He was then sent to the Paediatric Oncology Department for further treatment. Treatment options of childhood LCH lesions in bones around the ears may include chemotherapy and steroid therapy or surgery.

## CONCLUSION

In conclusion, LCH is a rare disease. The symptoms are non-specific and often masquerade as other more common condition such as otitis media. Diagnosis of LCH can only be confirmed with tissue biopsy and positive immunohistochemical staining. Early diagnosis and single system involvement are the good prognostic factor. Therefore, a high index of suspicion for LCH is essential when the conventional treatment of otitis media has failed.

## REFERENCES

1. Bernstrand C, Sandstedt B, Ahstrum L, Henter JI. Long-term follow-up of Langerhans cell histiocytosis: 39 years' experience at a single centre. *Acta Paediatr.* 2005;94(8):1073-1084. doi:10.1111/j.1651-2227.2005.tb02048.x
2. Irving RM, Broadbent V, Jones NS. Langerhans' cell histiocytosis in childhood: management of head and neck manifestations. *Laryngoscope.* 1994;104(1 Pt 1):64-70. doi:10.1288/00005537-199401000-00011
3. Anonsen CK, Donaldson SS. Langerhans' cell histiocytosis of the head and neck. *Laryngoscope.* 1987;97(5):537-542. doi:10.1288/00005537-198705000-00002.
4. Kleinjung T, Woenckhaus M, Bachthaler M, Wolff JE, Wolf SR. Langerhans' cell histiocytosis with bilateral temporal bone involvement. *Am J Otolaryngol.* 2003;24(4):265-270. doi:10.1016/s0196-0709(03)00049-8
5. Kumar YP, Agrawal J, Mohanlakshmi J, Kumar PS. Langerhans cell histiocytosis revisited: Case report with review. *Contemp Clin Dent.* 2015;6(3):432-436. doi:10.4103/0976-237X.161912