

See discussions, stats, and author profiles for this publication at: <https://www.researchgate.net/publication/379643378>

CASE REPORT: EYE EXENTERATION AND FACIAL SKIN DEFECT RECONSTRUCTION IN A CAT WITH SQUAMOUS CELL CARCINOMA

Article · February 2024

CITATIONS

0

READS

110

5 authors, including:



Norfitriah Mohamed Sohaimi
Universiti Putra Malaysia

38 PUBLICATIONS 164 CITATIONS

SEE PROFILE

CASE REPORT

EYE EXENTERATION AND FACIAL SKIN DEFECT RECONSTRUCTION IN A CAT WITH SQUAMOUS CELL CARCINOMA

NORFITRIAH, M.S.^{1*}, LOQMAN, M.Y.², GAYATHRI, T.S.², HAZILAWATI, H.², JASNI, S.² AND ERNI WATI, M.A.³

1 Department of Veterinary Laboratory Diagnosis, Faculty of Veterinary Medicine, Universiti Putra Malaysia, 43400 UPM, Serdang, Malaysia

2 Department of Veterinary Clinical Studies, Faculty of Veterinary Medicine, Universiti Putra Malaysia, 43400 UPM, Serdang, Malaysia

3 Department of Veterinary Microbiology and Pathology, Faculty of Veterinary Medicine, Universiti Putra Malaysia, 43400 UPM, Serdang, Malaysia

*Corresponding author: fitriahsohaimi@upm.edu.my

ABSTRACT. Eye exenteration is one of the surgical approaches for complete excision of malignant neoplasm around the ocular region and to prevent metastasizes of cancerous cells. This paper highlights the importance of surgical management of squamous cell carcinoma and skin flap technique to promote wound healing. In this case, a 10-year-old Domestic Shorthair cat with a non-healing ulcerated wound on right lower eyelid was presented to the University Veterinary Hospital (UVH), Universiti Putra Malaysia (UPM) and was diagnosed as squamous cell carcinoma (SCC) based on cytology and histopathology findings. A cluster of various abnormal squamous cells with typical characteristics of well-differentiated squamous cell carcinoma was observed under cytology examination. In addition, the ulcerated wound rapidly increased in size and it was decided to conduct complete surgical removal of tumour in the entire part of the eye region. Eye exenteration followed by transpositional skin flap were applied to cover the defect area. The biopsy sample was collected and confirmed as grade 1 SCC with minimal hyperchromatism. Suction drainage was provided in the orbital spaces with application of head bandage at post-operative management to create pressure and reduce dead space. However, there are three episodes of skin flap breakdown due to the presence of large dead space and seroma within the orbital space. Finally, the wound was managed as secondary intention healing until the cat was discharged.

Keywords: eye exenteration, squamous cell carcinoma (SCC), transpositional skin flap, cytology, seroma

INTRODUCTION

Squamous cell carcinoma (SCC) is a malignant tumour derived from the epithelium of the squamous cell and most frequently reported in cats with hairless and non-pigmented skin typically in the eyelid region (Marconato *et al.*, 2021). In addition, SCC is locally invasive and occasionally metastatic (Blood *et al.*, 2007). The tumour commonly affects older cats with mean age of 12 years old and manifests either a proliferative or an erosive lesion (Julie *et al.*, 2009; Sequeira *et al.*, 2022). Treatment options

depend on the stage of the primary tumour either by chemotherapy, surgical excision, radiation therapy, and immunotherapy (Bilgic *et al.*, 2015). While, eye exenteration is surgical procedure for removal of the globe, nictitating membrane, lid margins, and orbital contents for complete excision of neoplasia and contact region (Telle *et al.*, 2022). Facial skin defect reconstruction will be applied in any cases following removal of tissue in order to cover the orbital cavity through transpositional skin flap obtained from additional surrounding skin with a rectangular form and rotated into the

defect area (Fossum, 1997; Degner, 2007). The surgical excision is a primary curative option to prevent metastasis of tumour. Nevertheless, the success of therapy depends much on the proper plan for skin reconstruction of the defective tissue as a result from tissue removal (Orencole, 2013; Guzu *et al.*, 2021). We report a case of surgical excision in a cat with SCC by application of eye exenteration and facial skin defect reconstruction as a technique to prevent local recurrence of this invasive tumour.

CASE REPORT

Case History and Clinical Presentation

A 10-year-old, spayed female, Domestic Shorthair cat weighing 4.4 kg was presented to the University Veterinary Hospital of Universiti Putra Malaysia (UVH-UPM) for a first visit with a complaint of ulcerated wound at right lower eyelid. The wound was noticed by the owner in the last 2 months prior to the visit and was treated in another clinic but showed lack of improvement. Physical examination findings revealed a non-

healing wound at the lower lateral and medial canthus of the right eye and lower eyelid. All vital signs were within normal range.

Diagnostic Investigations

Haematological, serum biochemistry parameters, as well as thoracic radiography were unremarkable in this case. Giemsa staining performed on the impression smear taken from the right lower eyelid revealed a cluster of well-differentiated squamous cells with marked anisocytosis, anisokaryosis, poikilocytosis, prominent nucleolus and macronucleus, coarse nuclear chromatin pattern, and basophilic cytoplasm as shown in Figure 1(a). The confirmative diagnosis based on cytology was well-differentiated squamous cell carcinoma. The wound rapidly progressed in size from 0.5 cm in diameter during Day 1 hospitalisation and increased to 2 cm in diameter at Day 6 hospitalisation with severe ulceration, appearing as a cauliflower-like lesion [Figure 1(b)]. Surgical excision of eye region was decided for complete removal of the tumour.

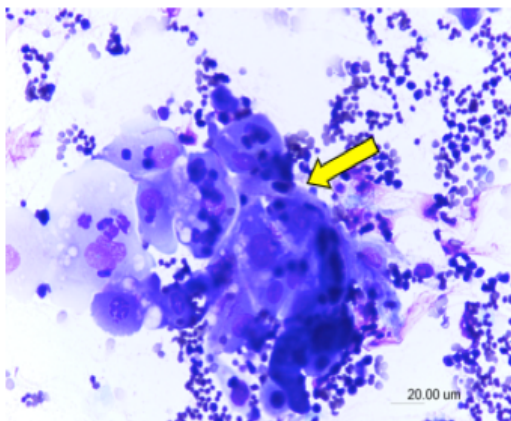


Figure 1(a). A cluster of well-differentiated squamous cells with marked anisocytosis, anisokaryosis and poikilocytosis with basophilic cytoplasm (arrow), scale bar = 20.0 µm (May-Grunwald Giemsa stain, 200x)

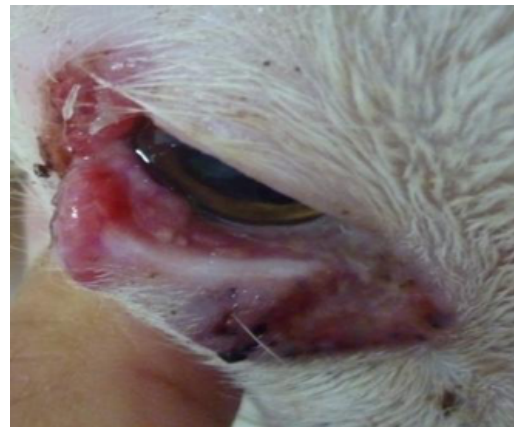

Figure 1(b). Cauliflower-like lesion in ulcerated wound with 2 cm in diameter at right lower eyelid

Surgical Procedure

Right eye exenteration

General anaesthesia was induced in a cat with 2.5 % sodium thiopental (Pentothal) and maintained with 1.5 % Isoflurane (Forane). The cat was placed on left lateral recumbency prior routine surgical skin preparation aseptically. Initially, the eyelid margins were opposed using 3-0 nylon (Ethilon) with a simple interrupted pattern. Skin incision about 1 cm around the wound was made with scalpel blade #20 and incised together with conjunctiva and intraocular muscle [Figure 2(a)].

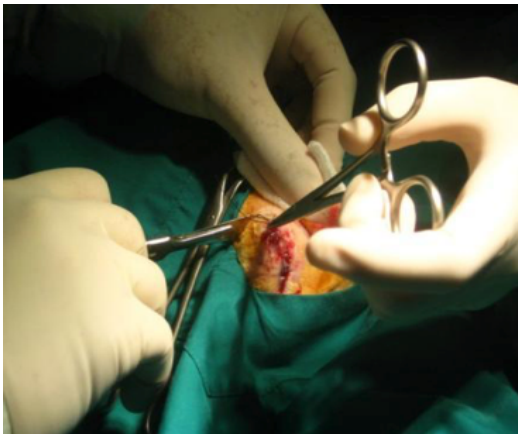


Figure 2(a). Skin incision about 1 cm around the wound was made with scalpel blade #20 and deeply incised the conjunctiva and intraocular muscle

The incision was continued about 1 cm to dorsal and ventral of the eyelid margins and 5 mm to the medial and lateral eye canthus. The blood vessels and optic nerve were clamped with hemostat and ligated with absorbable suture material 3-0 polyglyconate (Maxon) prior excision [Figure 2(b)]. For complete removal of the eye globe, sharp dissection using Metzenbaum scissors was performed for excision of eyelid margins, nictating membranes, and the surrounding intraocular muscles. All tissue debris was removed and flushed with 0.9 % sodium chloride solution into the ocular space.

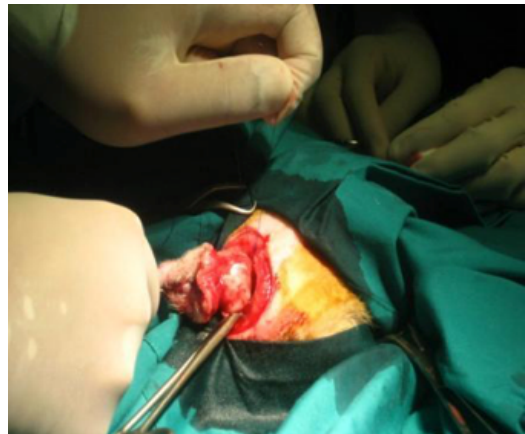

Figure 2(b). The blood vessels and optic nerve were clamped with hemostat and ligated with absorbable suture material 3-0 polyglyconate (Maxon) prior excision

Transpositional skin flap

Area of the lateral to the right eye skin was marked with a sterile marker for transpositional skin flap to cover the orbital spaces. The width of the flap equalled to the width of the defect [(Figure 3(a)]. By using Mayo scissors, the outlined skin was

incised and transposed onto the ocular defect. A seton with 16 cm length was placed in the ocular space to provide a post-surgical wound drainage [Figure 3(b)]. Finally, the transposed skin flap was sutured in place using 3-0 Ethilon with a simple interrupted pattern [Figure 3(c) and (d)].

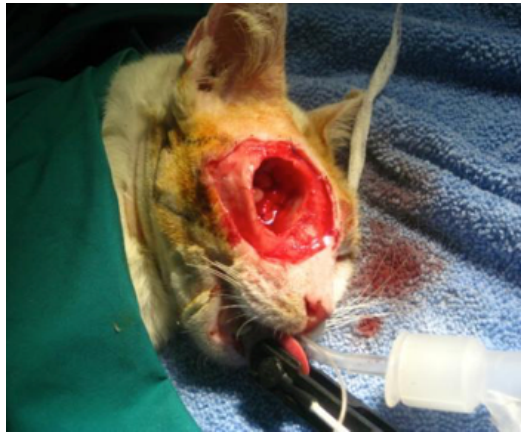

Figure 3(a). Skin lateral to the right eye was marked with equal length to defect area for skin flap

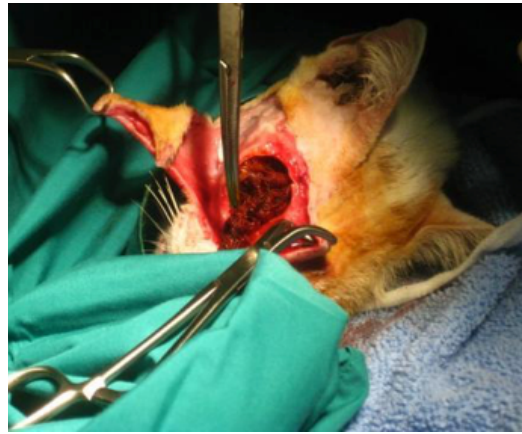

Figure 3(b). 16 cm seton was placed in ocular space for wound drainage

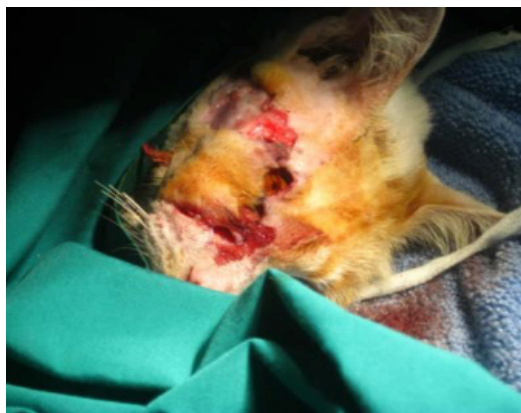

Figure 3(c). Skin flap was transposed and sutured with 3-0 Ethilon simple interrupted pattern

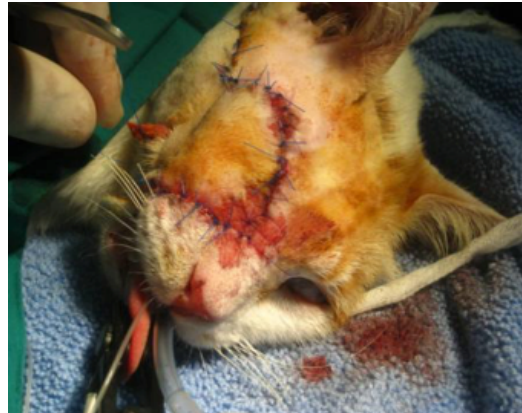

Figure 3(d). The recipient was sutured and the donor area was sutured completely and closed the defect region

Post-Operative Management

Tramadol (3 mg/kg) as analgesic, and Lactated Ringer's solution were administered at a maintenance dose (60 ml/kg) intravenously for 5 days. For dead space management, a head bandage was applied for 3 days as pressure exertion and to reduce the risk of edema and haemorrhage. Suture site and skin flap colour

were monitored daily with gradual removal of 1 cm seton per day after 3 days post-surgery.

Post-Operative Progression

Following the surgery, the cat was stable and given anti-inflammatory medication. However, post-operative complication was recorded which involved three episodes of suture breakdown at

Day 10, 21 and 24 post-surgery. In the first two episodes, wound debridement followed by re-suture the flap area was performed. In the last episode, the wound was treated as an open wound with daily flushing with sterile NaCl, povidone iodine solution, and debridement. The cat was discharged from the hospital at Day 35 post-surgery and the wound was treated as secondary intention wound healing. The prognosis for this case was poor since the cat became aggressive and unmanageable by the owner.

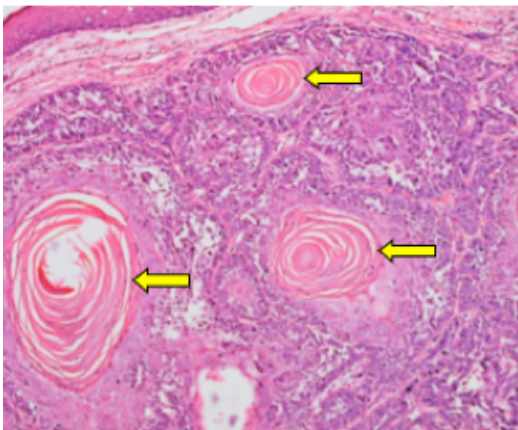


Figure 4(a). Numerous keratin pearls (arrow) from tumor on eyelid (H&E, x20)

Histopathological Findings

The tumour on eyelid was fixed in 10 % formalin, processed and stained with haematoxylin and eosin for histopathology evaluation. Histopathology diagnosis revealed the biopsy sample was grade 1 SCC based on Broder's system with evidence of numerous keratin pearls at variable sizes [Figure 4(a)] and minimal hyperchromatism [Figure 4(b)].

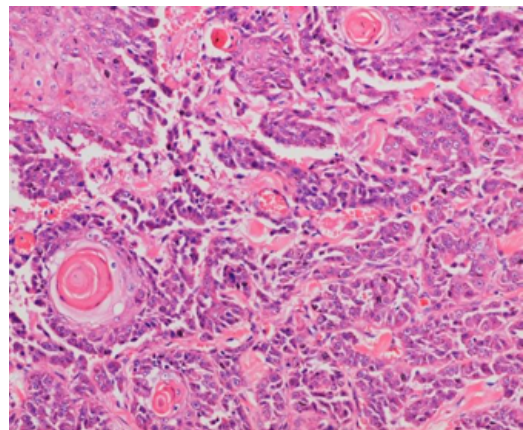


Figure 4(b). Minimal hyperchromatism and low indicative of malignancy at grade 1 (H&E, x40)

DISCUSSION

Surgical excision of tumour is one of the most frequent approaches among the other treatments in veterinary medicine such as chemotherapy or anticancer drug for complete removal of neoplasm and reduced risk of tumour recurrence. Although SCC occasionally metastasized, no metastasis had occurred in this case. However, the tumour rapidly progressed and increased in size during hospitalization which prompted immediate surgical intervention. Thus, wide resection of the tumour with clean margins by

eye exenteration procedure and covered with local pedicle flap was carried out, adopting the method by Dias *et al.* (2017).

The main issues in the surgical management for this type of case are pre-operative skin flap consideration and post-operative complications. The selection of skin flap technique depends on several factors such as the aetiology and nature of the wound, the availability of skin around the wound as well as the location of vascular pedicle or vascular limits for the skin flap (Degner, 2007). The aetiology and nature

of the wound influence the appropriate time of closure. While a malignant tumour is removed surgically in an aseptic way, the wound typically remains clean and uncontaminated (Bloch *et al.*, 2020). In this case, the flap of skin could be used to cover the defect in the wound. The minimal vascular supply, also referred to as the direct cutaneous artery, restricts the flap's size and length prior to it being harvested and transferred to an adjacent wound. As a result, in order to maintain the viability for the skin flap, it is crucial to seriously consider a specific vascular pedicle which is readily present in the transverse facial artery and superficial temporal artery, as this case demonstrates (Lee *et al.*, 2022).

Extensive tissue dissection such as eye exenteration creates large dead space in orbital space as shown in the present case. Seroma formation is a common post-operative complication due to presence of large dead space in the body cavity and leads to continuous discharge from defect area (Hennet *et al.*, 2022). Although suction drains and bandages were applied to eliminate dead space and seroma formation, flap dehiscence was observed due to early removal of the seton before reduction of dead space (Remedios, 1999). Thus, periods of seton removal also play an important role in the success of skin flap healing. It is suggested that the time might be extended from day 3 to 5 post-surgery in order to reduce dead space prior to seton removal. Subsequently, the wound was managed as secondary intention healing with daily debridement to prevent infection. Application of biodegradable drainage from polyethylene glycol or polycarbonate is beneficial for future use since it is a natural drainage and is absorbed directly into the body without manual retraction. Both materials are well tolerated to soft tissue and prevent seroma formation (Zawaneh *et al.*, 2010).

CONCLUSION

Surgical removal of tumour by the combination of eye exenteration and transpositional skin flap was completely beneficial for early-stage removal of SCC and minimised the possibility of metastasis to another region. In this case, a superficial temporal artery was included in the skin flap to cover the orbital wound defect. However, flap dehiscence occurred as a result of seroma formation in the large dead space within the orbit and managed as secondary wound healing.

Future Recommendations

To improve the effectiveness of skin flap in the future, the usage of biodegradable drainage from polyethylene glycol or polycarbonate is recommended due to rapid absorption into the body.

Client Education

Diagnosis of squamous cell carcinoma required several tests for staging and grading of the cancer. Early detection of SCC in non-healing wounds is important for proper therapy plans such as surgical excision for prevention of metastasis of cancer cells. In addition, wound management necessitates daily monitoring and aseptic cleaning to promote quick wound healing.

REFERENCES

1. Bilgic O., Duda, L., Sánchez M.D. and Lewis J.R. (2015). Feline oral squamous cell carcinoma: Clinical manifestations and literature review. *Journal of Veterinary Dentistry*. 32(1): 30-40.
2. Bloch J., Rogers K., Walker M., Dawson J. and Wilson-Robles H. (2020). Treatment of feline injection-site sarcoma with surgery and iridium-192 brachytherapy: retrospective evaluation of 22 cats. *Journal of Feline Medicine and Surgery*. 22(4): 313-321.

3. Blood D.C., Studdert V.P. and Gay C.C. (2007). Saunders Comprehensive Veterinary Dictionary. 3rd ed. Saunders Elsevier, USA, p1689.
4. Degner D.A. (2007). Facial reconstructive surgery. *Clinical Techniques in Small Animal Practice*. 22: 82–88.
5. Dias F.C., Danielski A. Forster K. and Williams D.L. (2017). Use of a subdermal plexus flap to reconstruct an upper eyelid following radical tumour resection in a cat. *Journal of American Veterinary Medical Association*. 250(2): 211-214.
6. Fossum T.W. (2002). Small Animal Surgery 2nd Ed. Mosby, Inc. p225-6.
7. Guzu, M., Rossetti, D. and Hennet, P.R. (2021). Locoregional Flap Reconstruction Following Oromaxillofacial Oncologic Surgery in Dogs and Cats: A Review and Decisional Algorithm. *Frontiers in Veterinary Science*. 8: 685036.
8. Hennet J., Pilot, M.A., Anderson D.M., Rossanese M., Chrysopoulos A., Puerta B.D.L., Mullins R.A and Chanoit G. (2022). Closure-related complications after median sternotomy in cats: 26 cases (2010–2020). *Journal of Feline Medicine and Surgery*. 24(6): e109-e115.
9. Julie L.W., Rachel E.B., Holly M.B. Bruce E.L. and Carrie E.K. (2009). Squamous cell carcinoma. Compendium: Continuing Education for Veterinarians Article. p133-40.
10. Lee J-H, You H-J, Lee T-Y and Kang HJ. (2022). Current Status of Experimental Animal Skin Flap Models: Ischemic Preconditioning and Molecular Factors. *International Journal of Molecular Sciences*. 23(9): 5234.
11. Marconato L., Murgia D., Finotello R., Meier V., Morello E.M., Pisoni L., Foglia A., Guerra D., Chalfon C., Aralla M., Mesto P., Annoni M., Albanese F., Bettini G. and Sabattini S. (2021). Clinical features and outcome of 79 dogs with digital squamous cell carcinoma undergoing treatment: A SIONCOV observational study. *Frontiers in Veterinary Science*. 8: 645982.
12. Orencole, M.J. (2013). Fundamental of surgical oncology in small animals. Today's veterinary practice, 14-18.
13. Pope E.R. (2006). Head and facial wounds in dogs and cats. *The Veterinary clinics of North America. Small animal practice*. 36(4): 793–817.
14. Remedios A. (1999). Complications of wound healing. In: BSAVA Manual of Canine and Feline Wound Management and Reconstruction. Fowler, D. and Williams, J.M. (Ed.) 1st. ed., Wiley, p71-73
15. Sequeira I., Pires M.D.A., Leitão J., Henriques J., Viegas C and Requicha J. (2022). Feline Oral Squamous Cell Carcinoma: A Critical Review of Etiologic Factors. *Veterinary Sciences*. 9(10): 558.
16. Telle M.R. and Betbeze C. (2022). Corneal Surgery in the Cat: Diseases, considerations and techniques. *Journal of Feline Medicine and Surgery*. 24(5): 429-441.
17. Withrow S.J. and Vail D.M. (2007). Small Animal Clinical Oncology. 4th Ed. Saunders Elsevier, St. Louis, p37.
18. Zawaneh P.N., Singh S.P., Padera R.F., Henderson P.W., Spector J.A. and Putnam D. (2010). Design of injectable synthetic and biodegradable surgical biomaterial. *Proceedings of the National Academy Sciences USA*. 107(24): 11014-11019.