

Titanium Elastic Nailing System of Diaphyseal Femur Fracture in a 7 Years Old Child: A Case Report

Shangeetha Tarmalinggam^{1,2*}, Edzell Swamy Appasamy¹, Kamarul Al Haqq Abdul Ghani¹, Norazian Binti Kamisan²

¹ Hospital Tengku Ampuan Rahimah, Klang, Department of Orthopaedics Surgery, Selangor, Malaysia

² University Putra Malaysia, Faculty of Medicine and Health Science, Department of Orthopaedics Surgery, Selangor, Malaysia

* Corresponding Author: Shangeetha Tarmalinggam E-mail: shangparanjothi@gmail.com

ABSTRACT

Objective: Midshaft femur fracture commonly treated conservatively in paediatric patients. However, complications are seen in conservative treatments and lately surgical interventions are being practised tremendously to minimise the complications.

Case Report: A 7 years old boy, sustained a closed fracture midshaft left femur after a motor vehicle accident. Operative management was decided for this patient using Titanium Elastic Nailing System, which revealed a good outcome within 3 months of duration.

Conclusion: Titanium Elastic Nailing System is fixed with minimally invasive techniques in children 6-16 years of age with diaphyseal femoral fractures, which gives a good outcome and minimizes the complications and allows earlier rehabilitation and return to school life by speeding up the fracture healing. However, an experienced surgeon and good surgical technique is desired to minimize the complications that may occur.

Keyword: Paediatric diaphyseal femur fracture, Operative management, Titanium Elastic Nailing

INTRODUCTION

Femoral diaphyseal fractures are the most common types of fractures seen in paediatric injuries (1). Conventionally, the fracture is treated by closed reduction with Bryant's traction, hip spica, and plating for surgical stabilisation (1). Due to spontaneous correction of angulation and the astounding rapid healing power due to age, non-surgical management has been the most favoured method of treatment in paediatric age groups traditionally (1). However, conservative treatments have resulted in complications such as loss of reduction and malunion (1). Moreover, newer understandings have been brought to light as present-day studies have shown that prolonged immobilisation on children by closed reduction such as Bryant's traction and Hip Spica can cause economic and psychosocial disturbances, not only to the children themselves but also to the entire family (2).

In the last two decades, there has been a rise in operative approach to managing femoral diaphyseal fractures in age between 6-16 as good outcomes have been proven in orthopaedic practise (1). Hereby, we are reporting a case of femoral diaphyseal fracture in a 7 years old child who was treated surgically using Titanium Elastic Nailing System (TENS).

CASE

A 7 years old Malay boy was brought to the emergency department, Hospital Tengku Ampuan Rahimah, Klang, by ambulance following a motor vehicle accident. On further history obtained from his parents, the child was seated in the back passenger's seat without fastening his seatbelt while travelling on the highway. Subsequently, the car was hit by a truck from the back and pushed into the drain. Post-trauma, the patient was complaining of intense pain over his left thigh and he was unable to weight bear with his left lower limb. There was no loss of consciousness, or retrograde amnesia. Vital signs were stable upon arrival to the hospital. On examination, noted deformity over the left lower limb. The left lower limb was externally rotated and shortened. There was significant tenderness over the left mid-thigh region. Otherwise, no other injuries or wounds were noted.

Case Report Article

Received 08-07-2022

Accepted 19-07-2022

Available Online: 20-07-2022

Published 30-07-2022

Distributed under
Creative Commons CC-BY-NC 4.0

OPEN ACCESS



MSD-2148-6832-2022-07-01-0001

A plain radiograph was done (**Figure 1**). X-Ray images show a simple transverse fracture midshaft of the left femur. The patient was diagnosed with a closed fracture midshaft left femur, Winquist, and Hansen Classification Type 0.

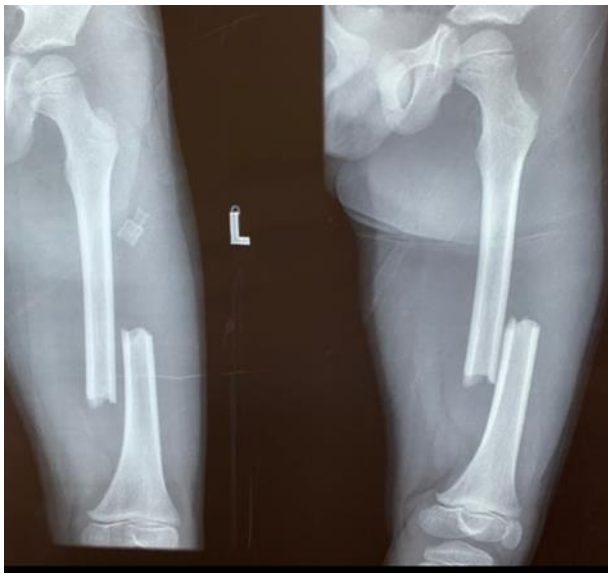


Figure 1: Pre-operative X-Ray images of left femur (Anteroposterior and Lateral View)

The patient was planned for the left femur Titanium Elastic Nailing System. Procedure was done under general anaesthesia. The patient was positioned supine on a radiolucent table. A rolled towel was placed under the distal thigh region with the leg hanging at the edge of the bed. Prophylactic antibiotic was served 30 mins before skin incision. A small skin incision was made over the medial and lateral aspects of the distal thigh. The entry point was made 2.5-3cm proximal to the distal femoral physis medially and laterally using an awl (**Figure 2**).

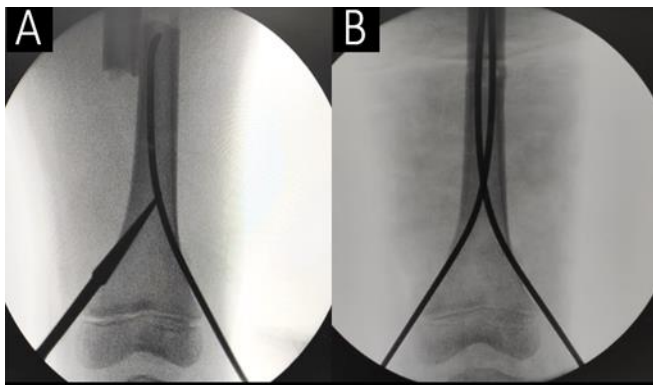


Figure 2: Intraoperative X-Ray images of left femur (Anteroposterior View). A: Pre-reduction image, B: Post reduction image

Two identical nail size 3.0 mm was used, and the nail was prebend 3 times the diameter of the bone at the fracture site. Retrograde nail insertion was done laterally and then medially. Fracture reduced using Kapandji method and subsequently both nails were pushed across the fracture site up to the metaphysis, one towards the lesser trochanter and another nail towards greater trochanter divergently (**Figure3**).

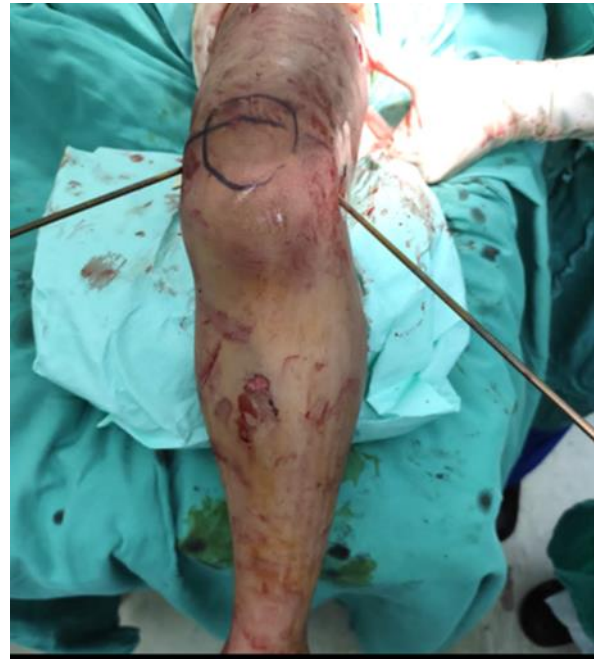

Figure 3: Intra-Operative images of right femur Titanium elastic nail entry point

Postoperatively, distal pulses were palpable, and there was no limb length discrepancy or rotation. Three doses of prophylactic intravenous antibiotics were completed in the ward. Post-operative check x-ray (**Figure 4**) was done, and alignment was acceptable.

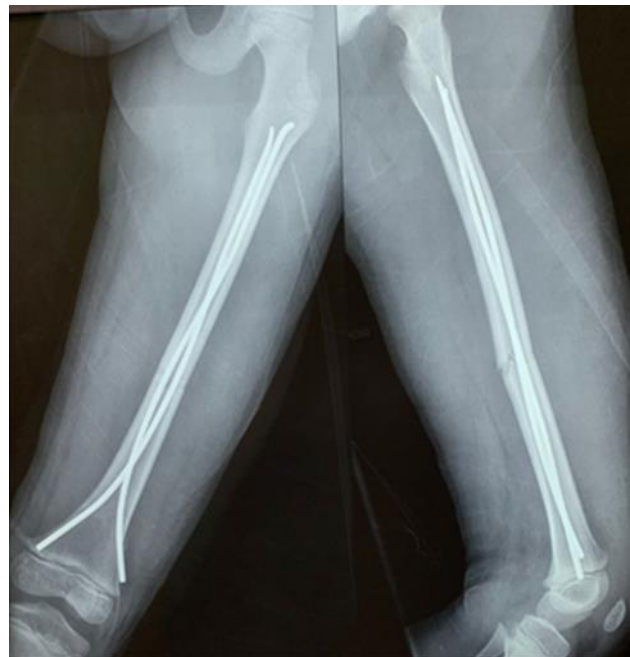

Figure 4: Immediate Post-Operative X-Ray Images of Left Femur (Anteroposterior and Lateral View)

No external immobilization was used, and the patient was started on gradual mobilization. On post-operative Day 2, the patient was well and discharged back home. On 3months follow-up in orthopaedic clinic x-ray (**Figure 5**) showed abundant callus formation. The patient was ambulating without aid (**Figure 6**).

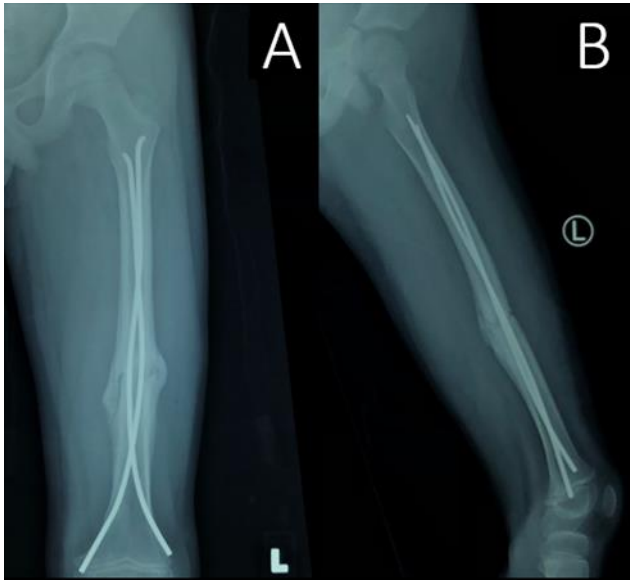


Figure 5: X-Ray left femur post-op 3 months. (A) Antero-posterior view, (B) Lateral view



Figure 6: Full Weight Bearing at Post-Operative 3 Months

DISCUSSION

It's been a constant challenge to the orthopaedic fraternity in choosing the ideal choice of implant or treatment in paediatric diaphyseal femoral fractures (1). Conservative treatment especially in older children noted to have complications such as malunion, joint stiffness and delay in functional recovery (1). Surgeons are looking into more efficient ways of treatment such as simple intramedullary nailing which maintains alignment of fracture and allows early mobilisation (2). TENS is an instrument that is uncomplicated, flexible and obtainable in all sizes (1,2).

It is a stable intramedullary nail or device which provides three-point fixation through the principle of symmetry bracing action of two nails with the same modulus of elasticity (1). This fixation provides rotational, axial, transitional and bending stability by offsetting the distraction and compression forces at the fracture site (1). It can be inserted in retrograde manner without harming the growth plate and this reduces the chance of avascular necrosis of the femoral head (1, 2).

Although there are complications such as limb length discrepancy, site irritation and mal-alignment in an insignificant number of cases, many studies are done which have proven to have remarkable results (1, 2). Transverse, short oblique and minimally comminuted diaphyseal femoral fractures are best to be fixed with TENS as it shows excellent result of outcome in older children (1). Studies revealed usage of TENS in obese children result in varus angulation after a proper pre bend of the nail, this can be avoided by additional plaster stabilization, traction or use of femoral brace (1).

Although, there are some chances for complications to occur, it is most likely due to technical errors made by surgeons such as choosing inappropriate nail diameter size which increases the incidence of varus or valgus angulation and mal-rotation (1, 3). Appropriate selection of nail insertion site and advancement of nail reduces the risk of skin ulceration due to nail protrusion and nail migration as well (1). This indicates that the experience of a surgeon and good surgical technique is the most crucial element in usage of TENS (3).

CONCLUSION

In conclusion, the Titanium Elastic Nailing System is fixed with minimally invasive techniques in children 6-16 years of age in diaphyseal femoral fractures (1). It reduces the risk of shortening and malunion moreover allows earlier rehabilitation and return to school life by speeding up the fracture healing. However, an experienced surgeon and good surgical technique is desired to minimize the complications that may occur.

Author Contributions: ST, ESA, KAHAG: Concept, Data collection and/or processing, Patient examination, and Surgery, Literature review, ST: Writing, Revision.

Acknowledgments: None

Conflict of interest: The authors declare no competing interests.

Ethical approval: All procedures performed in studies involving human participants were in accordance with the institutional and/or national research committee's ethical standards and with the 1964 Helsinki Declaration and its later amendments or comparable ethical standards.

REFERENCES

1. Govindasamy R, Gnanasundaram R, Kasirajan S, Ibrahim S, Melepuram JJ. Elastic stable intramedullary nailing of femoral shaft fracture-experience in 48 children. *Archives of Bone and Joint Surgery*. 2018 Jan;6(1):39.
2. Mallik M, Gupta TS, Maharaj RC, Chand DK, Sahoo PK, Nanda DP. Experience with Titanium Elastic Nails (TENS) for Femur Fracture and its Complications among 5-15 Years Age Group in Odisha: A Prospective Study.
3. Donati F, Mazzitelli G, Lillo M, Menghi A, Conti C, Valassina A, Marzetti E, Maccauro G. Titanium elastic nailing in diaphyseal femoral fractures of children below six years of age. *World Journal of Orthopedics*. 2017 Feb 18;8(2):156.